

Prepared by Drs. David SC Hui¹, Gavin M Joynt², KT Wong³, Gregory E Antonio³, Anil T Ahuja³ and Mr. Terence Lam³.

1 Department of Medicine and Therapeutics

2 Department of Anaesthesia

3 Department of Imaging and Interventional Radiology,
The Chinese University of Hong Kong.



Introduction

Dear Visitors,

Thank you for visiting our webpage on "avian flu". Through this webpage, we hope to share the clinical and radiographic features of this novo disease with the rest of the medical community.

Our first encounter with this new viral disease was in 1997 when there was a limited outbreak of the infection in Hong Kong. No major human outbreaks have since occurred until last winter. This time, however, the disease is more widespread and not limited to Asia or a single strain of the virus. With the help of our colleagues in Hong Kong and Vietnam, we have gathered a collection of serial radiographs of this disease and the associated clinical findings.

We would like to thank all the medical staff who have contributed and helped with providing information for this webpage. We would also like to acknowledge the efforts of the public, health-care workers and health authorities in limiting the spread of this disease.

Department of Imaging and Interventional Radiology,

The Chinese University of Hong Kong.

16th April, 2004.

13-year-old symptomatic female

Admitted to Paediatric ward 26/11/97 (Day 1) from the Emergency department.

Previously healthy. Sore throat, rhinorrhoea, and dry cough one week prior to admission. Fever four days prior to admission.

Examination - Alert, febrile, no respiratory distress. Lung auscultation - decreased breath sounds and crepitations in R lung base.

Complete blood count - WCC 4700/microL, Platelets 62 000/microL

Blood culture - negative

Sputum culture - nil of note

Viral titre - nil of note

Diagnosis of atypical pneumonia - Clarythromycin orally.

Following day - haemoptysis. Cefotaxime added.

In evening cough, increasing respiratory rate and distress and hypoxia despite oxygen therapy.

Admitted to ICU on 27/11/97 (Day 2).

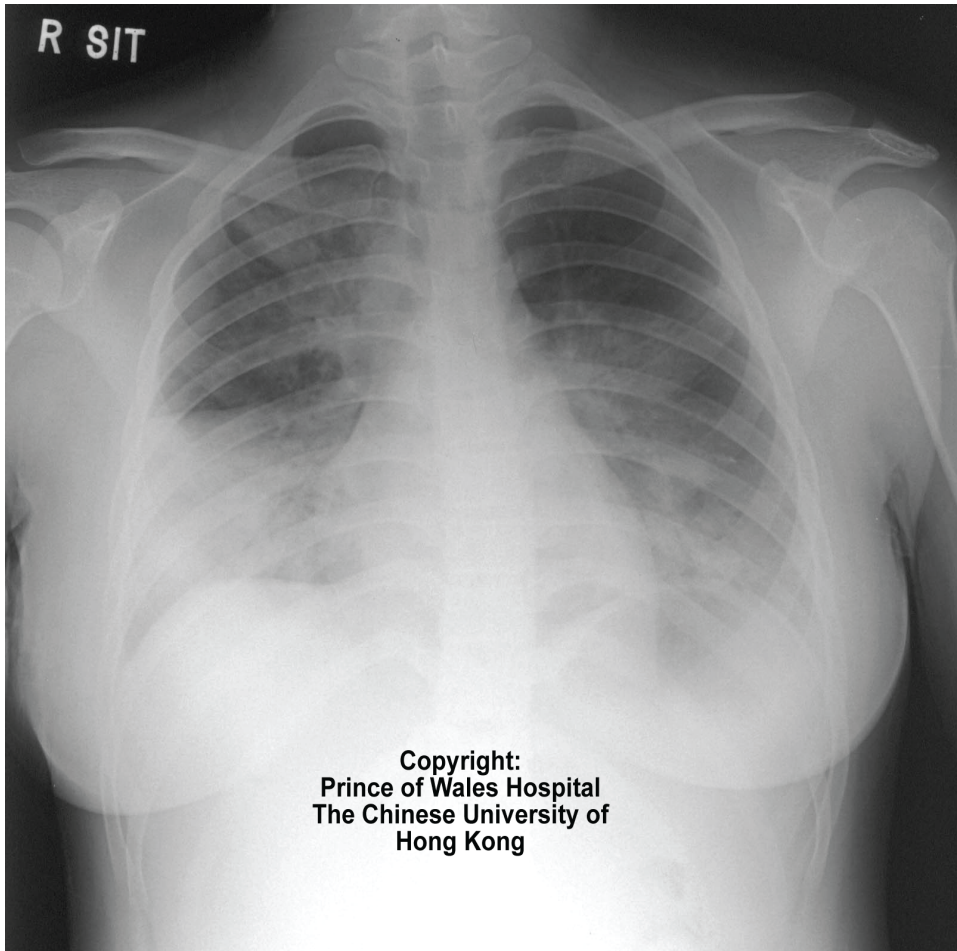
Mechanical ventilation for hypoxia 6 h after admission. Clinical R lower and middle lobe crepitations and audible "rub". Rapid deterioration over next 3 days with ARDS, multiple organ dysfunction.

29/11/03: Upper gastrointestinal bleeding. Worsening ARDS requiring prone position ventilation - until the 5th or 6th Dec.

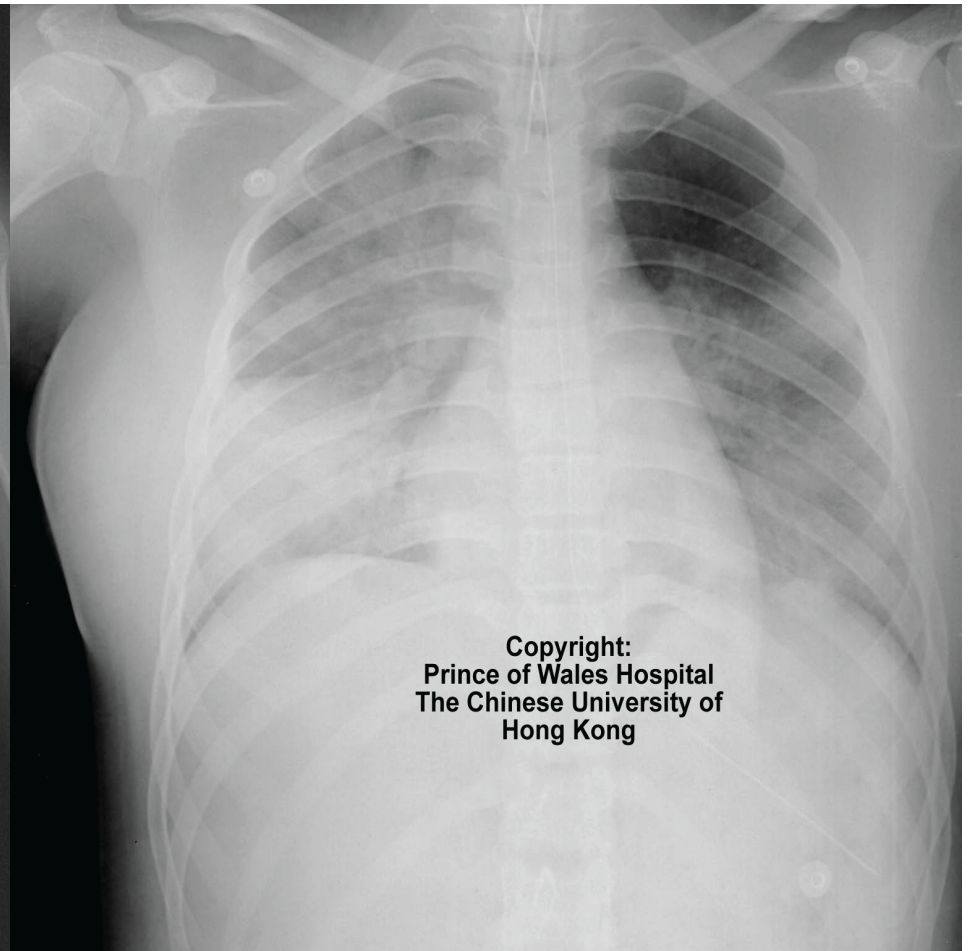
Died 21/12/97. cause of death intractable respiratory failure (hypoxia).

Avian Flu

Case One



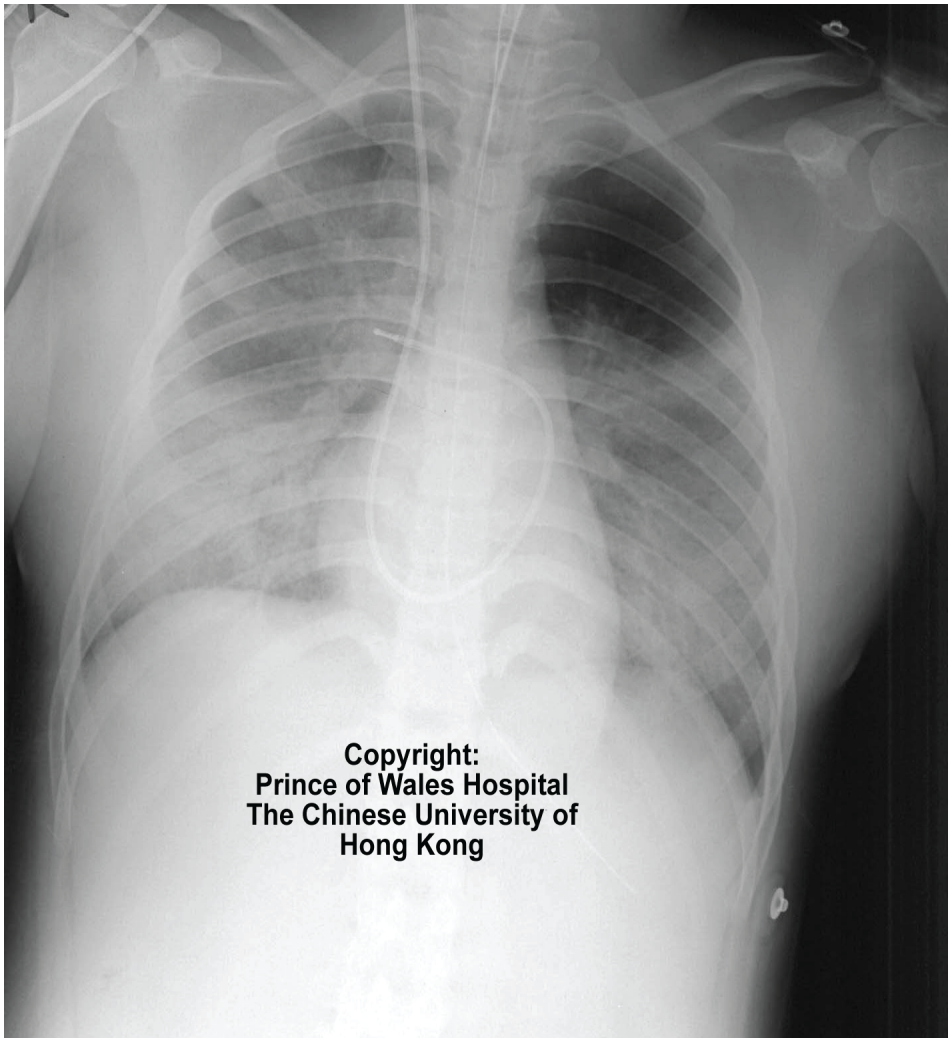
Day 2



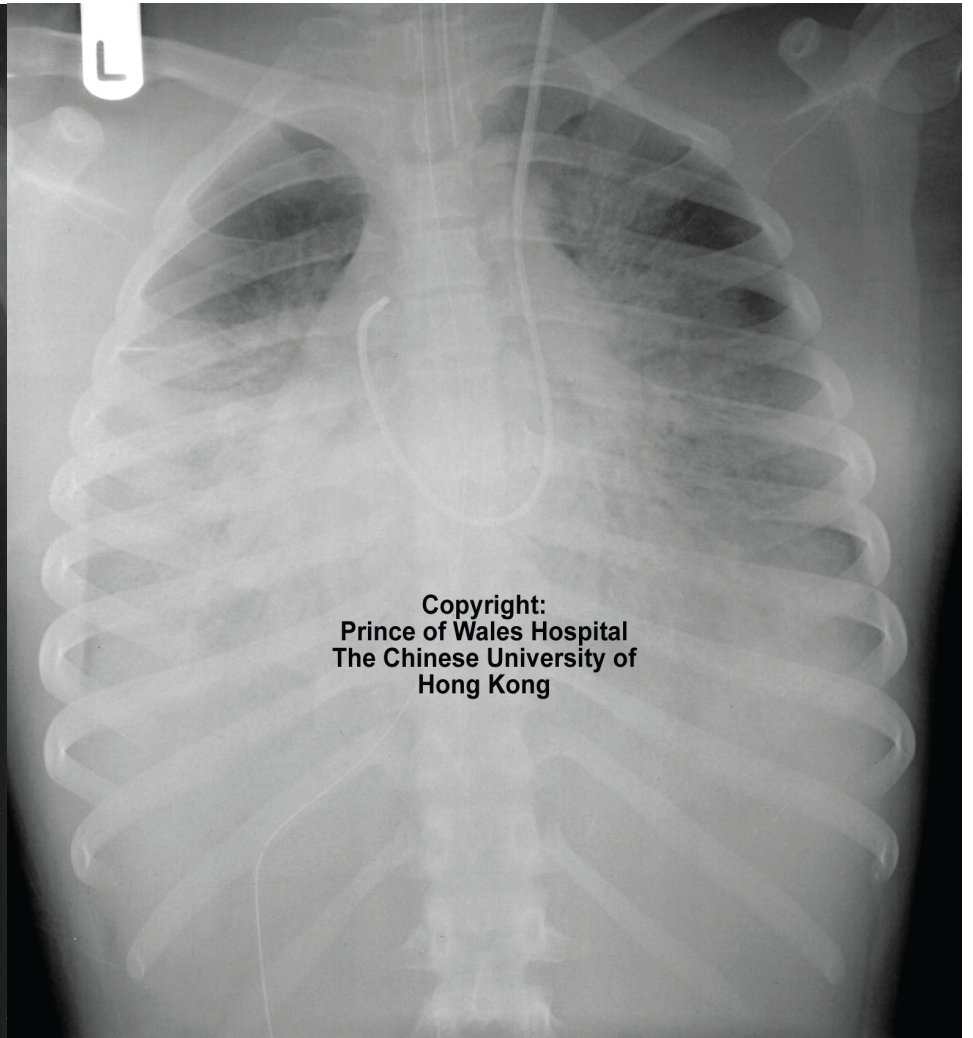
Day 3

Avian Flu

Case One



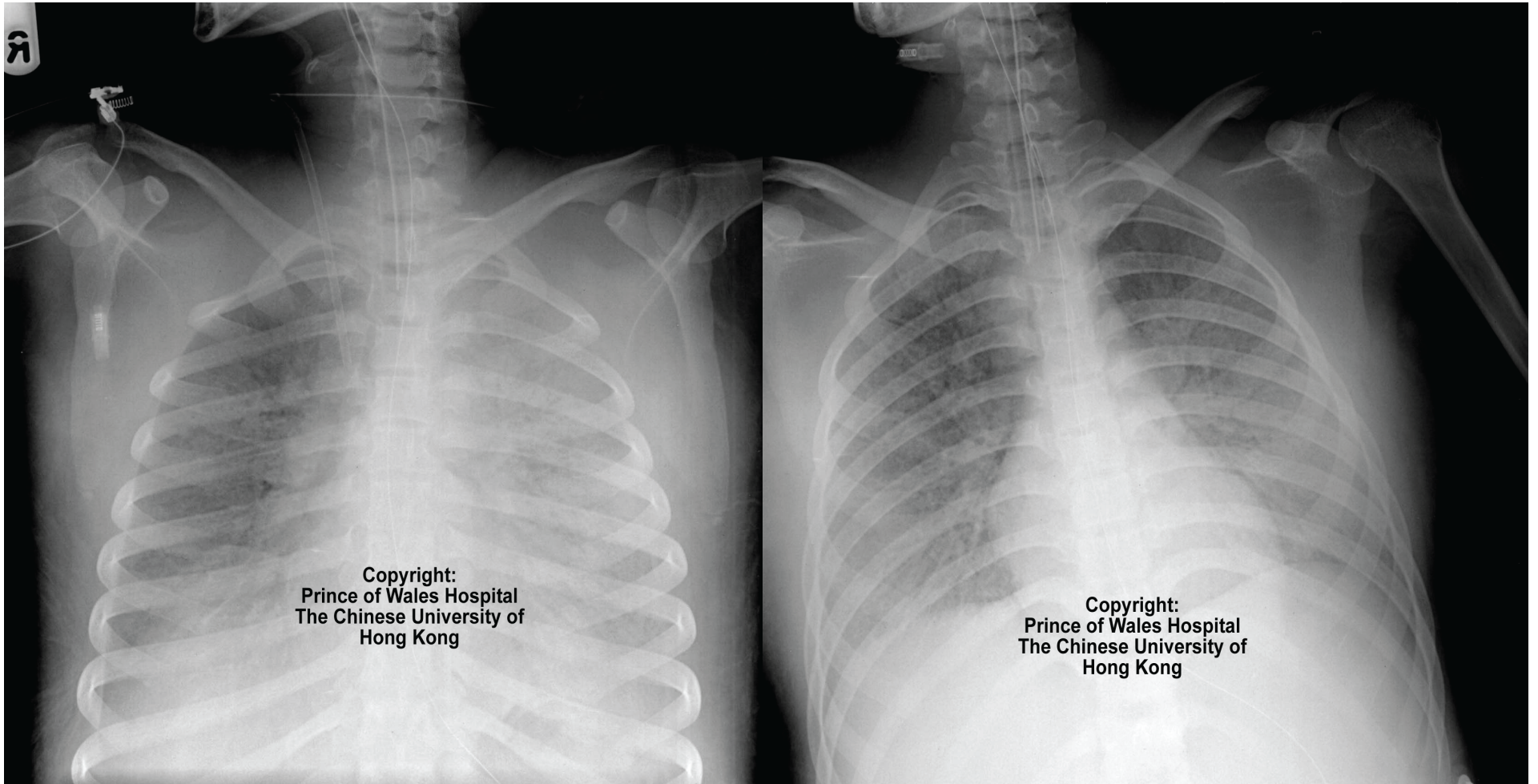
Day 4



Day 5

Avian Flu

Case One

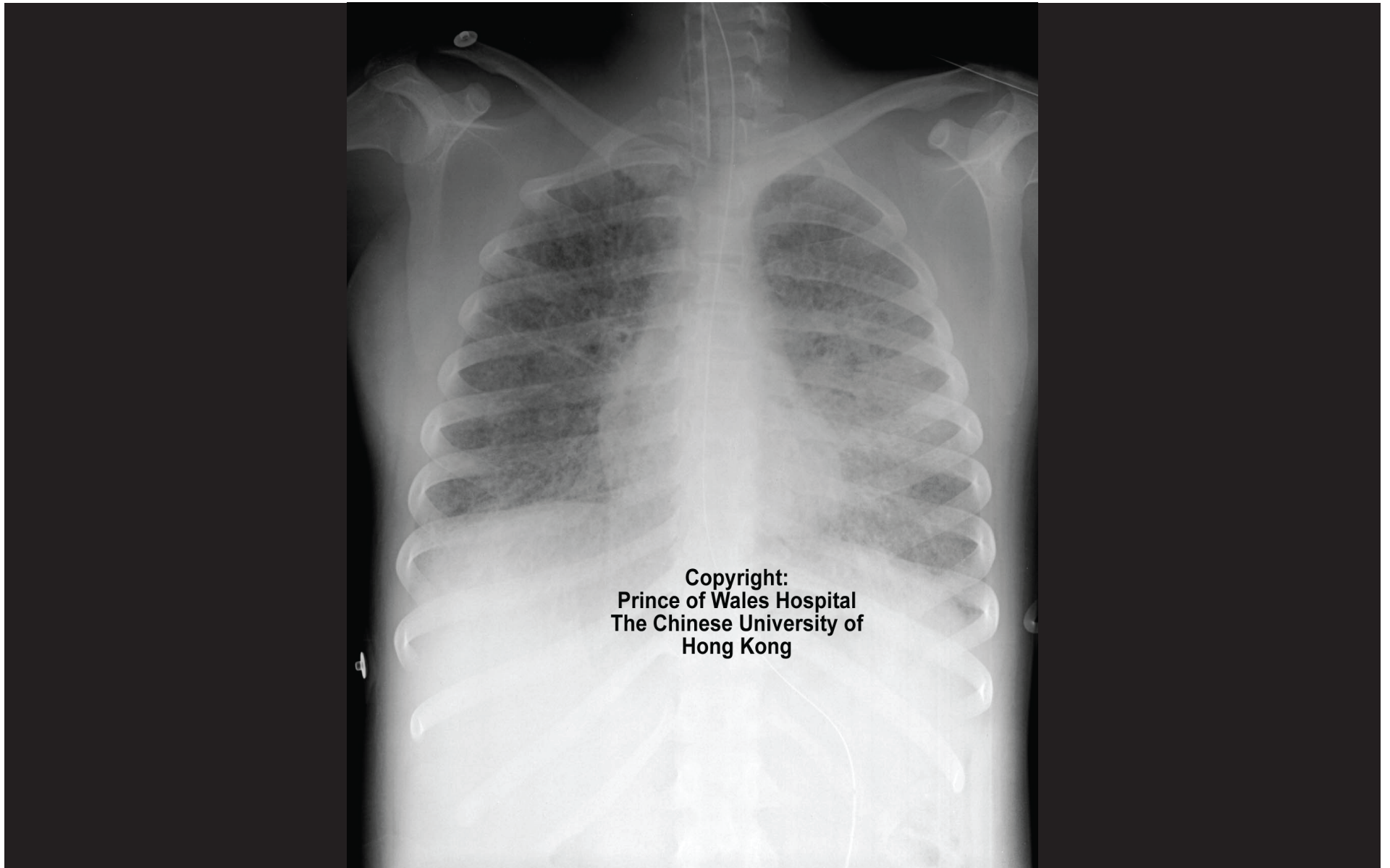

Day 9

Day 14

Avian Flu

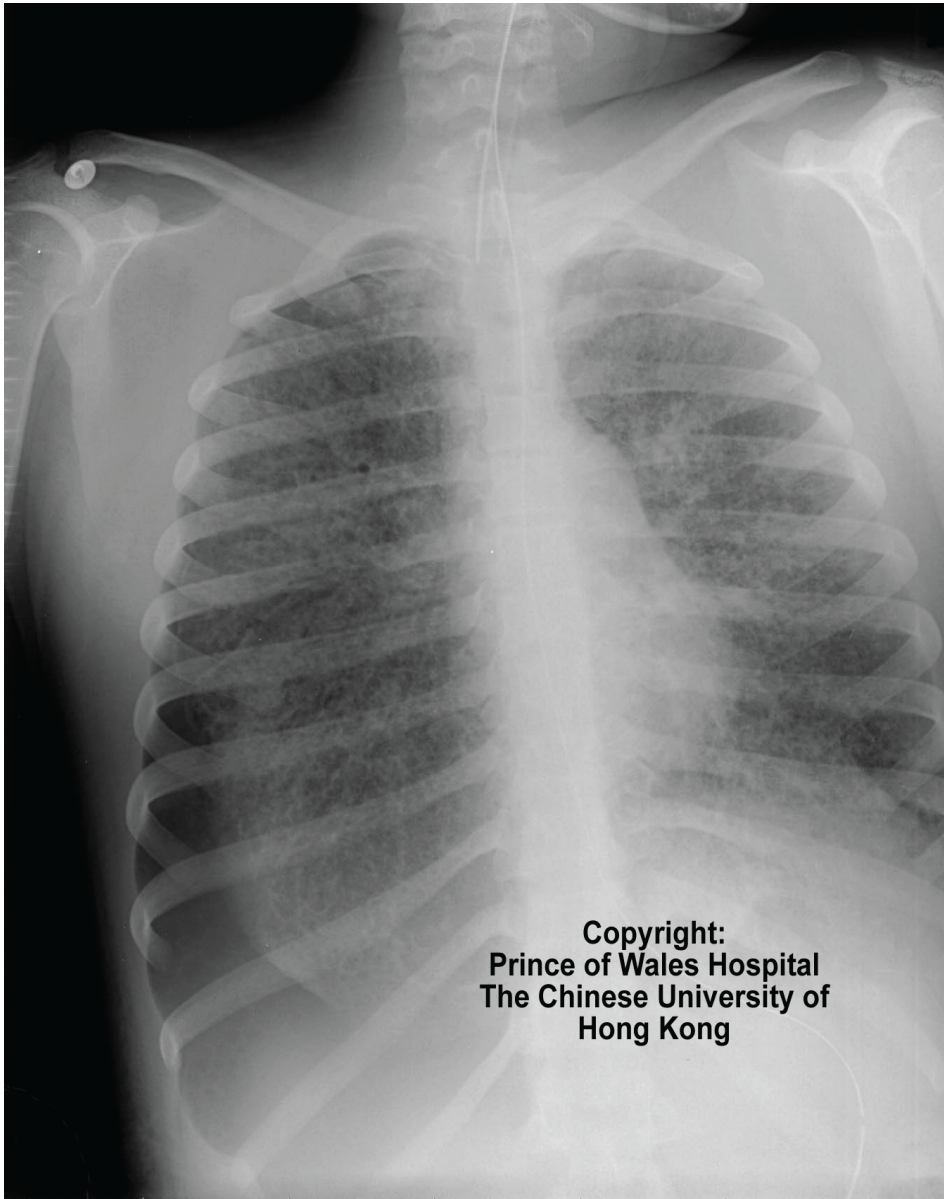
Case One



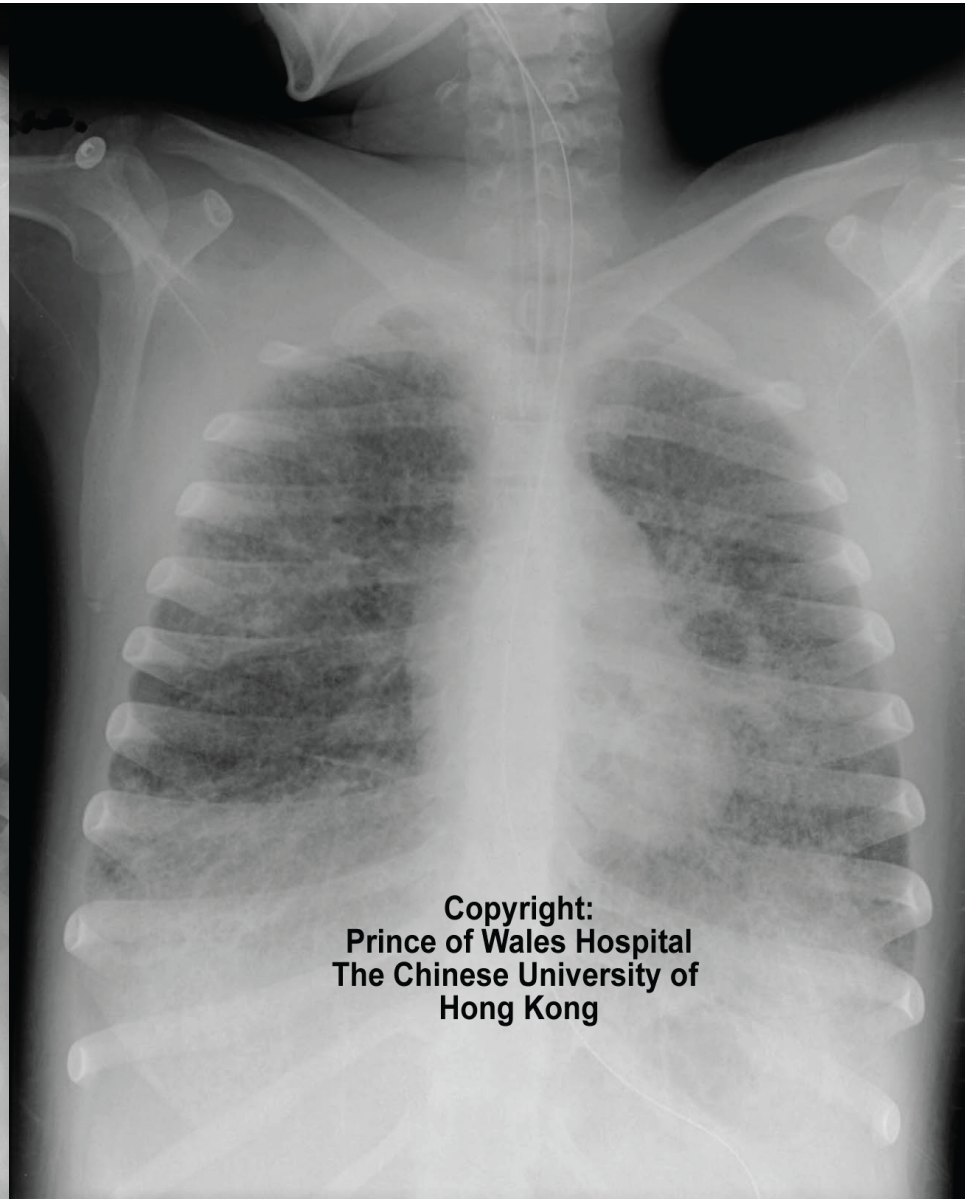
Day 20

Avian Flu

Case One



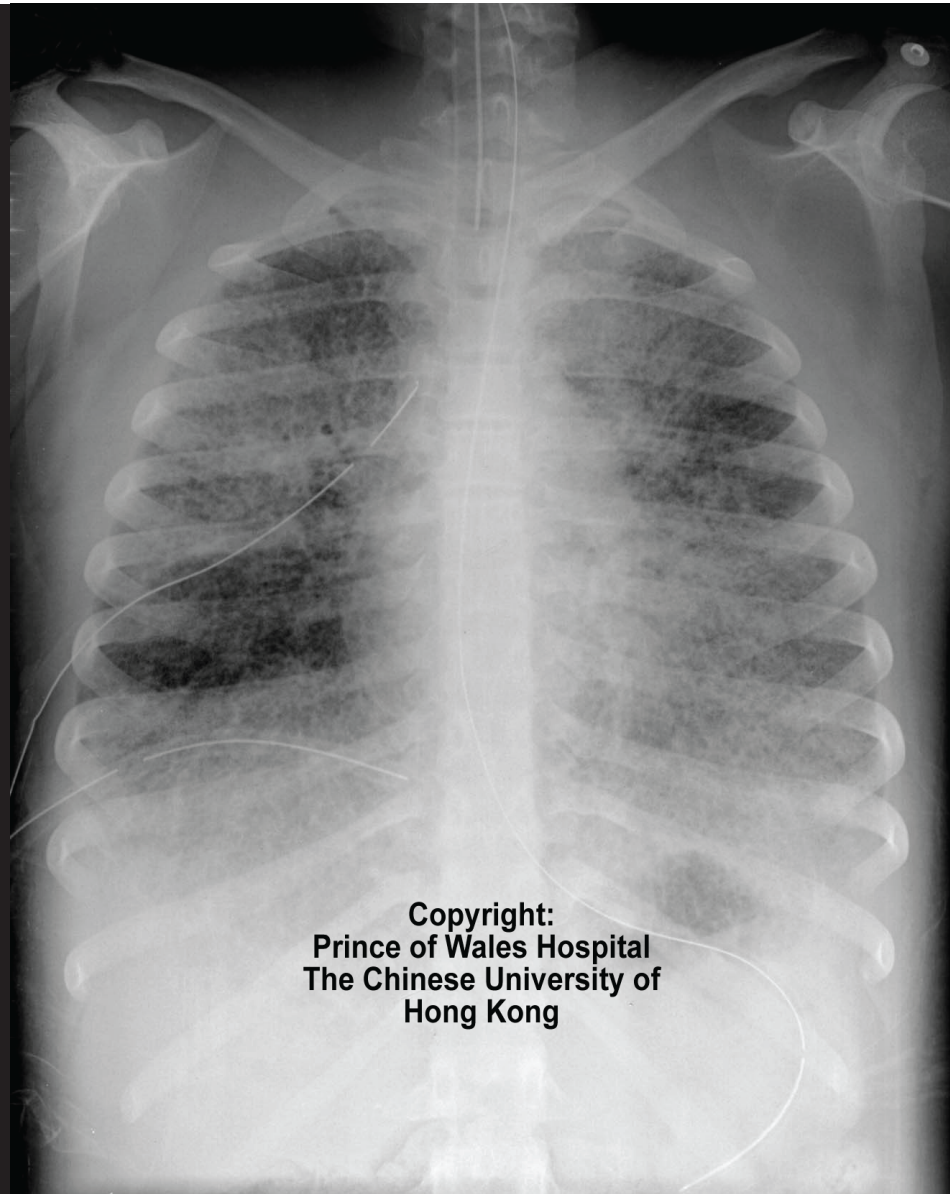
Day 23(1)



Day 23(2)

Avian Flu

Case One



Copyright:
Prince of Wales Hospital
The Chinese University of
Hong Kong

Day 26

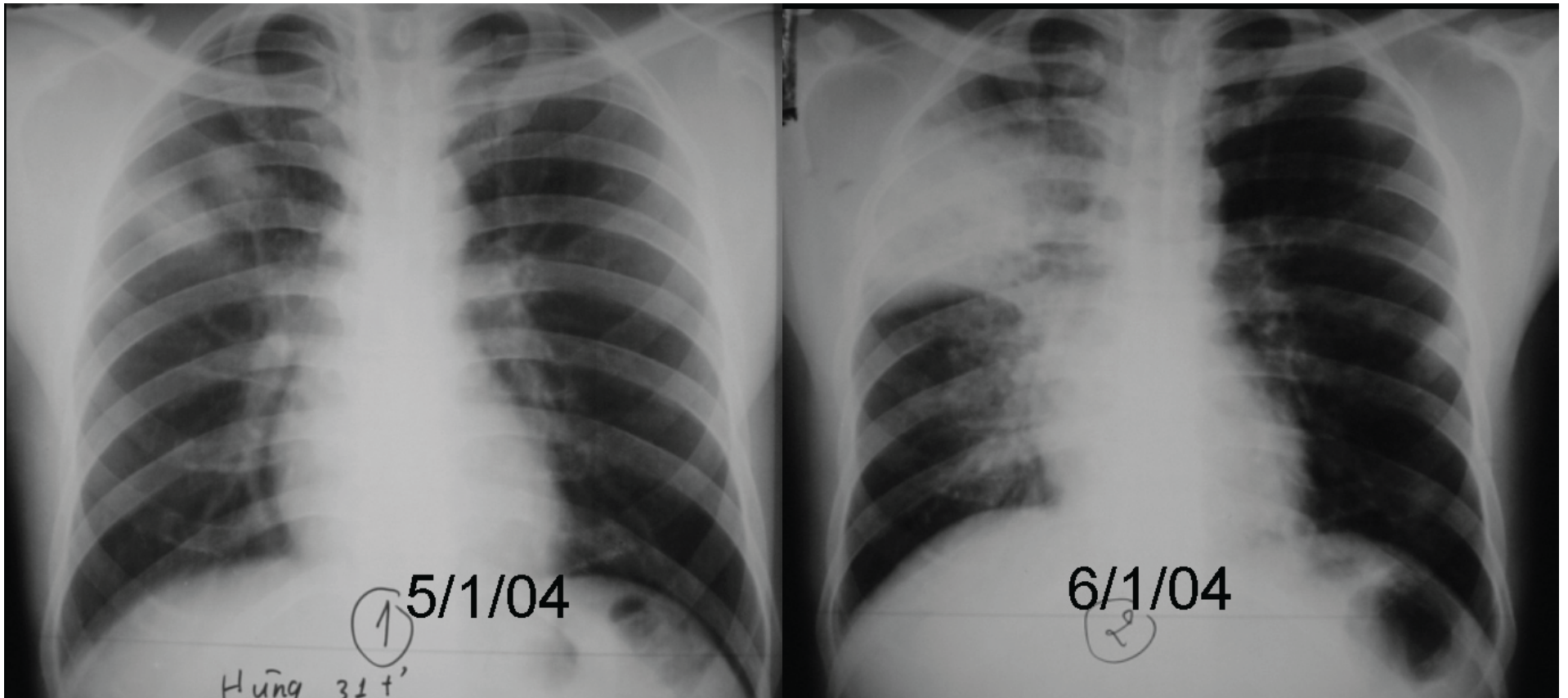
Avian Flu

Case Two

M 31 yrs: Exposed to dead chicken 5 days before illness (onset 3/1/04).

Fever 40C, malaise, dry cough, SOB, headache for 2 days.

His 2 sisters died of confirmed H5N1 2 weeks later.

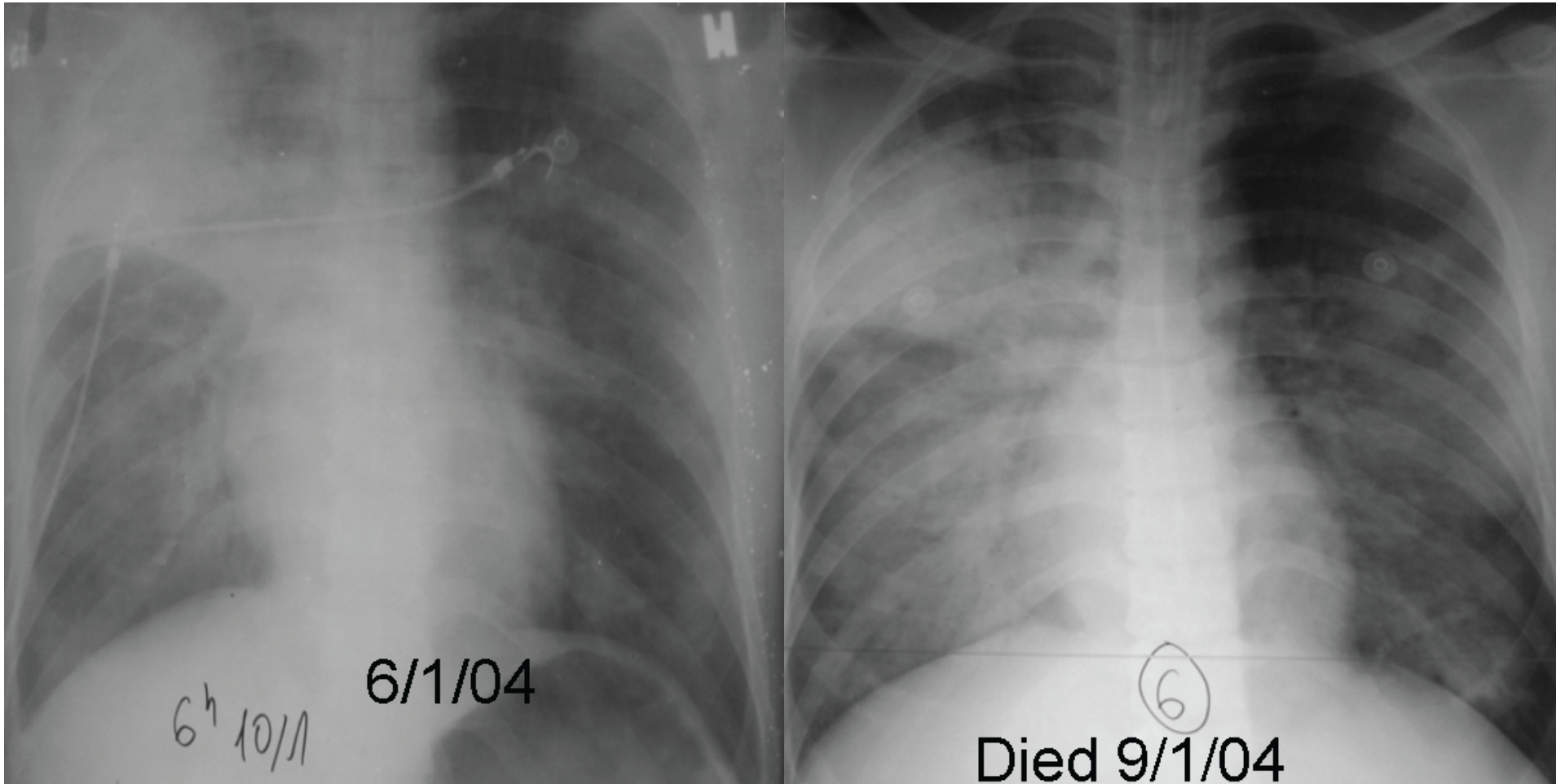


5/1/2004

6/1/2004-1

Avian Flu

Case Two



6/1/2004-2

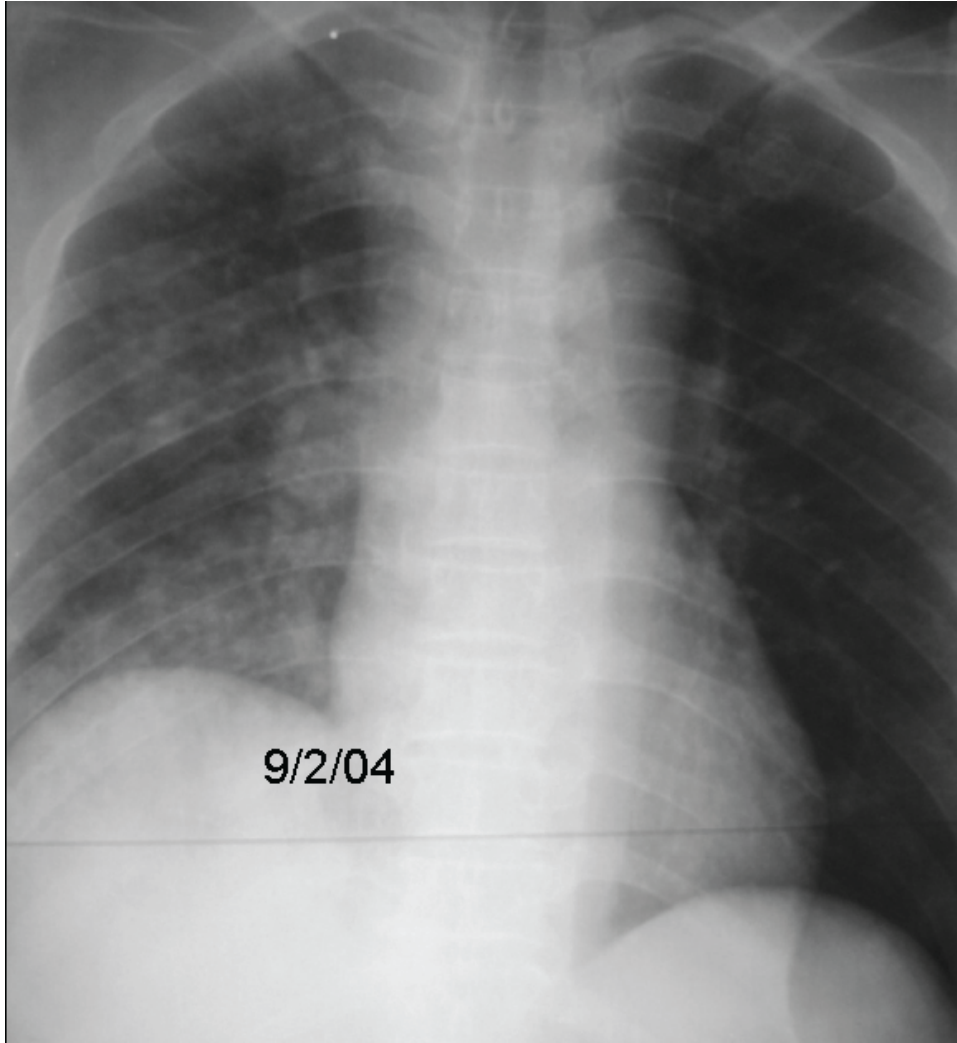
9/1/2004

Avian Flu

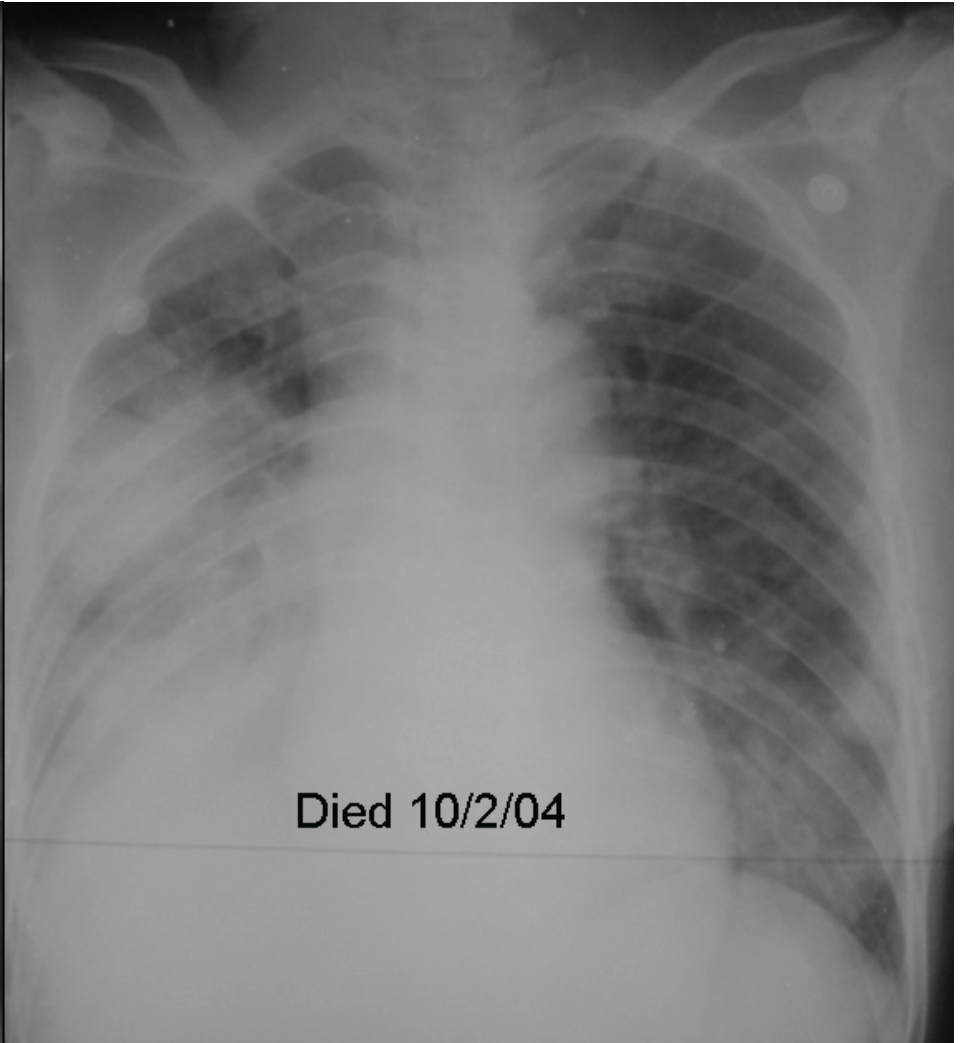
Case Three

M/52 yrs old: Poultry farm worker, contact with dead chicken. Fever 5 days / dry cough, runny nose & SOB for 2 days.

CPK 15820. Rx: Fortum & Amikacin.



9/2/2004

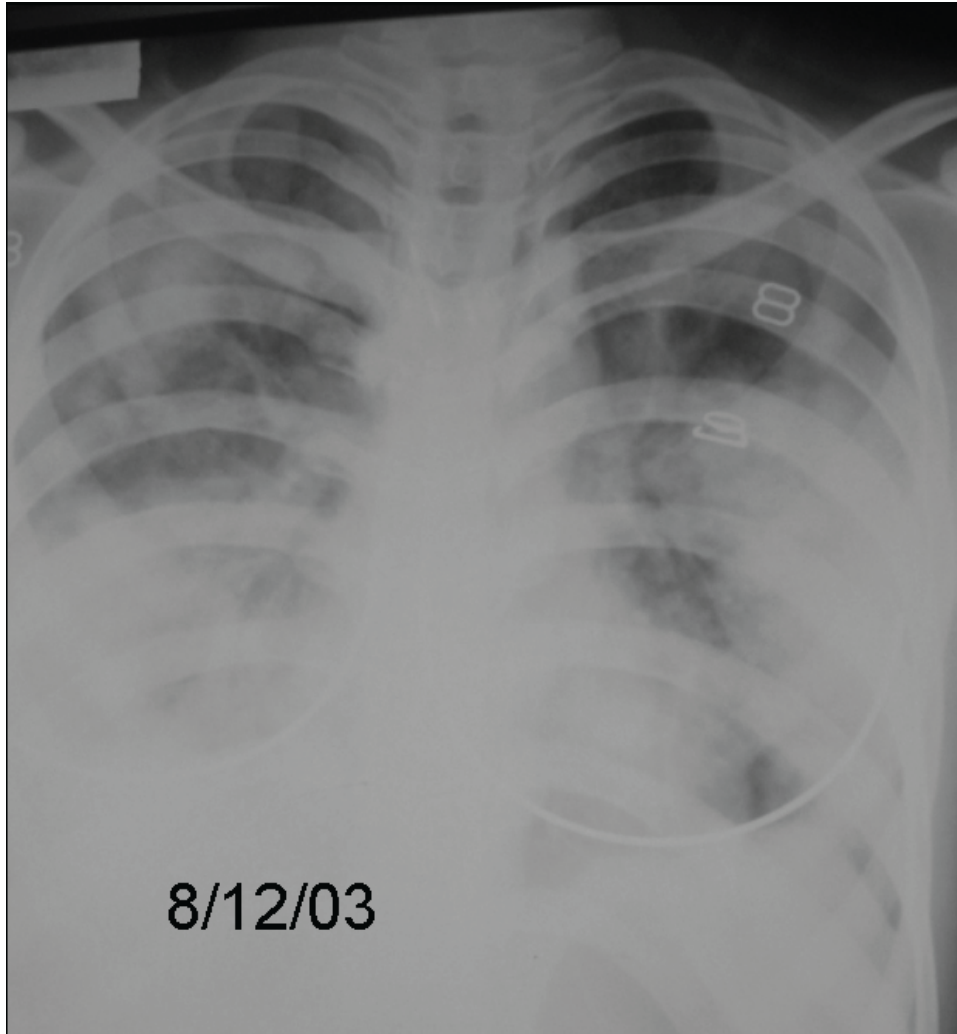


10/2/2004

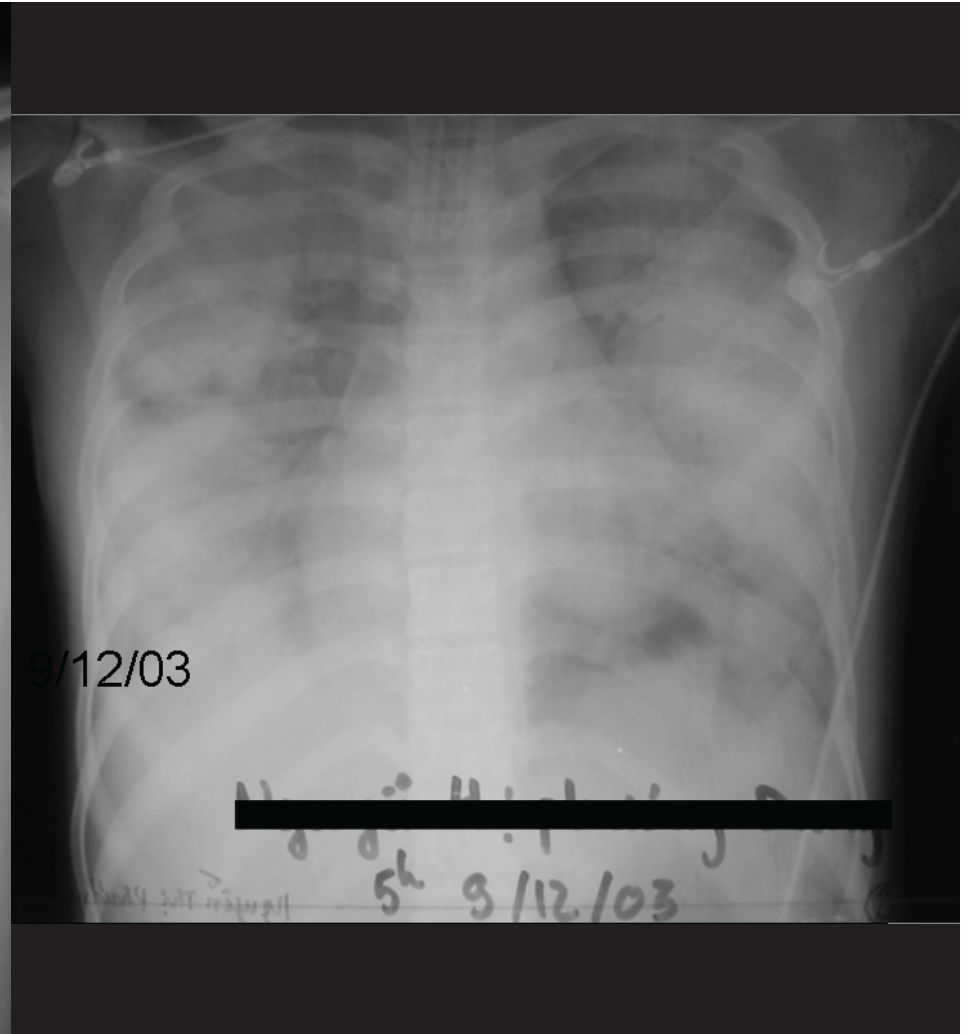
Avian Flu

Case Four

M/19 yrs: Poultry farm worker with contact of dead chicken. Fever, productive cough, SOB since 5/12/03. WBC 2.1, L=0.6, Plt 30, Normal fibrinogen & APTT. Urea 15.4, Cr 238, ALT 49, AST 397. Rx: cefotaxime, gentamicin.



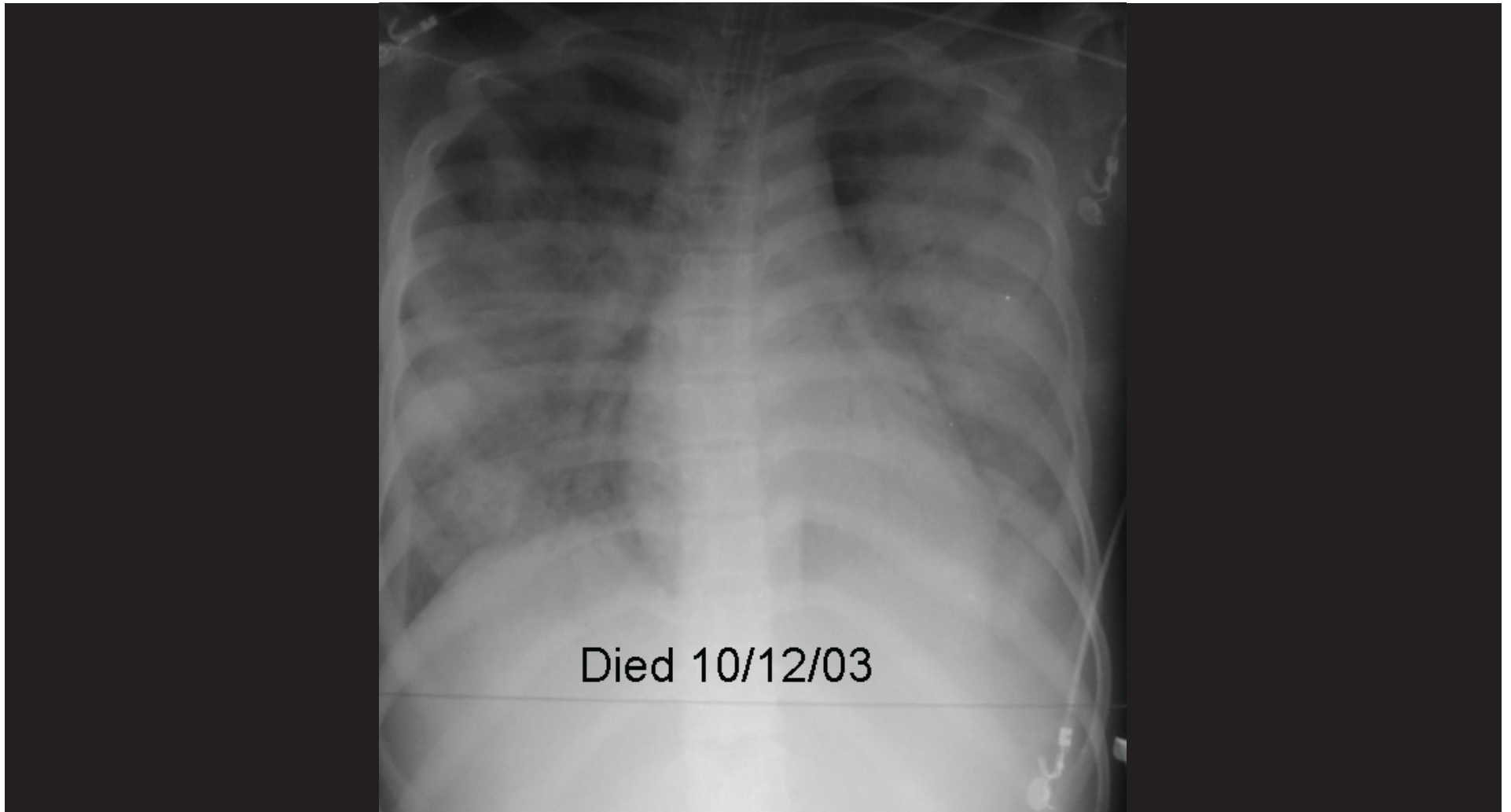
8/12/2003



9/12/2003

Avian Flu

Case Four



10/12/2003

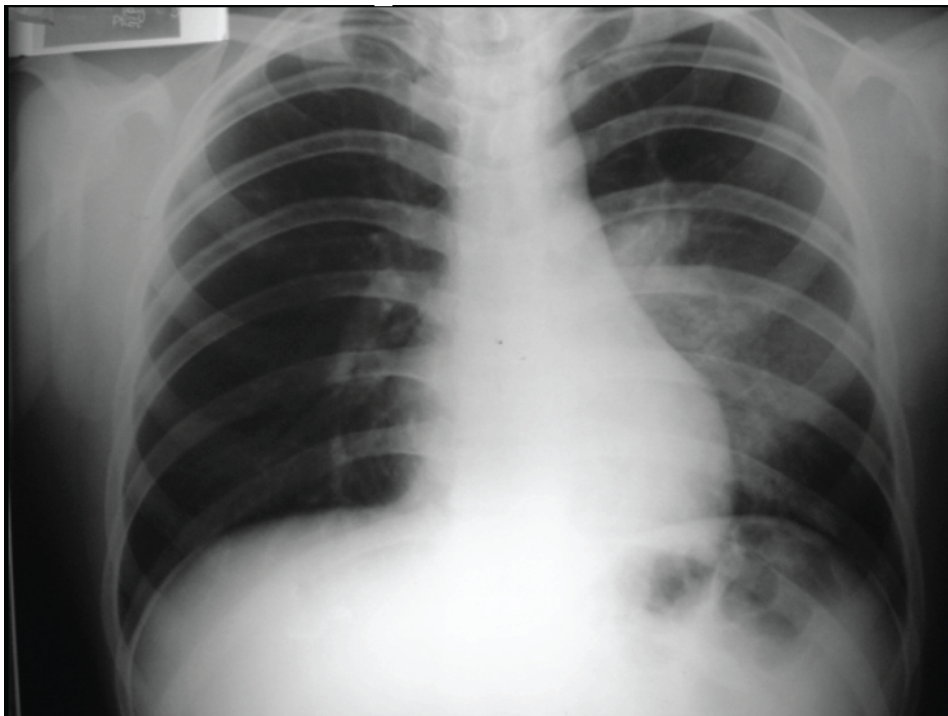
Avian Flu

Case Five

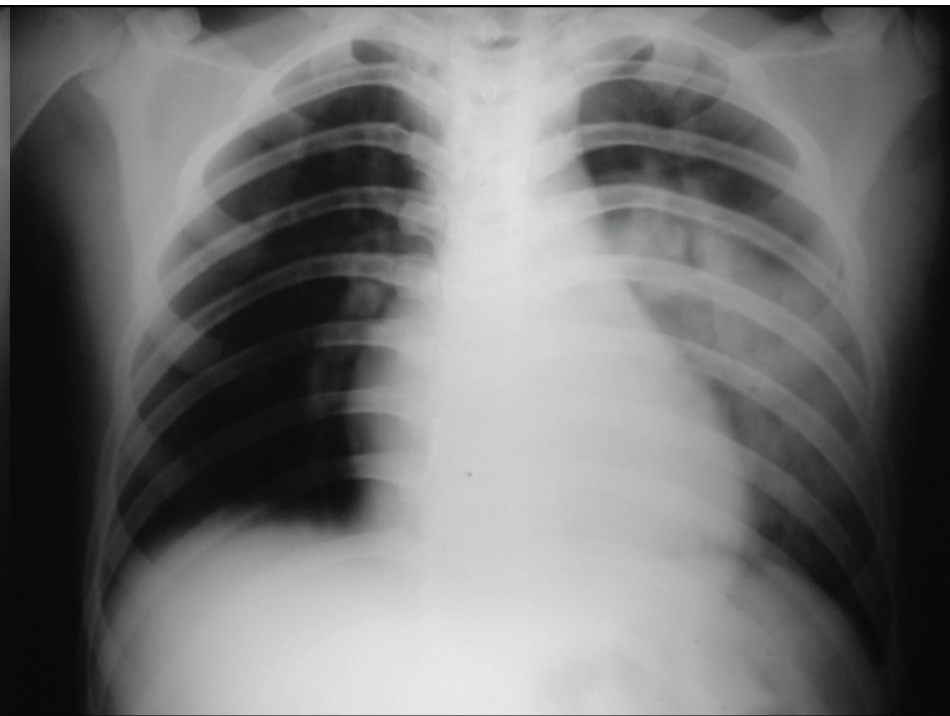M/23 yrs: Farmer. Contact with dead chicken 3 days prior to illness. T38.7C, Productive cough, SOB, diarrhoea.

Admitted to HCM Hosp for Tropical Dis 7 days after onset. SpO2 90% on 40% oxygen. Hb 17.6, WBC 3.9, Lym 0.7, Plt 102, Cr 121, ALT 89, AST 110.

RTPCR positive for H5N1.



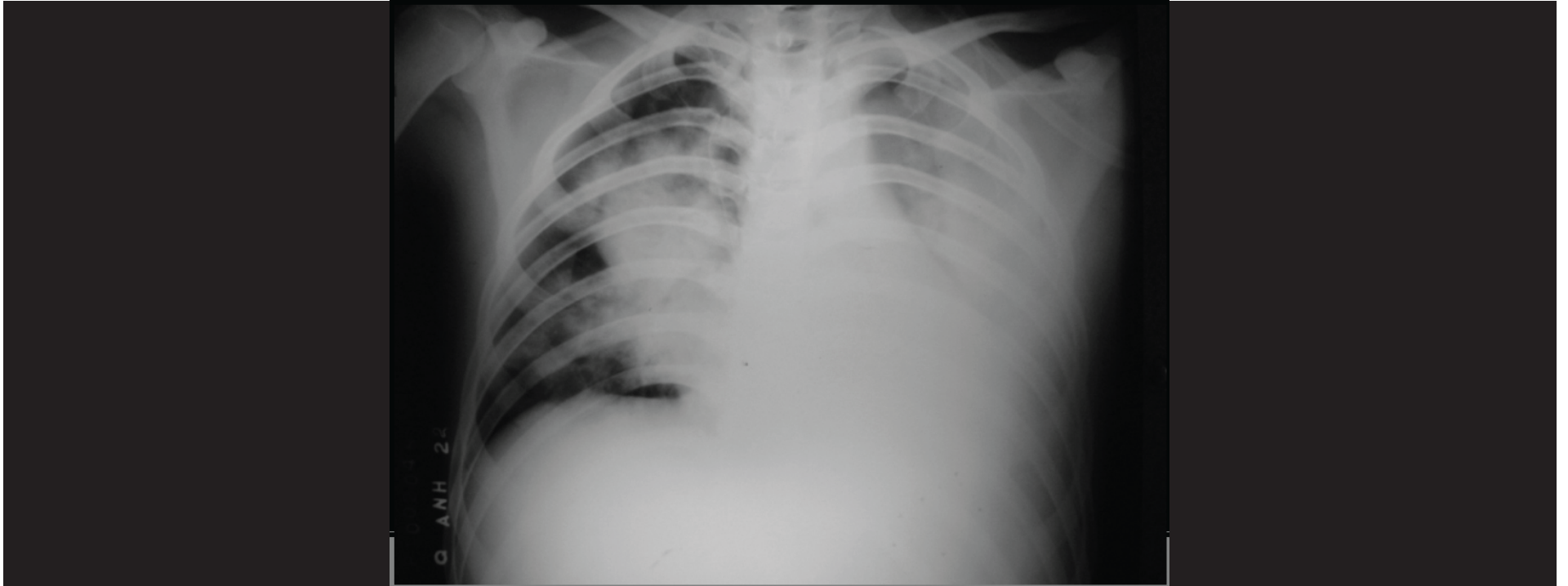
Critically ill-1



Critically ill-2

Avian Flu

Case Five

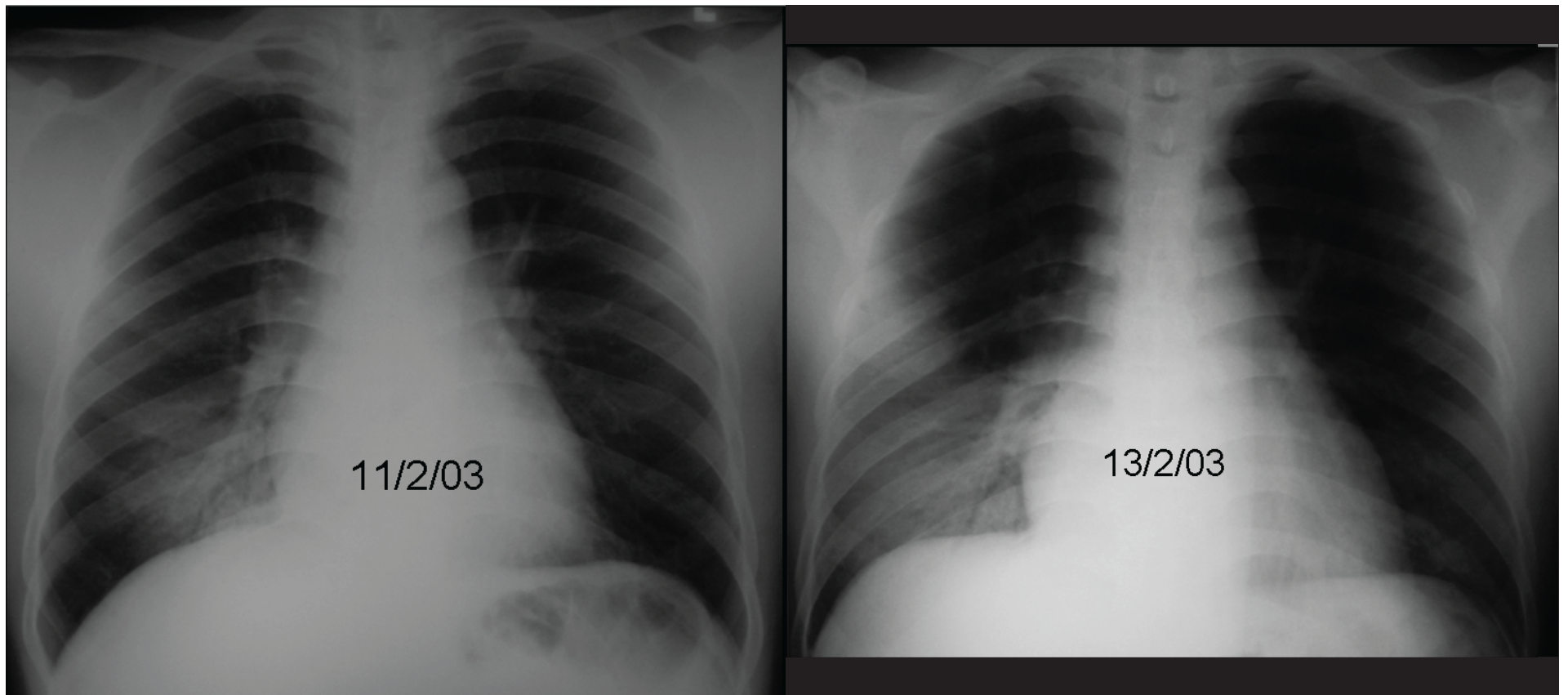


Critically ill-3

Avian Flu

Case Six

M 33 yrs/Princess Margaret Hospital,
Hong Kong: returned from Fujian with fever, chills, cough since 7/2/03.
Lymphopenia, increased ALT.
ARDS & MODS on 14/2/03.
Died on 17/2/03

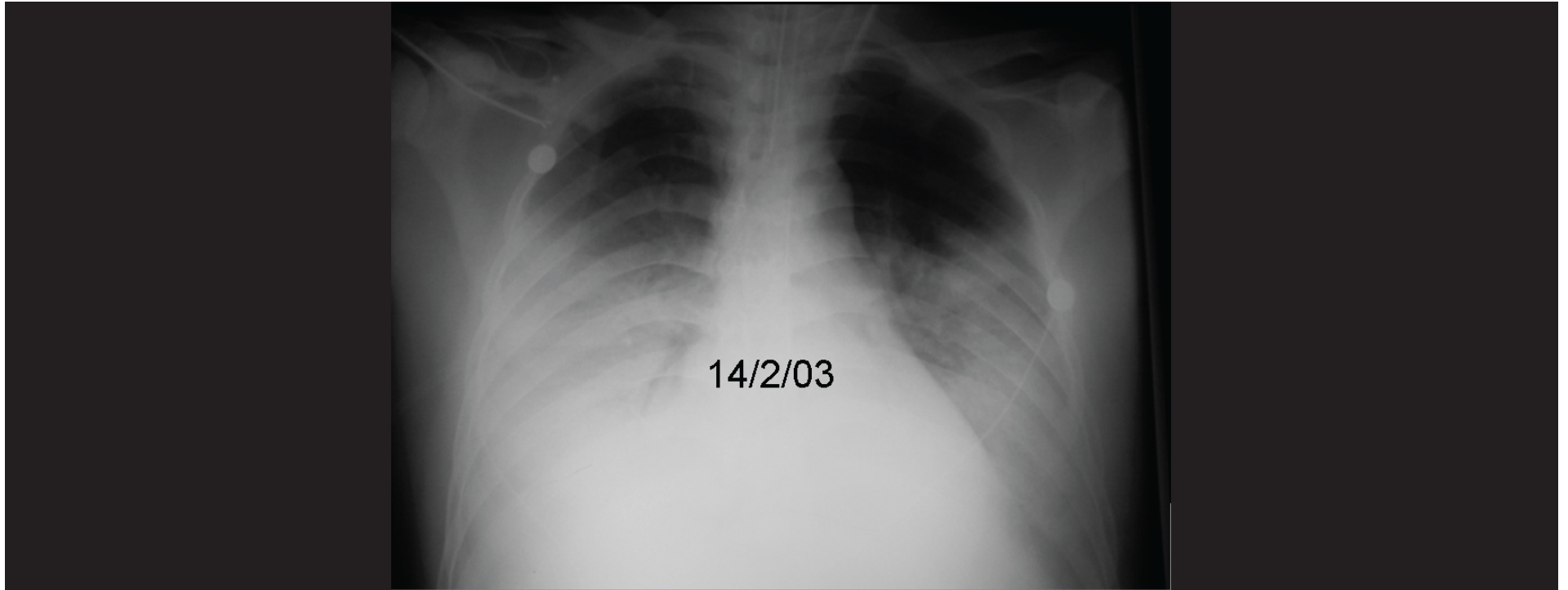


11/2/2003

13/2/2003

Avian Flu

Case Six



14/2/2003

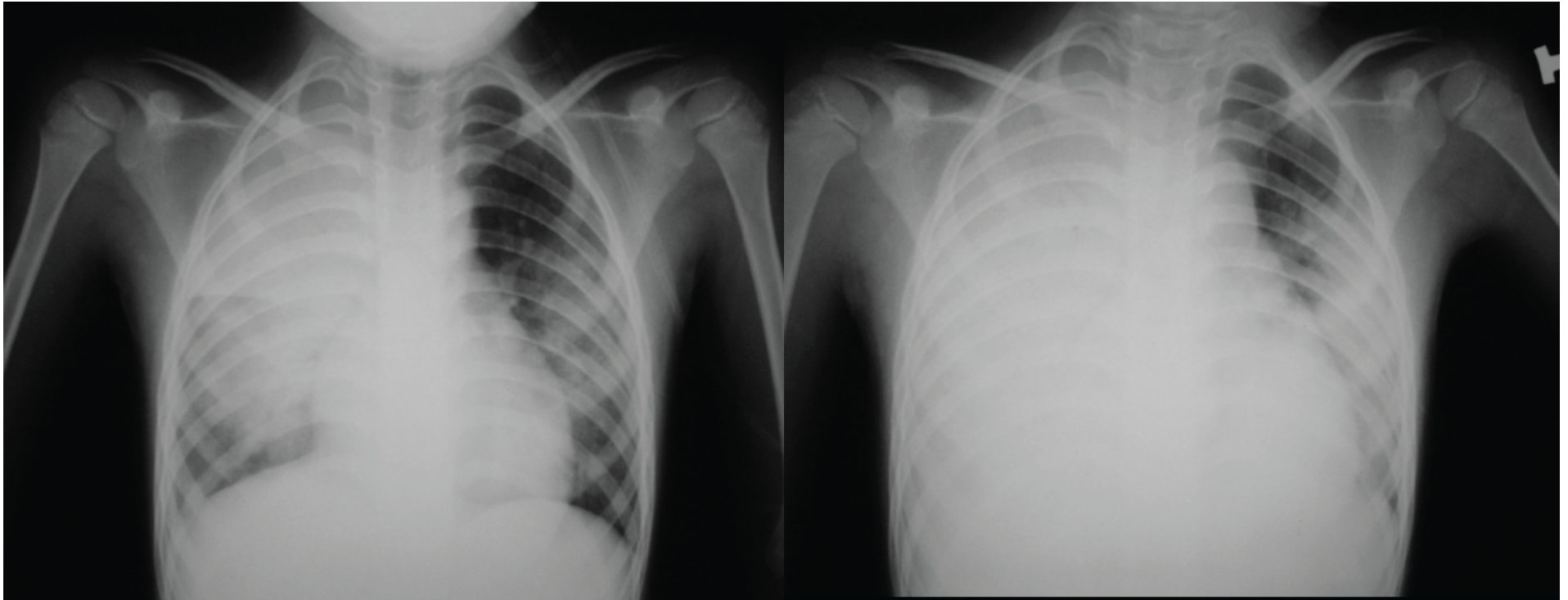
Avian Flu

Case Seven

F/6 yr, fever for 8 days, developed acute respiratory distress

Adm WBC $2.4 \times 10^9/L$, L $0.5 \times 10^9/L$, plt $127 \times 10^9/L$, ALT 246 IU/L, AST 1379 IU/L, nasal swab H5 Ag +ve

Given Methylpred 5 mg/kg/day and Tamiflu. Died 3 days after admission

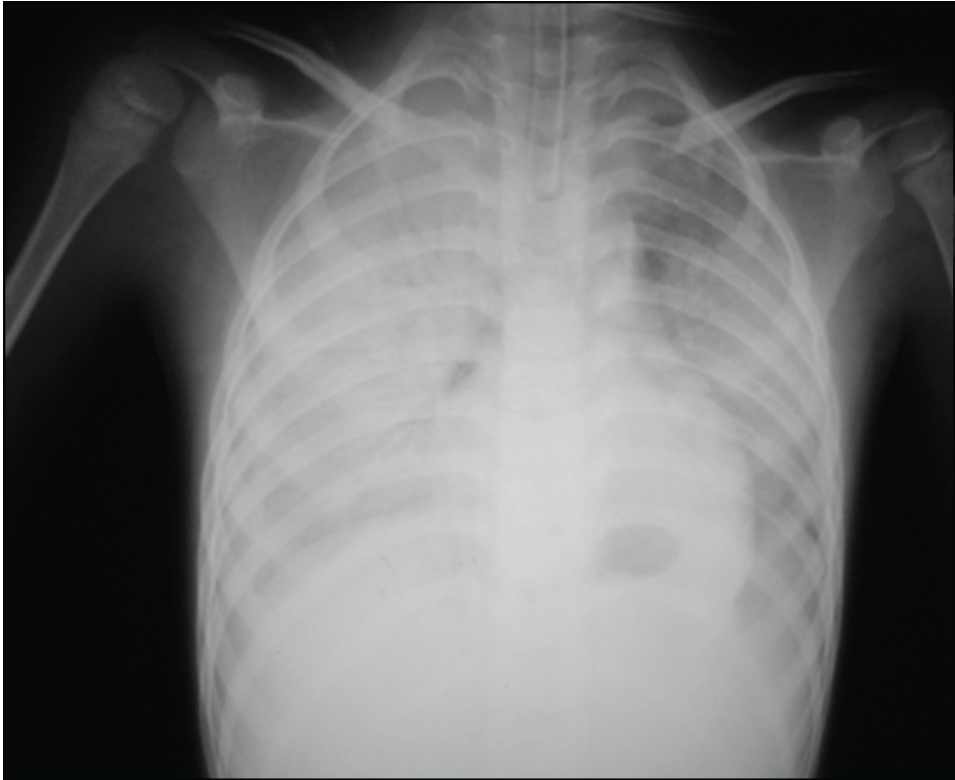


CXR on admission

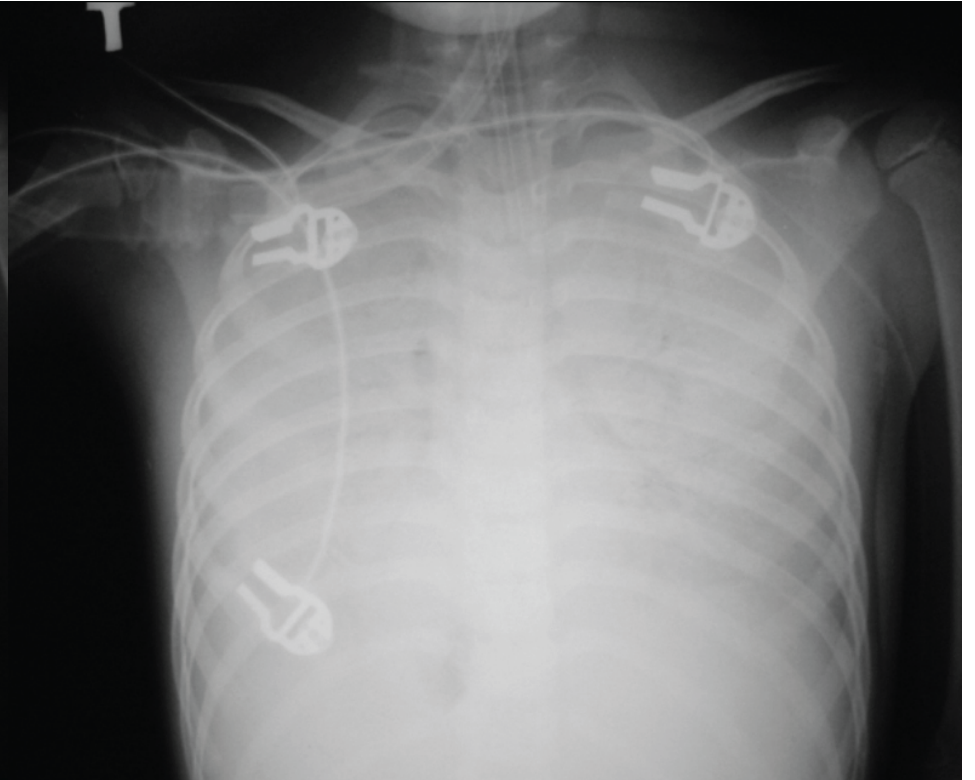
CXR 6 hours after admission

Avian Flu

Case Seven



CXR on day 2



CXR on day 3