
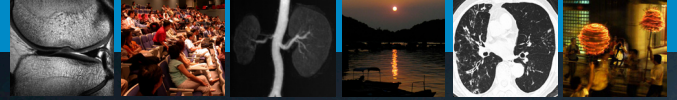



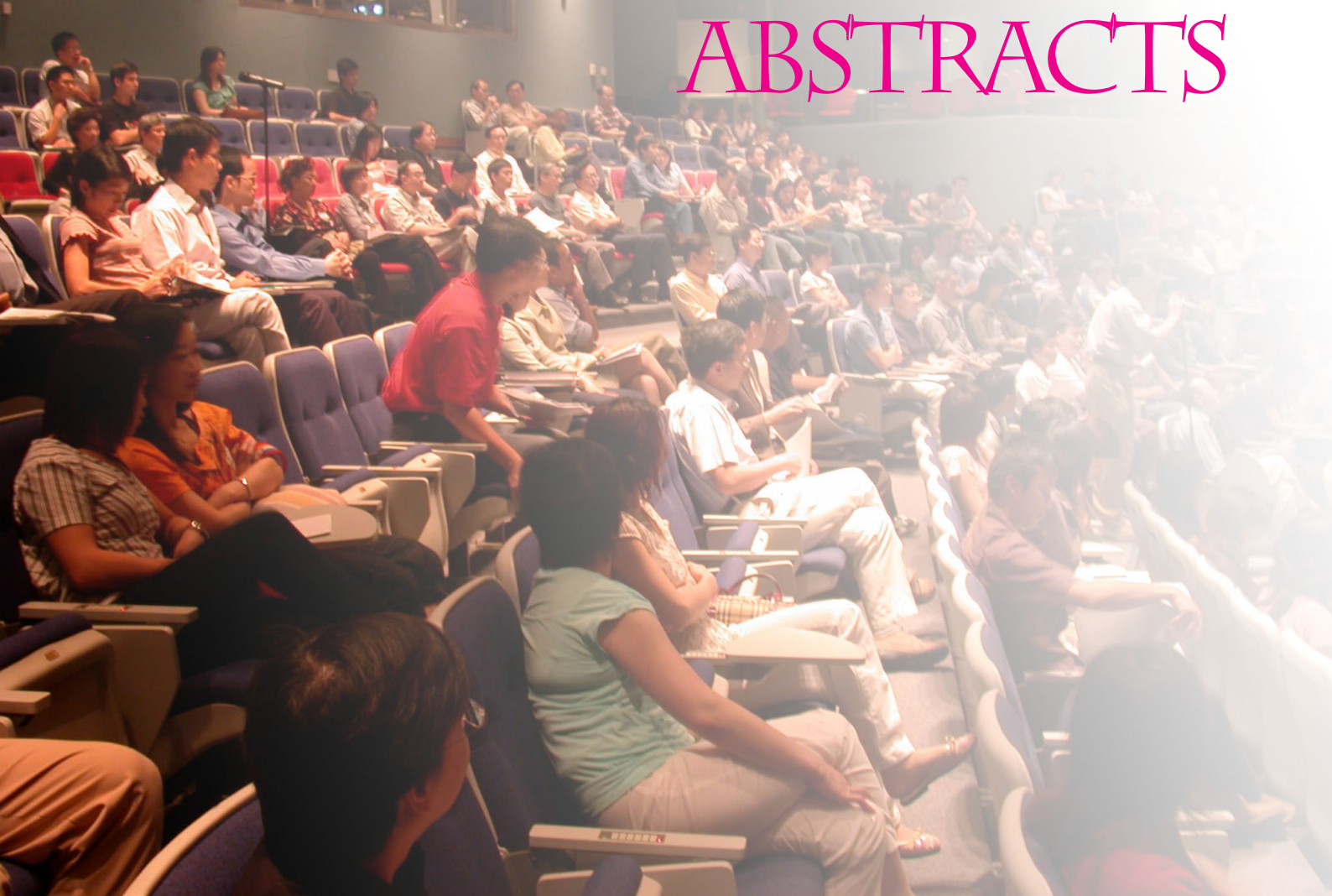
# International Imaging Course

24-25 September 2005

The Chinese University of Hong Kong  
Department of Diagnostic Radiology and Organ Imaging



## ABSTRACTS

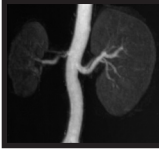

SPONSORS:  
Major Sponsors



Other Sponsors



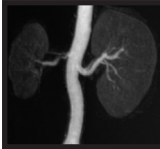

Vascular Imaging Session

## Vascular surgeons versus radiologist

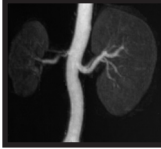*Dr. Yuk Hoi Lam*

Technological advances have constantly opened new dimensions in the therapy of patients with vascular diseases. Conditions that were treated previously only by open surgery can now be managed by interventional radiological means with comparable or sometimes superior short-term results. The development offers an excellent solution for modern societies in which an increasing number of ageing and 'medically unfit' patients with vascular problems would now be no longer denied of treatment. Even previously forbidden problems are now circumvented by expedient application of modern endovascular devices and the proliferation of endovascular therapy in the last decade sees the potential to relegate traditional open surgery. Nonetheless the vascular-surgeons-versus-radiologists contention, or rather collaboration, continues to energize the hotbed for further development in vascular therapy.



Since its introduction in the early 90's, CT and MRI are used increasingly to study the vascular structures. It has become the imaging modalities of choice for many clinical situations such as aortic aneurysm, organ donor workup just to mention a few. This lecture will concentrate on abdominal applications.

1. Introduction to imaging techniques – CTA and MRA
  - a. Scanning Technique
  - b. Contrast dynamics
  - c. Post-processing
2. Applications in abdomen
  - a. Aortic diseases
    - i. Aneurysms
    - ii. Dissection
    - iii. Aortoarteritis
  - b. Visceral Arteries
    - i. Liver
      1. Pre-operative workup for malignancy
      2. Organ donor workup
      3. Post-liver transplant complications
    - ii. Pancreas
      1. Pre-operative workup for malignancy
    - iii. Kidney
      1. Renal artery stenosis
      2. Congenital renal vascular disorders
      3. Organ donor workup
      4. Renal vein disorder
      5. Others
    - iv. Mesenteric arteries
  - c. Venous structures
    - i. Portal vein
      1. Portal hypertension
      2. Thrombosis
    - ii. IVC
3. Future development
  - a. On the horizon.



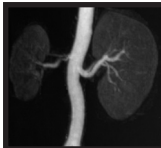Vascular Imaging Session

## Imaging of peripheral vascular and venous diseases

*Prof. Simon S.M. Ho*

This will be a two-part lecture. The first part of the lecture will focus on the imaging of peripheral vascular disease. Conventional imaging of peripheral vascular disease has been based on digital subtractive angiography and duplex Doppler ultrasound, which have the disadvantage of being invasive and operator dependent respectively. Recent years have seen exciting new developments in magnetic resonance angiography (MRA) and computed tomography angiography (CTA), and these two techniques are increasingly utilised as the non-invasive imaging modality of choice in peripheral vascular disease. The techniques, limitations and relative roles in treatment planning (endovascular and surgical intervention) of these imaging modalities will be discussed and current literature will be reviewed.

The second part of the lecture will cover some aspects of the imaging of venous diseases. The role of MRI and CT in the assessment of deep vein thrombosis and central venous obstruction will be discussed with particular reference to pre-procedural planning in endovascular intervention – namely caval filter placement, catheter directed thrombolysis and central venous stenting. The use of duplex Doppler ultrasound in the diagnosis of deep vein thrombosis will be discussed in another lecture by another speaker.



The introduction of colour Doppler imaging in the early eighties added a new dimension to vascular diagnosis. Nowadays, vascular ultrasound utilizing colour Doppler imaging (high-resolution gray-scale imaging, colour-coded imaging and spectral analysis) is widely applied in different clinical entities such as peripheral arterial disease, deep vein thrombosis, chronic venous insufficiency, renal artery stenosis in native and transplanted kidneys, intracranial and extracranial arterial disease, graft surveillance, and other vascular abnormalities such as arteriovenous fistula, aneurysms and portosystemic shunts etc.

Colour Doppler imaging, which is developed based on the concept of Doppler phenomenon, is frequency and angle-dependent. The frequency of the transducer used determines the sensitivity of an ultrasound system depicting the flow in a blood vessel. The lower the transducer frequency used, the more sensitive it is to pick up a trickle flow. The angle of insonation affects the magnitude of Doppler signals. In clinical practice, it is preferable to maintain the angle of insonation to the vessel as small as possible in order to obtain strong Doppler signals. In addition, the angle should be no greater than 60 degrees. An angle greater than 60 degrees tends to overestimate the flow velocity and significantly affects the accuracy of estimating an arterial stenosis in which velocity parameters are based upon.

To render an accurate diagnosis, the information available on the colour coded image and velocity spectrum must be interpreted with caution. In general, the diagnostic criteria of colour Doppler vascular studies are derived from one or more of the following alterations in the blood flow of a vessel:

- change in flow velocity (increase or decrease)
- change in flow pulsatility or resistance (increase or decrease)
- change in flow direction (retrograde flow)
- change in the shape of spectral waveform (triphasic to biphasic or vice versa, monophasic and tardus-parvus waveform, arterialization of venous signals and loss of respiratory venous phasicity), and
- change in intraluminal colour filling (absent, partial, turbulent).

In arterial occlusive disease, a focal peak systolic velocity (PSV) increase accompanied by post-stenotic flow disturbance is characteristic of a haemodynamically significant stenosis. In peripheral vascular disease of the lower limb, a focal PSV increase of more than 100% is indicative of a stenosis between 50 and 99% whilst a focal PSV increase  $>180\text{cm/s}$  and  $>230\text{cm/s}$  are predictive of a  $\geq 60\%$  renal artery stenosis and a  $\geq 70\%$  internal carotid artery stenosis, respectively. In all cases, post-stenotic flow disturbance and/or dampened down-stream waveforms should be present. Low velocity monophasic or high resistance waveforms will be obtained proximal to a near or total arterial occlusion in which no or trickle intraluminal colour Doppler signals can be found. Surrounding collaterals reconstituting the flow distal to the occlusion may be demonstrated.

Flow direction is scrutinized in the studies of chronic venous insufficiency, subclavian steal syndrome and collateralization secondary to total/subtotal common carotid artery occlusion. Flow reflux in a venous segment with duration either longer than 0.5 sec with patient standing or greater than 2.0 sec with patient supine during Valsalva Manoeuvre or manual distal flow augmentation, is diagnostic of chronic venous insufficiency with valvular incompetence. Retrograde flow present in the vertebral artery is indicative of a significant stenosis at or near the origin of the ipsilateral subclavian artery, resulting in subclavian steal syndrome. In cases of total or subtotal common carotid artery occlusion, demonstration of retrograde flow in the ipsilateral external carotid artery is a sign of collateral pathway via this vessel. To ensure diagnostic accuracy, proper interpretation of the alterations of the flow velocity, flow resistance, flow direction, velocity waveform shape and colour filling is hence crucial.

Vascular ultrasound is a time-consuming investigation and requires experienced hands for a proper examination. The accuracy greatly depends on the operator's knowledge on vascular anatomy and haemodynamic principles as well as his/her scanning technique. With the expertise, ultrasound can provide valuable information that sometimes MRA and DSA fail to offer. Therefore ultrasound is not only an ideal diagnostic tool for the screening of vascular disease and monitoring of graft surveillance but also a useful adjunct to these sophisticated imaging modalities.

### References

1. Strandness DE, Jr. Duplex scanning in vascular ultrasound 3rd ed. Lippincott Philadelphia: Williams & Wilkins, 2002.
2. Grant EG, Benson CB, Moneta GL, et al. Carotid artery stenosis: gray-scale and Doppler US diagnosis--Society of Radiologists in Ultrasound Consensus Conference. Radiology. 2003; 229:340-6.

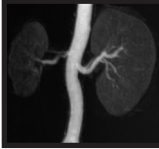

Vascular Imaging Session

## Neurosurgeon's perspective on imaging

*Dr. George K.C. Wong*

Advances in three-dimensional imaging and blood flow study have greatly enhanced the capacity for patient assessment and operating planing in neurosurgery. This presentation aims to highlight the different modalities in vascular neurosurgery commonly requested from neurosurgeons and in what aspects they assist in clinical management.

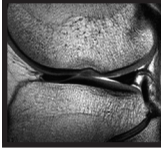


This lecture provides an update of recent development in computed tomography (CT) and magnetic resonance imaging (MRI) for evaluation of cerebrovascular diseases. With the rapid technological advances in both modalities, CT or/ and MR angiography has almost replaced the invasive catheter angiography which used to be considered as the gold standard with its unsurpassed spatial and temporal resolutions.

The major breakthrough in CT angiography is the continued development of helical CT scanners into multi-detector CT that dramatically enhances the speed as well as unprecedented spatial resolution approaching that of the conventional angiography. True isotropic volumetric data set and exquisite 3D reconstruction could be readily achieved with state-of-the-art 64-slice CT scanner. These advances are crucial in the accurate anatomical depiction of intracranial steno-occlusive disease or aneurysm.

Nevertheless, MRI remains the workhorse in neurovascular imaging. Time-of-flight intracranial MR angiography is widely accepted as the modality of choice for preliminary cerebrovascular assessment without the added hazards of ionizing radiation and iodinated contrast agents of CTA. Extracranial MR angiogram with bolus-chasing technique also proves to be comparable to conventional angiogram in the assessment of carotid artery stenosis. Continued improvement in temporal resolution with time-resolved MR cerebral angiogram becomes possible without significant sacrifice of spatial resolution and signal-to-noise ratio following introduction of high field (3 tesla) clinical scanner. This opens an entire new horizon in the assessment of arteriovenous malformation.

Last but not the least, CT or MR perfusion study has been increasingly been utilized for functional study of cerebrovascular status with quantitative assessment of cerebral blood flow or even cerebrovascular reserve. Previously, this haemodynamic information could only be obtained with radionuclide or PET brain scans.

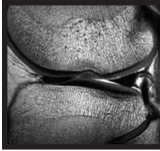


Musculoskeletal Imaging Session

## Shoulder: Rotator cuff including SLAP lesions

*Prof. Donald Resnick*





## Shoulder: Rotator cuff ultrasound

*Prof. James F. Griffith*

Over the past eight years, we have performed more shoulder ultrasound examinations than shoulder MRI examinations at PWH. While the most common indication for shoulder MRI is instability, the vast majority of shoulder cuff ultrasound examinations are performed to look at the rotator cuff. It is also fortunate that the portion of the rotator cuff where pathology occurs is particularly assessable to examination by ultrasound allowing almost a complete evaluation in all cases. The arm needs to be moved into various positions to show each of the rotator cuff components to best effect.

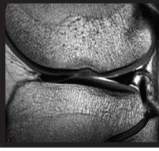
The three main pathologies affecting the rotator cuff are tendinosis, tendon tears and subacromial-subdeltoid bursitis. Tendinosis (or tendon degeneration) is associated with proteoglycan accumulation within the tendon substance. This leads to tendon weakening and tears. Tendinosis is a very common pathology. All of the rotator cuff tendons are susceptible though particularly the supraspinatus and long head of biceps tendons. On ultrasound, it manifests as increasing tendon thickening and hypoechogenicity. Even if it is entirely asymptomatic, you should not use the contralateral side as a comparative control. Similar though often slightly less severe disease is present on the contralateral side and this is often entirely asymptomatic. Tendinosis is graded, rather subjectively, as mild, moderate severe or very severe.

Tears may be complete (i.e. the whole tendon is torn) or partial (i.e. only part of the whole tendon is torn). Partial tears may be partial-thickness or full-thickness. Tears usually occur as avulsive-type injuries rather than affecting the 'critical zone', which is located just proximal to the insertion. The anterior and middle fibers of the supraspinatus tendon are the most prone to tears and these should be inspected very closely. The hallmark is tendon discontinuity or non-visibility. When a tear is encountered measure its anteroposterior and mediolateral dimension.

Subacromial-subdeltoid bursitis is also a commonly encountered pathology. The cardinal sign is fluid in the bursa. Bursitis should be carefully sought since this is the likely source of the patient's pain. Tear and tendinosis may be asymptomatic though bursitis rarely is. Bursal fluid should be sought with the arm in a neutral position as the various maneuvers used to demonstrate the tendons to best effect compress and redistribute bursal fluid. Usually it is difficult to quantify the degree of bursitis present and this is usually graded, correctly or incorrectly, as mild or moderate depending on the degree of fluid present. If one encounters a severe degree of bursitis, one should consider an underlying inflammatory arthropathy.

When it comes to depicting tears, in experienced hands, the accuracy of both ultrasound and MRI is comparable. In other words, accuracy should not be an issue when deciding whether to do an ultrasound or MRI examination for rotator cuff pain. Ultrasound has the advantage of being quicker, cheaper, more available, and probably allowing a more accurate assessment of early tendinosis, particularly of the biceps tendon. Ultrasound also facilitates guided aspirations and injections and patients overall prefer ultrasound examination to MRI examination. MRI is better at depicting structural changes such as osteophytic spurs, coracoacromial ligament thickening, acromial shape) that may have predisposed to tendon degeneration. MRI also allows a more global picture, allows the examination to be readily reviewed by a third party and is probably more accurate at depicting muscle bulk and lesser degrees of bursitis than ultrasound. MRI can also reveal SLAP lesions that are not demonstrable by ultrasound and can present in a similar fashion to rotator cuff disease.

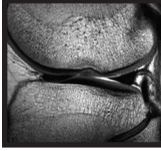
I would recommend ultrasound as the first line investigation for patients with suspected rotator cuff disease with MRI being used for those patients in whom arthroscopy is being considered or in those patients whom ultrasound fails to find a satisfactory explanation for symptoms.



Musculoskeletal Imaging Session

## Cartilage injury

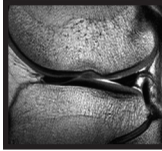
*Prof. Donald Resnick*



Musculoskeletal Imaging Session

## Knee: Meniscus-new concepts

*Prof. Donald Resnick*

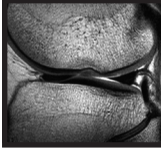


Developments in MRI are mainly focused on increasing field strength, new imaging sequences and more versatile post-processing software. Improvement of scanning technique tends to take a backseat and is left to the users.

This lecture discusses the use of the “Finger Coil” (small field of view surface coil) in large joints and other sites outside the fingers. Through a spectrum of physiology and pathology images, the attendees will be introduced to:

1. the physics behind the Finger Coil in terms of image quality
2. the pros and cons of using this coil for imaging
3. the required level of anatomical knowledge for image interpretation
4. considering changes in scanning practices.

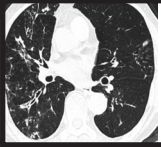
For musculoskeletal imaging, our experience has shown that the “Finger Coil” is most useful in the detailed examination of cartilage, menisci, and ligaments for various joints. Its use is akin to changing from a low frequency transducer to a high frequency transducer in sonographic interrogation.



Musculoskeletal Imaging Session

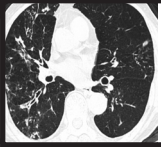
## Knee: Ligaments

*Prof. Donald Resnick*



Lung cancer remains a common and global problem in medicine; in this context there can be few radiologists who do not encounter this catastrophic disease in their working life. Whilst the plain chest radiograph is usually the first radiological investigation to highlight the possibility of a lung cancer, there are issues regarding sensitivity (lesions less than 1cm in diameter are generally inconspicuous) and specificity (plainly, not all intrapulmonary nodules are malignant!). Computed tomography (CT) has significant advantages over chest radiography: because there is no anatomical superimposition and the contrast resolution is so much higher, small lesions are more readily detected. Indeed, our ability to identify tiny intrapulmonary lesions has increased significantly with multidetector-row CT technology and has been aided by the development of computer software to automatically detect small nodules.

In addition to diagnosis, an important task for the radiologist is to stage the disease; accurate staging is a crucial step in planning treatment and defining prognosis. Understandably, the plain radiograph has a limited role in this regard and CT is the mainstay of investigation. Not only are the morphological characteristics of the primary lesion better defined on CT but the presence of nodal involvement and distant metastases may be identified. Although magnetic resonance imaging (MRI) has theoretical advantages over CT, it will be appreciated that, except in the specific scenario of a Pancoast tumour (where involvement or otherwise of the brachial plexus is an important surgical consideration), MR staging has no significant advantages over CT. However, it must also be remembered that the staging of lung cancer with CT is not always straightforward. A specific and important area of difficulty is in determining the significance of enlarged intrathoracic lymph nodes; traditionally, radiologists have relied on size criteria (a short axis diameter of less than 1cm tending to indicate benignity), when reporting on lymph nodes in patients with cancer. However, it is amply clear that the size of lymph nodes is not a wholly reliable guide: thus, not all large nodes have tumour and conversely, small nodes may contain metastatic foci. The advent of 18fluoro-deoxyglucose positron emission tomography (18FDG-PET) has rightly been regarded a major advance in the field of cancer staging: by highlighting regions of metabolically-active tissue, 18FDG-PET images can significantly influence the staging (both local and distant) of lung cancer.

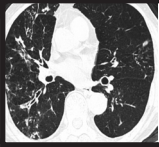


Chest Imaging Session

## Nuclear medicine in chest imaging

*Dr. Yat Yin Yau*

The role of NM is diminishing in the diagnostic arena of thoracic disease with advent of multi-detector spiral CT and 3T MRI. The savior comes with the arrival of PET-CT. The value and limitation of PET-CT will be discussed.



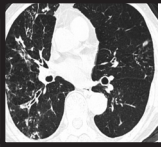
Diseases of the airways are common and imaging tests have an acknowledged role in evaluation. Plain chest radiography is the standard (and time-honoured) investigation. However, there are significant limitations because of problems including anatomical superimposition and limited contrast resolution. By comparison, computed tomography (CT), and more specifically, the technique of high-resolution CT (HRCT) has rapidly become an important and sensitive tool in study of patients with suspected airways disease.

From the radiologist's perspective, a common reason for imaging the large airways is when a diagnosis of bronchiectasis is suspected. As the reader will be aware, the term bronchiectasis refers to an irreversible dilatation of the airways usually associated with inflammation in the bronchial wall. Historically, the gold-standard test for bronchiectasis was bronchography, an invasive (and somewhat barbaric) procedure in which contrast was instilled into the bronchial tree. However, the advent of HRCT, has rendered obsolete bronchography.

Obliteration of the terminal and respiratory bronchioles (traditionally termed the "small airways") is surprisingly common and occurs in diverse clinical settings. A more important fact is that whilst the cross-sectional area of an individual peripheral airway is small, because of their number, the effective cross-sectional area of the small airways is considerable; thus, the distal airways offer little resistance to normal airflow. The clinical corollary is that considerable damage can occur in the small airways before a patient presents with symptoms. Historically, confusing terminology has plagued the classification of small airways disease. One proposal was to divide the small airways diseases into "constrictive" and "proliferative" forms. The term constrictive obliterative bronchiolitis (OB) captures the essence of the underlying pathological process: submucosal and peribronchiolar fibrosis causing narrowing and obliteration of the bronchiolar lumen. Unfortunately, the term proliferative bronchiolitis is more difficult to contend with and a more logical division into constrictive and exudative types has been proposed. The attraction of this dichotomy is that there are distinct clinical and (more importantly for the radiologist) imaging correlates of these two histopathological processes. In constrictive OB, a pattern of mosaic attenuation on CT (accentuated on images performed at residual volume) is the typical finding. As the term suggests, in the exudative bronchiolitis (typified by the entity of diffuse panbronchiolitis), the peripheral small airways are plugged with inflammatory exudate, giving a "tree-in-bud" pattern on CT.

The accompanying presentation will discuss the advantages and disadvantages of imaging tests in the investigation of airways disease. The radiological signs of airways disease (particularly those on CT) will be discussed (with reference, where possible, to the relationships between pathological changes and findings at CT). Some of the difficult areas of imaging in the diagnosis of large and small airways disease will be covered.





Pulmonary embolism is one of commonly encountered cardiovascular emergencies. Clinical features might suggest the diagnosis and imaging is required to confirm the diagnosis.

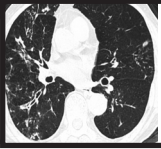
Chest radiography is usually normal in patients suffering from acute pulmonary embolism. In the past, pulmonary embolism is usually diagnosed by nuclear medicine imaging. Any mismatch in ventilation perfusion scan would suggest the diagnosis. There are intrinsic limitations of the investigation. Radiopharmaceuticals might not be readily available. Patients might suffer from shortness of breath and compromising the image quality of ventilation scan. Evaluation of pulmonary artery by computed tomography is possible. With a multi-detector CT, collimation of 0.625mm to 1.25mm could be achieved. In one of the previous study, using 1.25 mm collimation, up to 71-94% subsegmental arteries could be identified. With 0.625mm collimation, better accuracy and sensitivity of detection of subsegmental arteries is expected.

Patients with suspected pulmonary embolism usually receive 80-100ml iodinated contrast and the whole lung could be covered with one breath hold. The average acquisition time is 20 seconds and image might be compromised by motion artifact for those patients with severe shortness of breath.

Magnetic resonance angiography also allows evaluation of pulmonary artery. In one of the previous studies, sensitivity and specificity of 92% and 94% respectively could be achieved. Different magnetic resonance imaging technique could be employed. For patients with severe shortness of breath, contrast enhanced angiography can be performed within 3-5 seconds, though the spatial resolution would be compromised and only the main and major branches of pulmonary artery could be achieved.

Doppler imaging is usually employed for the detection of the source of pulmonary embolism, ie. deep vein thrombosis. CT venography and MR venography have proved feasible and in the future, it is possible to perform one stop examination by either CT or MRI and the deep vein system of the lower limbs and the pulmonary artery could be assessed in one examination.

Future development also include MR ventilation scan which either polarized gas or oxygen could be used for the evaluation of the lungs. With the combination of the MR perfusion, this will create a new imaging era for diagnosis of pulmonary embolism.

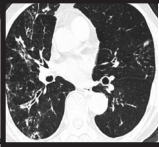


The diffuse interstitial lung diseases (DILDs) are a heterogeneous group of disorders which principally affect the lung parenchyma. Encompassed under the “umbrella” term of DILD it is possible to subcategorise a number of groups: firstly, there are the DILDs which are secondary to known cause (for example lung disease secondary to exposure to certain drugs or as a consequence of collagen vascular diseases). Secondly, there is the large and interesting group of the idiopathic interstitial pneumonias. Thirdly, there are the granulomatous diseases which affect the lung parenchyma and finally a group of intriguing diffuse lung diseases that include Langerhans’ cell histiocytosis and lymphangioleiomyomatosis.

High resolution computed tomography (HRCT) is rightly considered an important test in the investigation of patients with suspected DILD. In certain cases (where biopsy would previously have been mandatory), the diagnostic process has been revolutionised by HRCT. In patients with the entity of usual interstitial pneumonia, for example, the HRCT appearances are characteristic enough for an accurate radiological diagnosis to be made and render biopsy unnecessary.

The idiopathic interstitial pneumonias (IIP) are perhaps the most interesting and important group of diffuse interstitial lung diseases. The IIPs, which have recently been reclassified by an American and European consensus committee, include usual interstitial pneumonia (UIP), non-specific interstitial pneumonia (NSIP), desquamative interstitial pneumonia (DIP), respiratory bronchiolitis-associated interstitial pneumonia (RB-ILD), acute interstitial pneumonia (AIP), lymphocytic interstitial pneumonia (LIP), and cryptogenic organising pneumonia. Whilst this list appears somewhat daunting, in practise the important diagnostic distinction for the radiologist is between the UIP pattern and all others. In this regard, the cardinal HRCT features of the UIP pattern are a predominant subpleural and basal reticular pattern with honeycombing; although ground glass opacification is often present it is rarely the dominant pattern. When this pattern of changes is seen on HRCT, the radiologist is able to make a confident (and importantly, correct), diagnosis. Unfortunately and it is a sobering thought that the characteristic CT features of the UIP pattern may not be seen in around one third of patients.

The accompanying presentation will review the imaging features of the diffuse interstitial lung disease. Special attention will focus on the idiopathic interstitial pneumonias.



Chest Imaging Session

## MDCT in imaging thoracic diseases

*Prof. Clara G.C. Ooi*

Computed Tomography (CT) imaging of the thorax has progressed significantly since the 1980's when high resolution CT was deemed as a revolutionary technique in imaging lung parenchyma. When helical CT came to the fore, CT imaging was generally regarded as having reached its zenith. However with the advent of multidetector CT from 4-detector scanners to current commercially available 64-detector scanners, several new facets of thoracic imaging have therefore emerged. Optimized usage of tube power in these scanners together with high resolution along z axis have resulted in isometric imaging with larger volumes of body evaluated in shorter scan times providing an improved data base for 3D imaging.

This lecture will provide an overview of the clinical applications of MDCT in lung diseases with reference to evaluating focal and diffuse lung lesions, lung cancer staging and screening, pulmonary vascular imaging including pulmonary embolism and aortic disease, and its applications in airway diseases. Image processing with volume rendering, automated computer aided detection (CAD) systems, maximum intensity projections (MIP), and multiplanar reconstruction (MPR) in the evaluation process will also be discussed.