

MRI Hip

Ryan Lee

Prince of Wales Hospital

MRI hip

- A. Hip impingement
- B. Snapping hip
- C. Greater trochanteric pain syndrome
- D. Hip fracture
- E. Femoral head avascular necrosis

A. Hip impingement

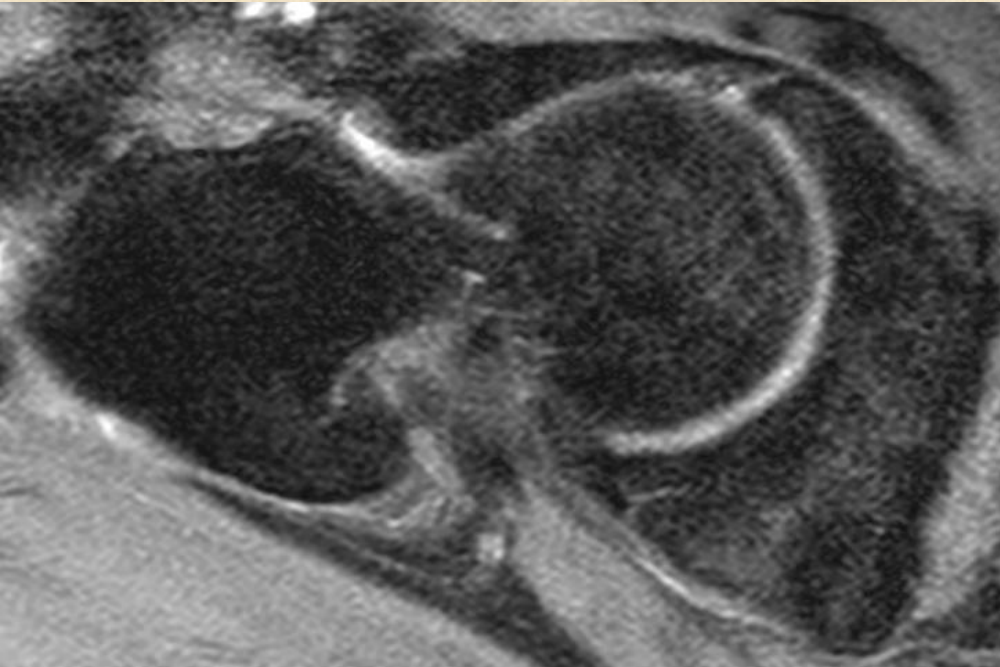
- Intra-articular
 - ✓ Femoroacetabular impingement
 - ✓ Iliopsoas impingement

- Extra-articular
 - ✓ Ischiofemoral impingement
 - ✓ Subspine impingement

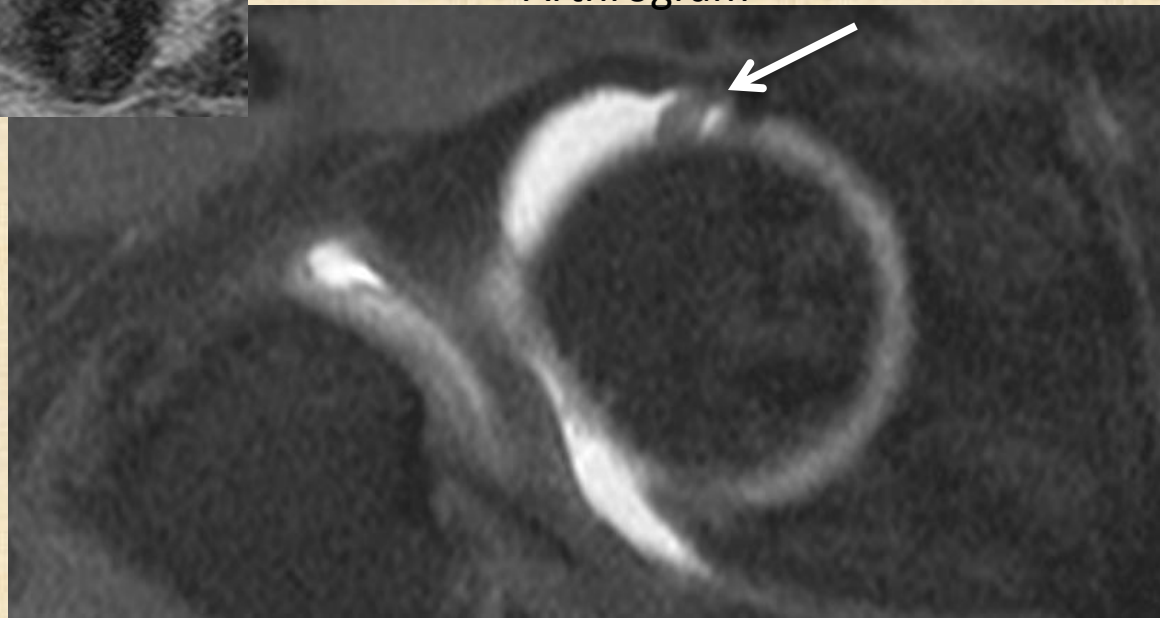
Femoroacetabular impingement (FAI)

- Not as common as the East
- Lead to premature OA
- CAM-type, Pincer-type and Mixed-type

Arthrogram or not arthrogram ?

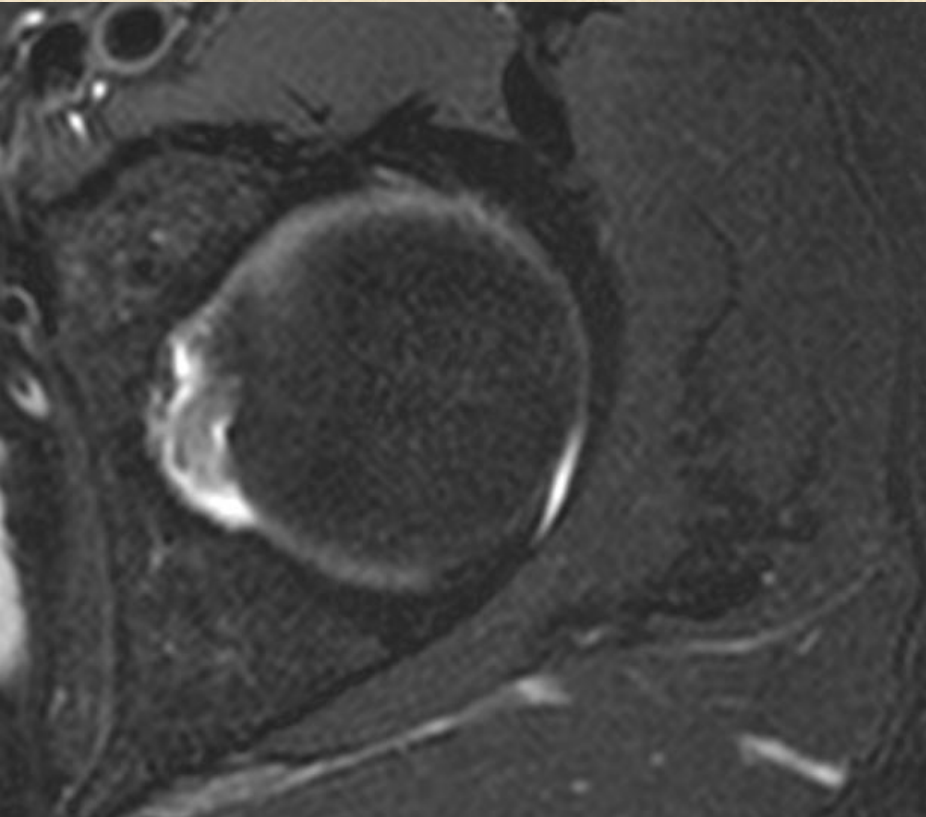


Non-arthrogram

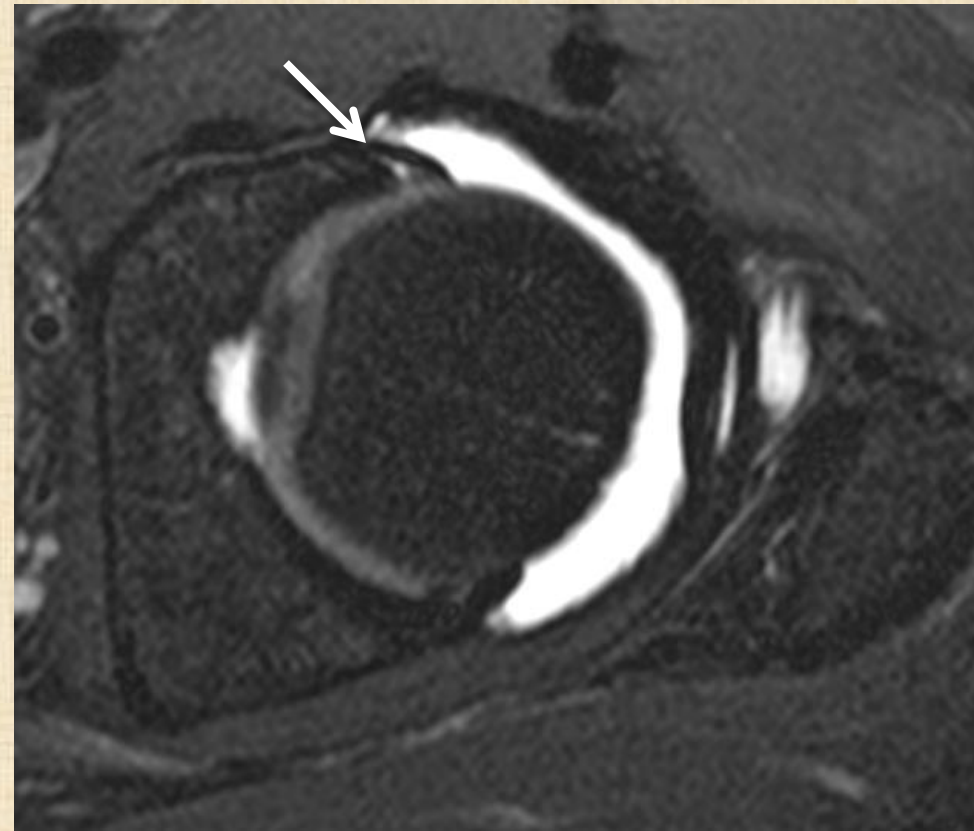


Arthrogram

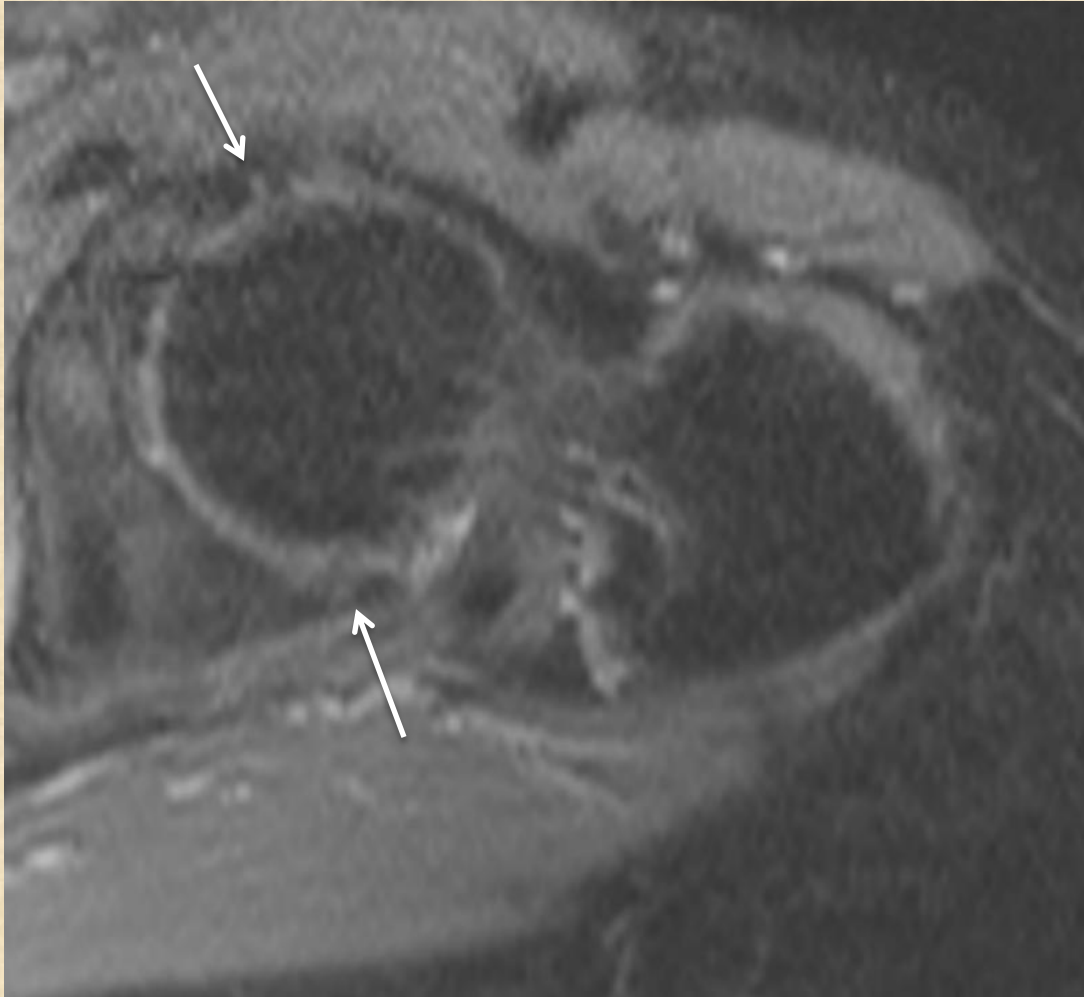
Arthrogram or not arthrogram ?



Non-arthrogram

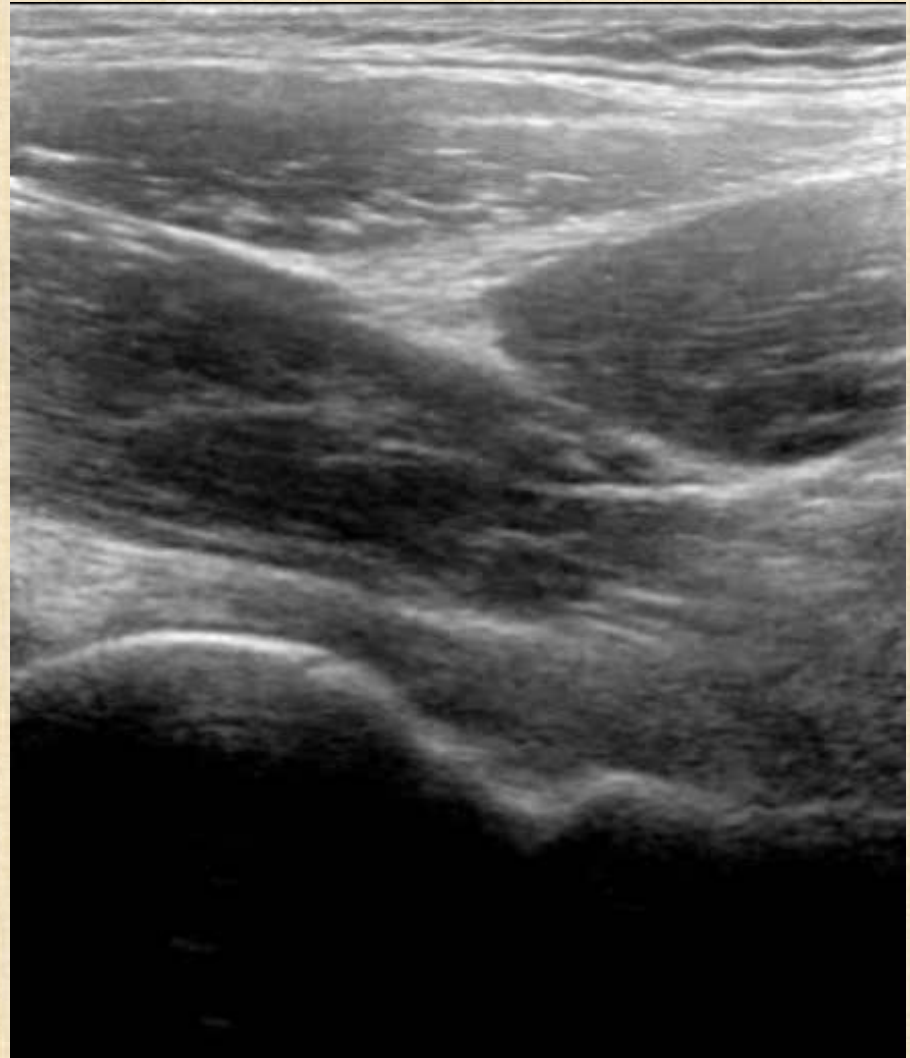
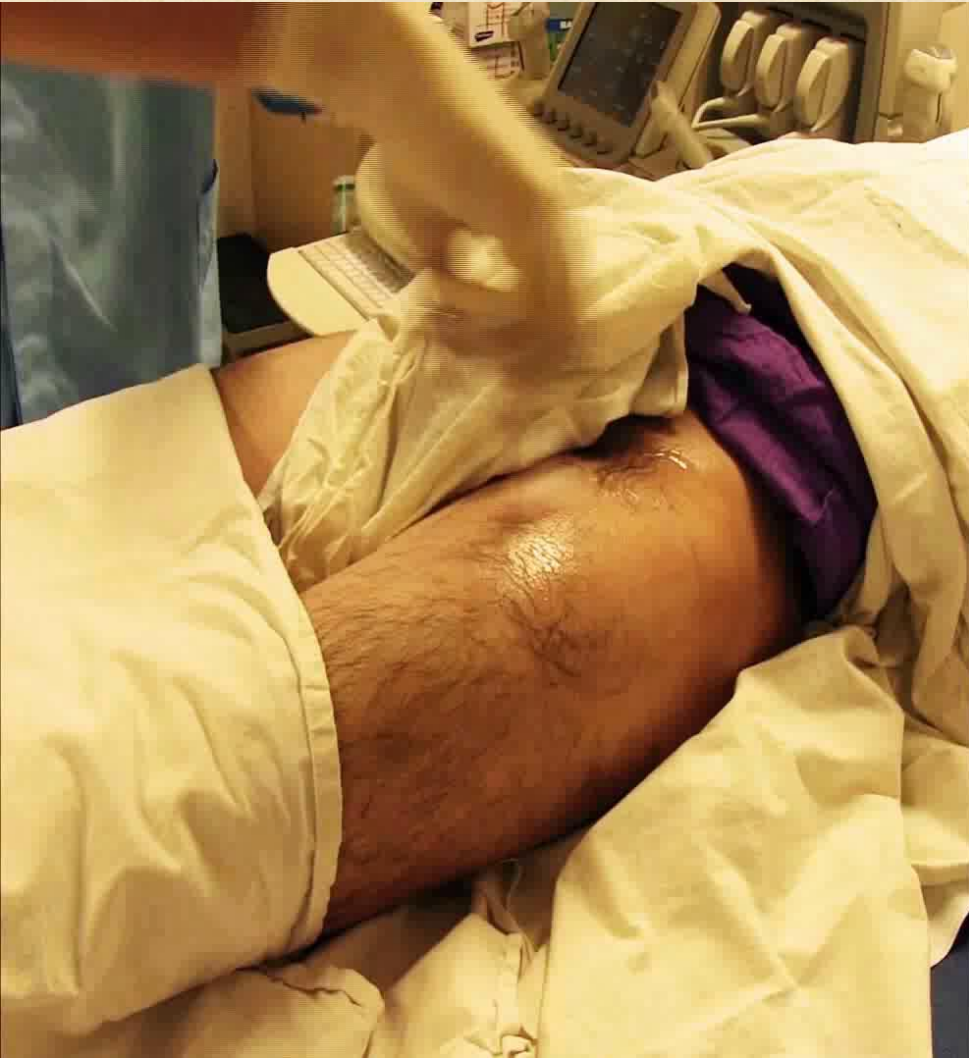
3T replace arthrogram ?

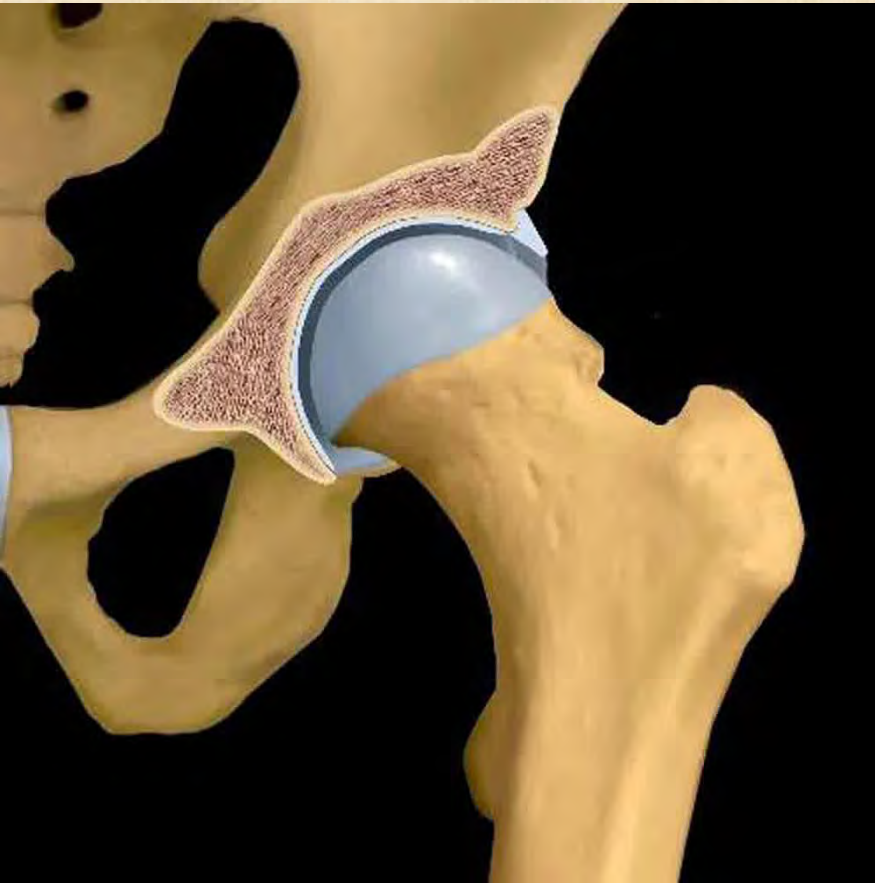


1.5T MRI

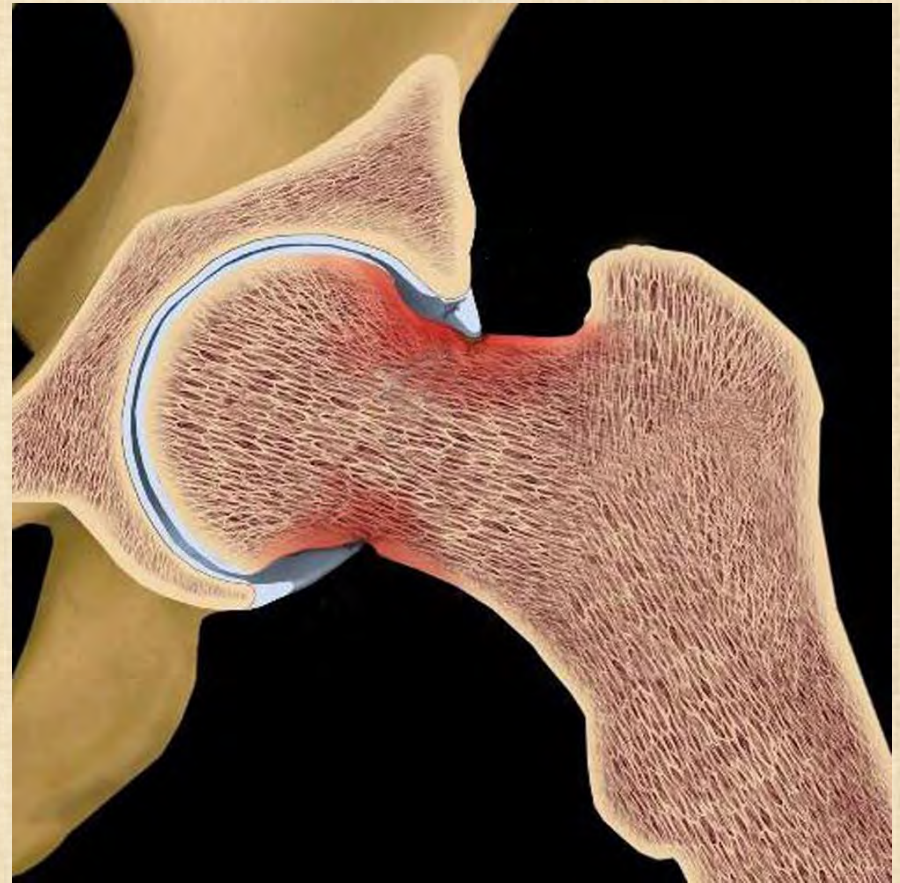USG guided hip arthrogram



FAI

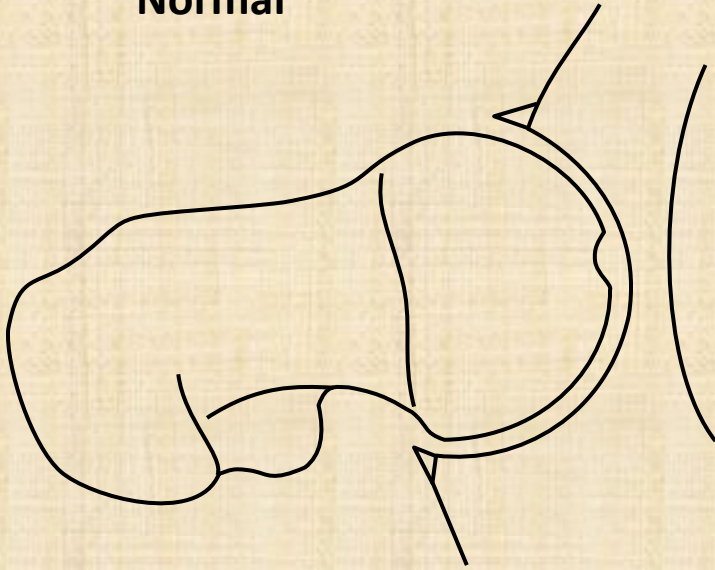


CAM

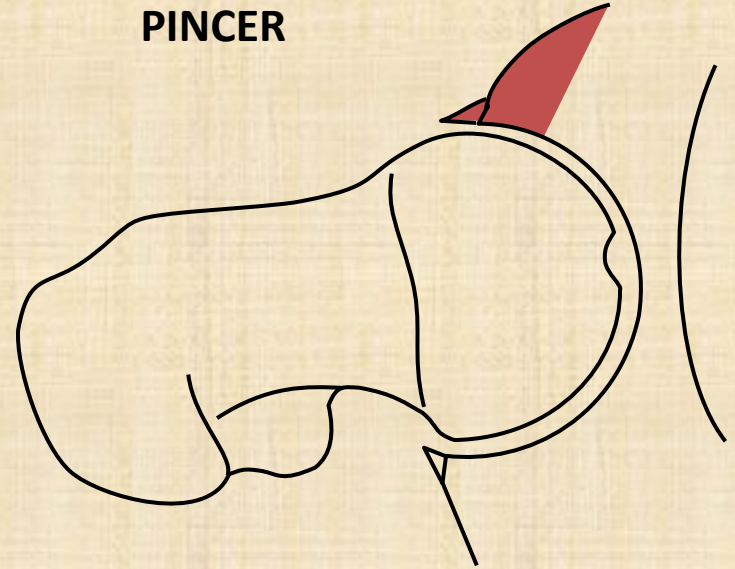


PINCER

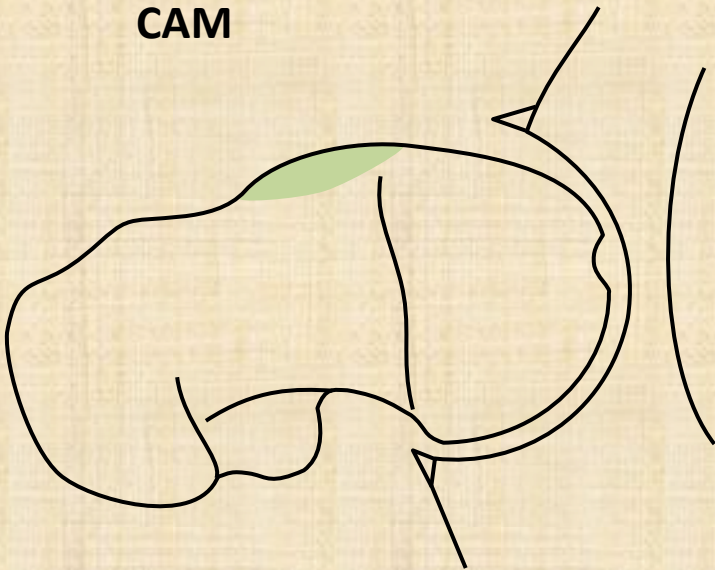
Normal



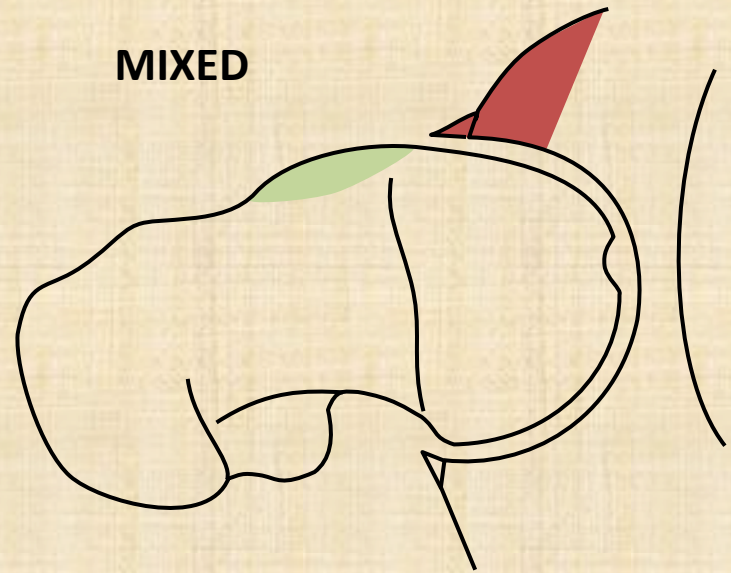
PINCER




CAM



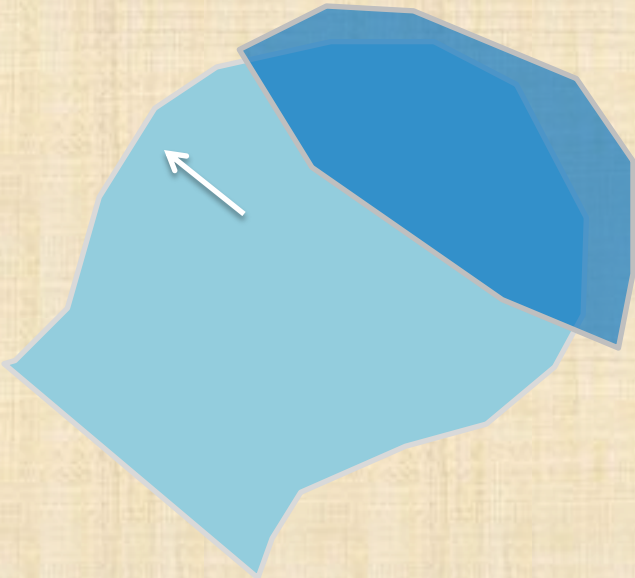
MIXED




Normal



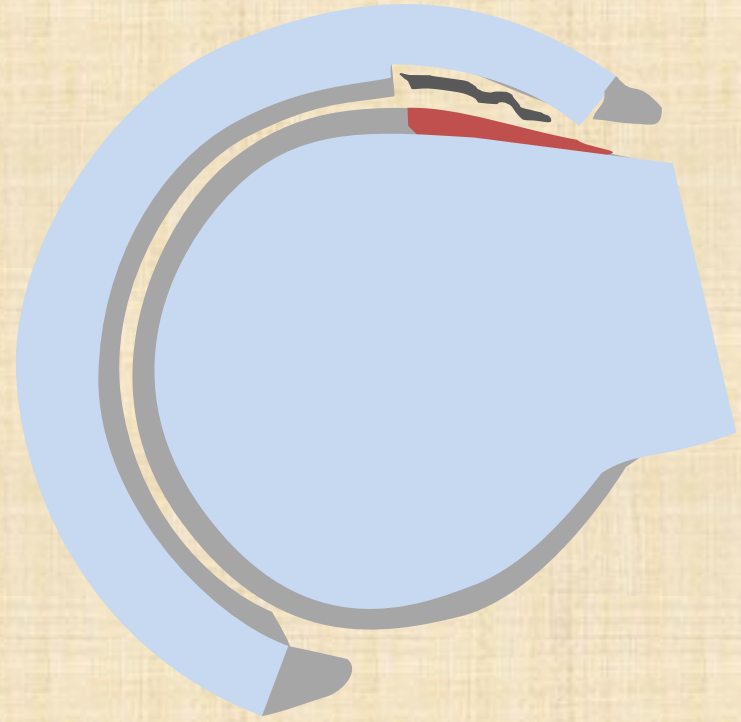
CAM



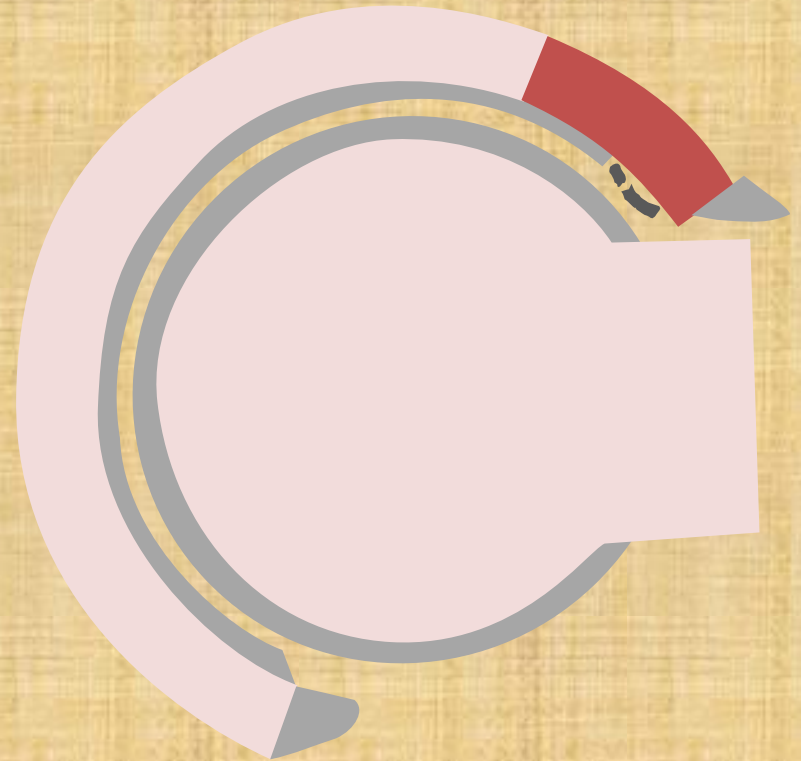

PINCER

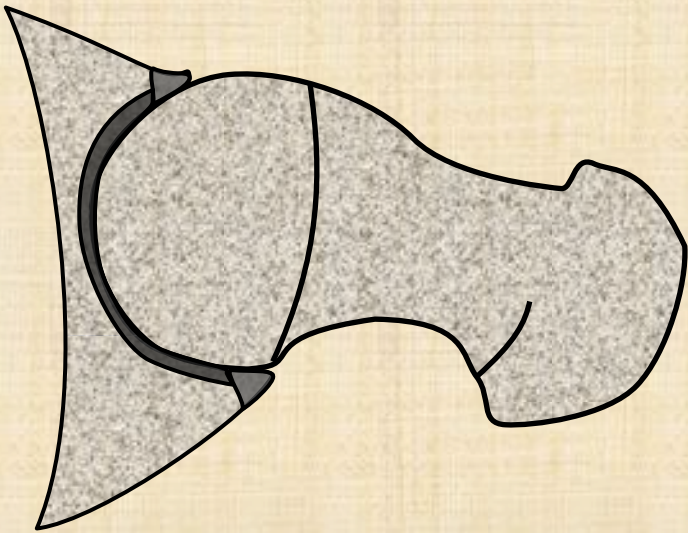


CAM type

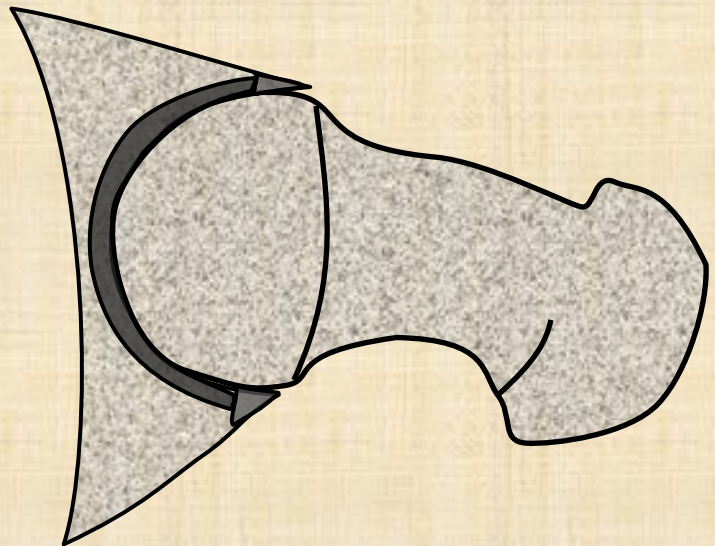


PINCER type

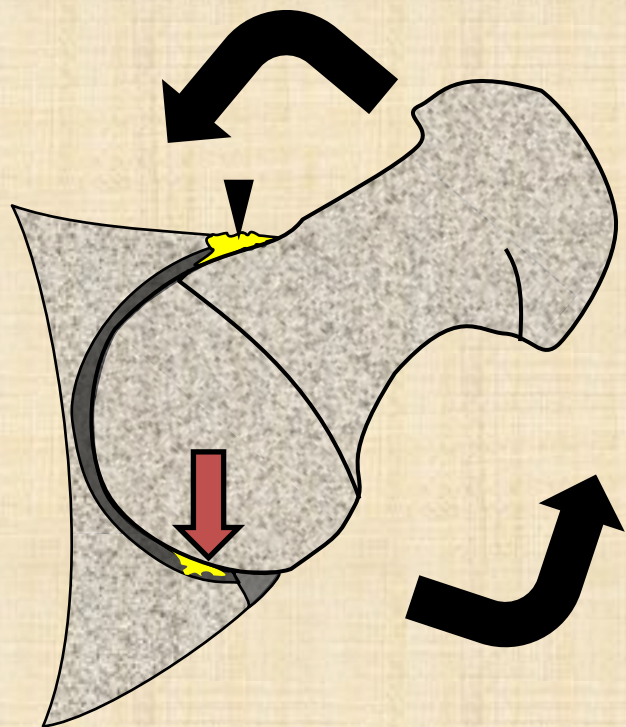
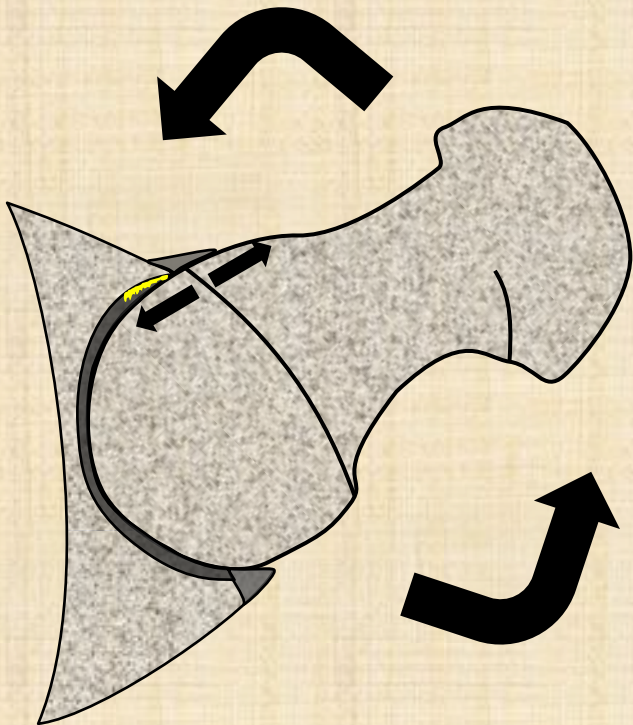




CAM



PINCER



CAM vs Pincer

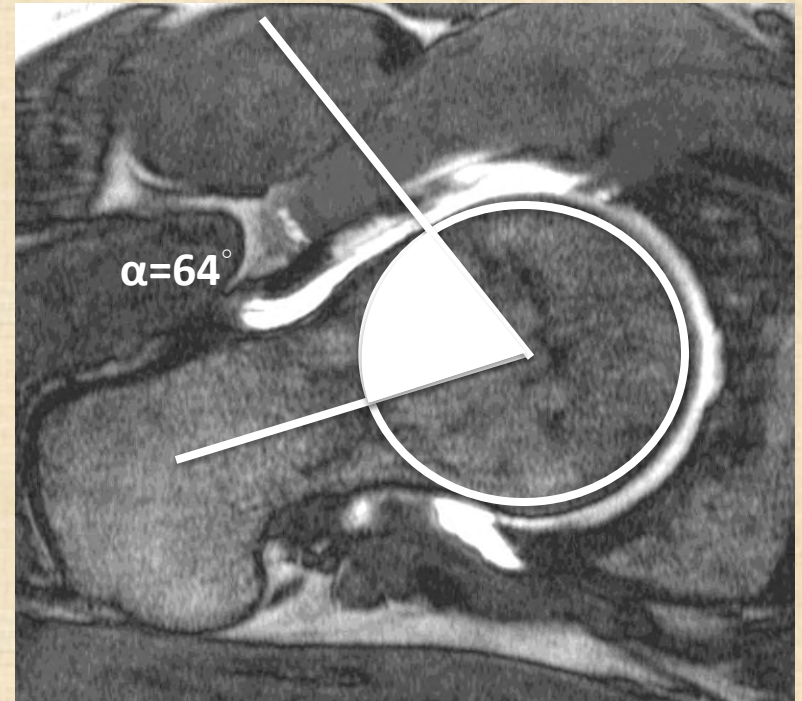
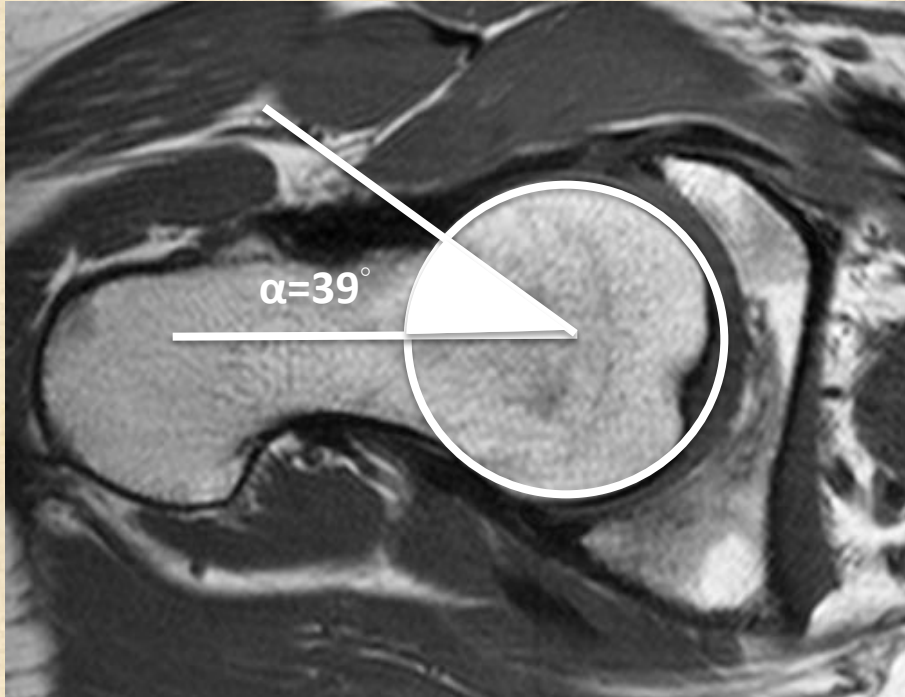
	CAM	Pincer
	Young male 3 rd decade	Female 4 th decade
	Femoral problem	Acetabular problem
Labrum tear	Anterior Anterosuperior	Anterosuperior (mainly)
Osseous abnormalities	Osseous bump at head-neck junction (A. alpha angle ; B. pistol grip deformity)	1) Retroversion - anterior 2) Acetabular protrusion (overcoverage) - global
Chondral delamination	More focal, larger (mainly)	More diffuse, longer, smaller, thinner
Chondral defect location	Anterosuperior	Anterosuperior Posteroinferior (contrecoup)

FAI MRI report

- Osseous abnormalities (femur and acetabulum)
- Labrum (fraying, degeneration, tear)
- Cartilage (delamination)
- Associated findings (herniation pit + os acetabuli)

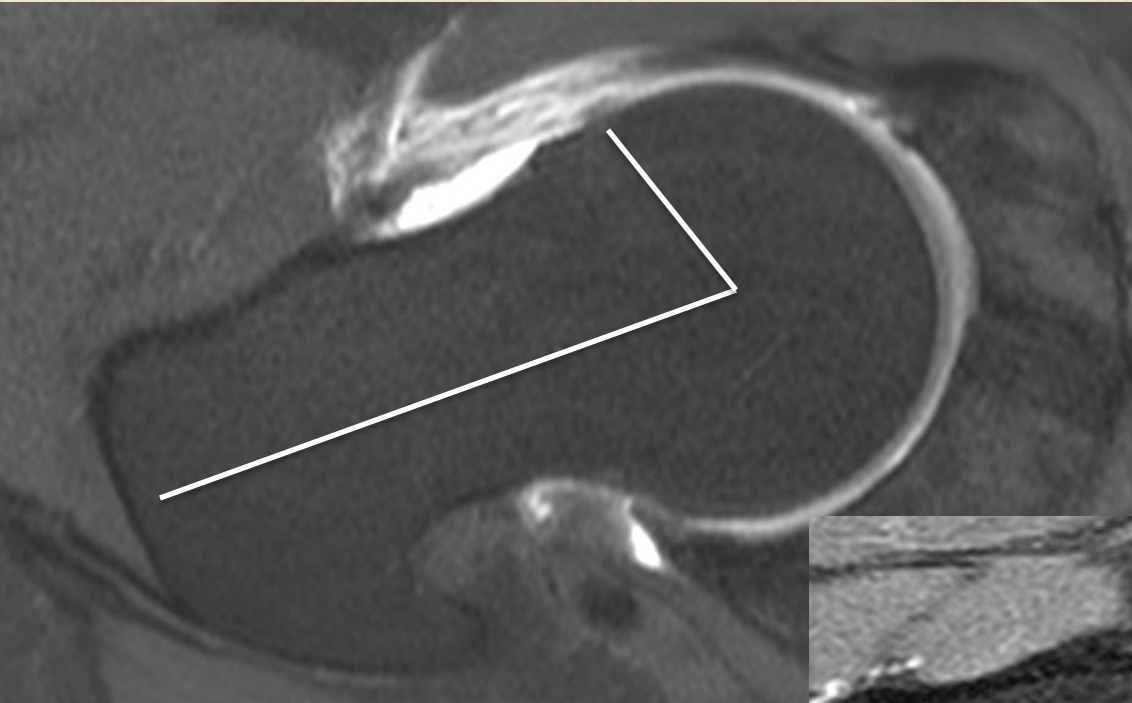
- Ligamentum teres
- Joint capsule

CAM type FAI

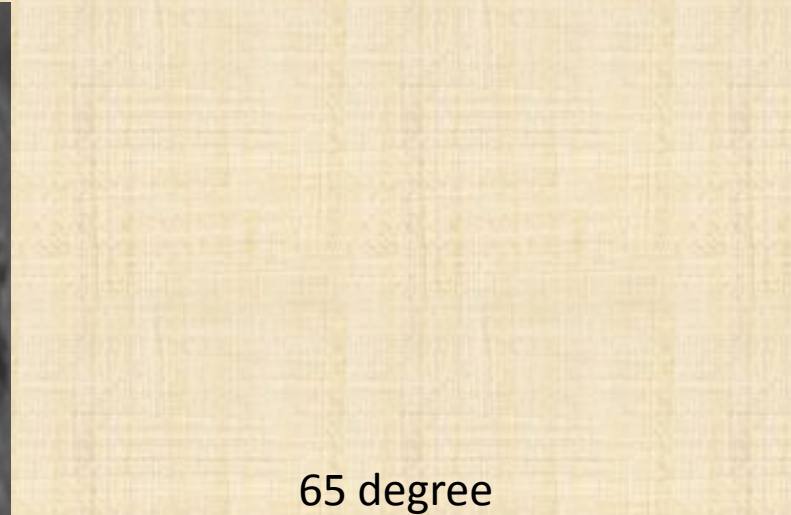

Normal alpha angle $< 60^\circ$

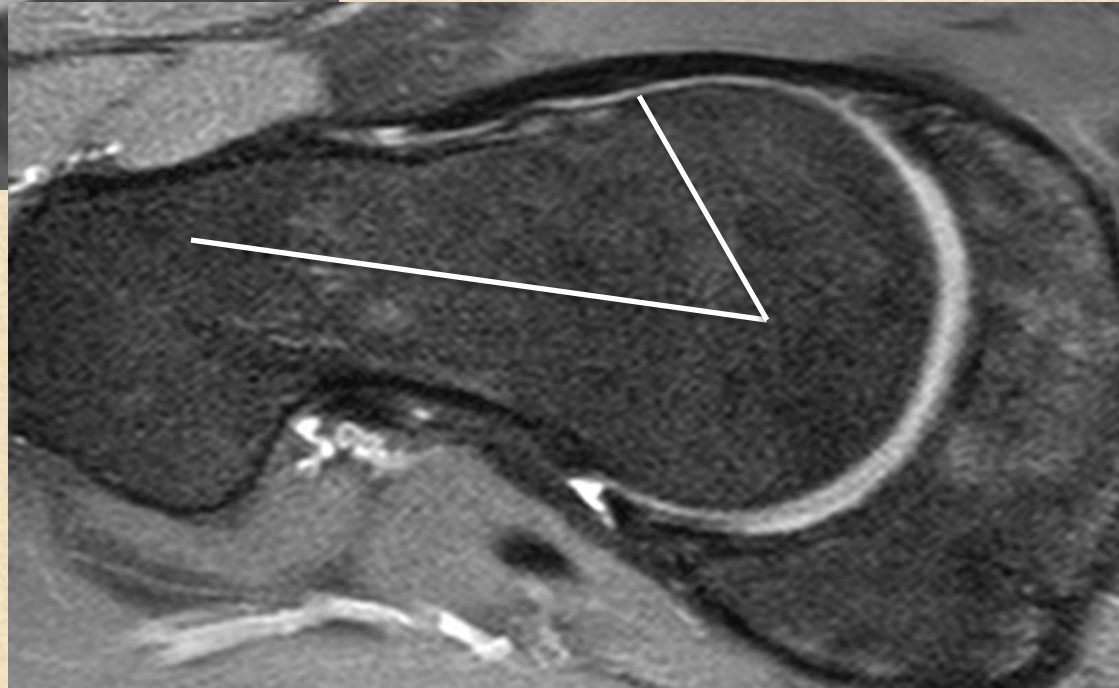
A. Alpha angle



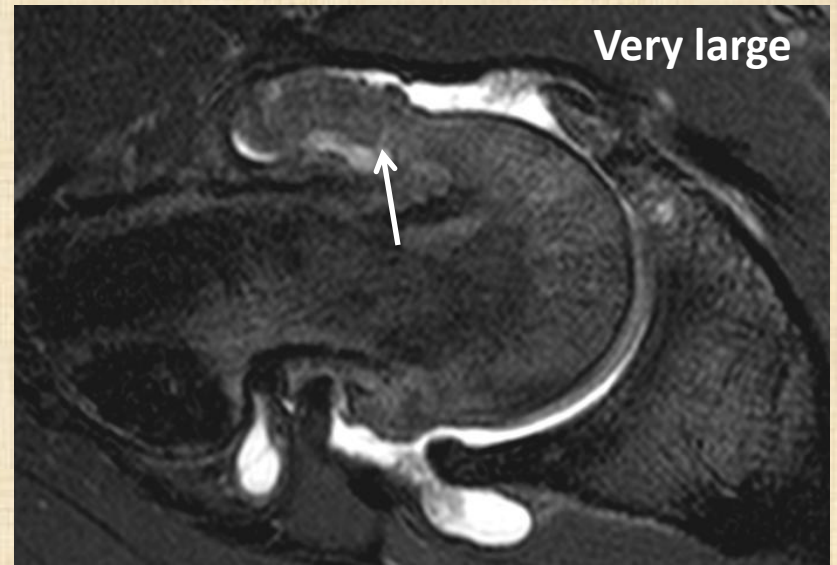
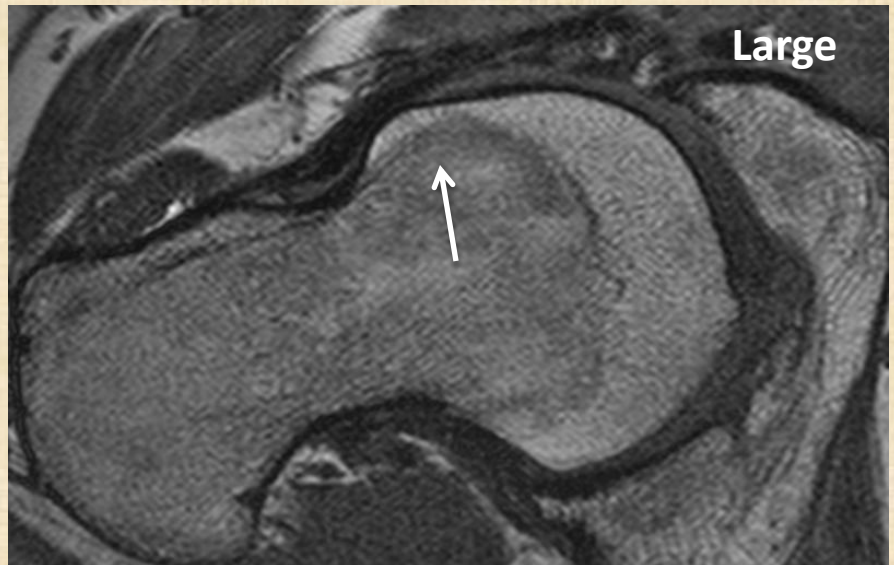
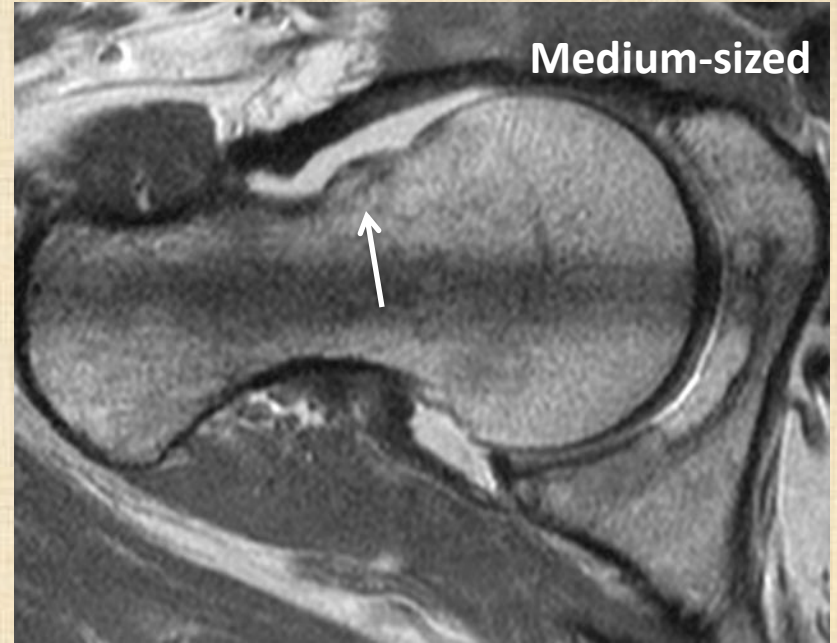
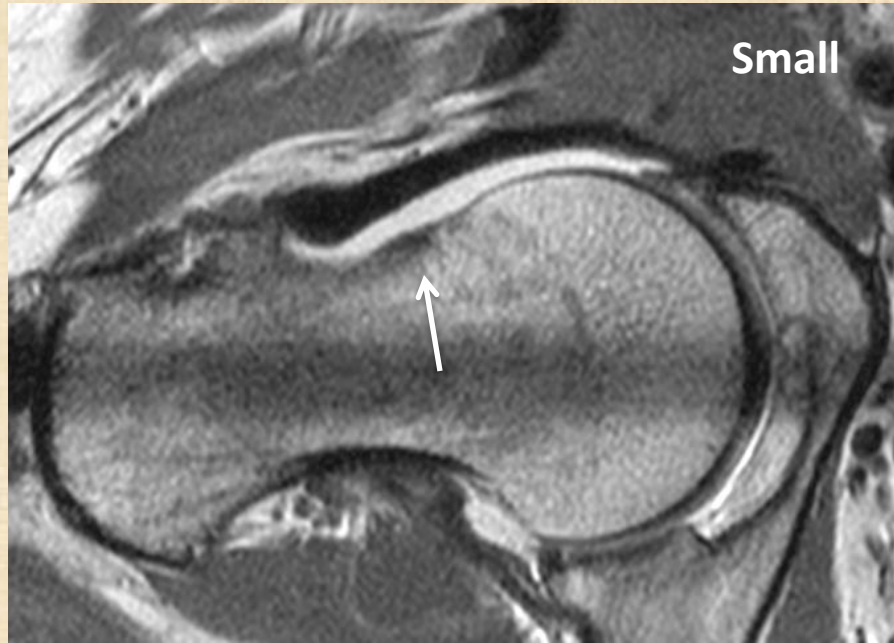70 degree



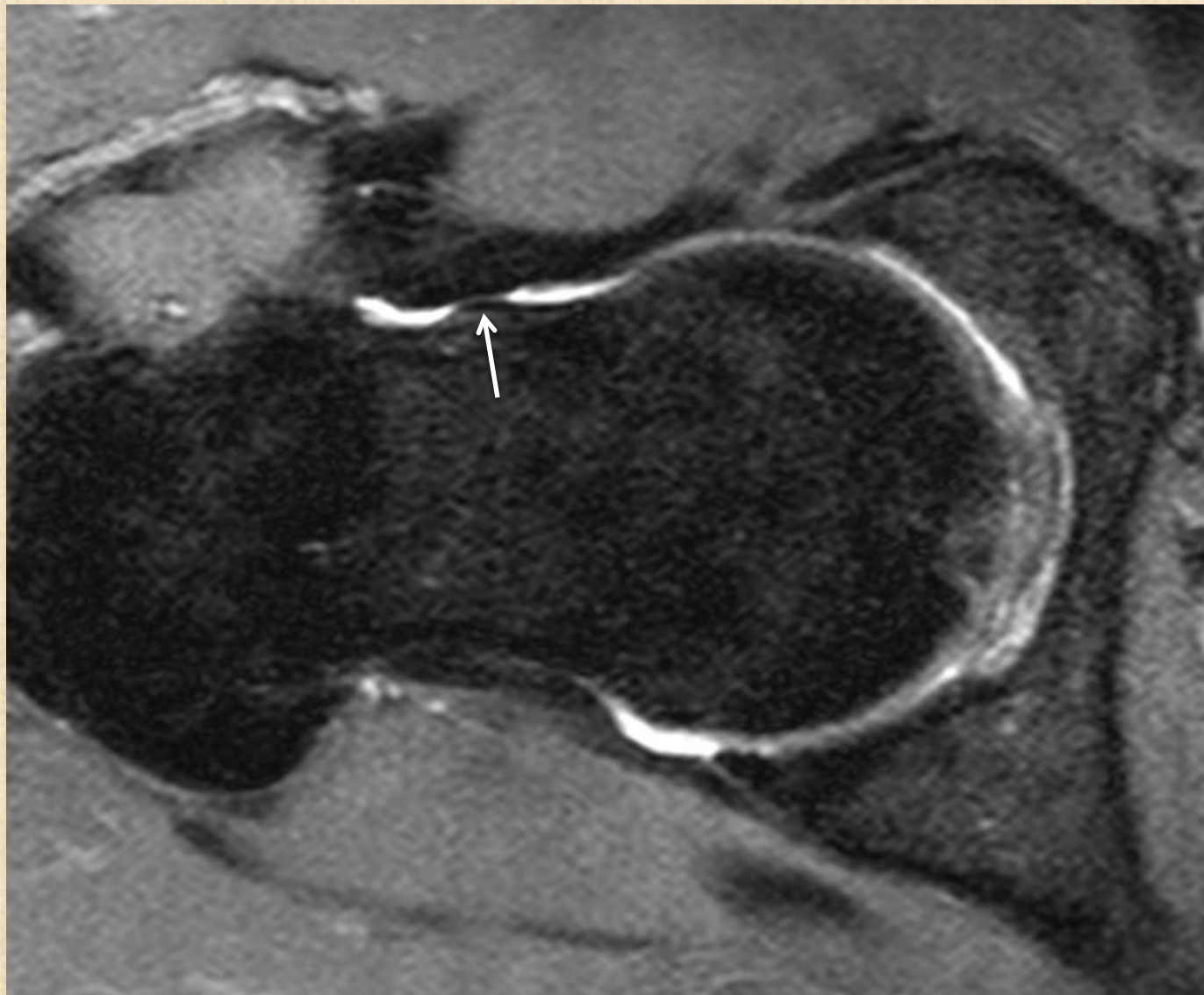
65 degree



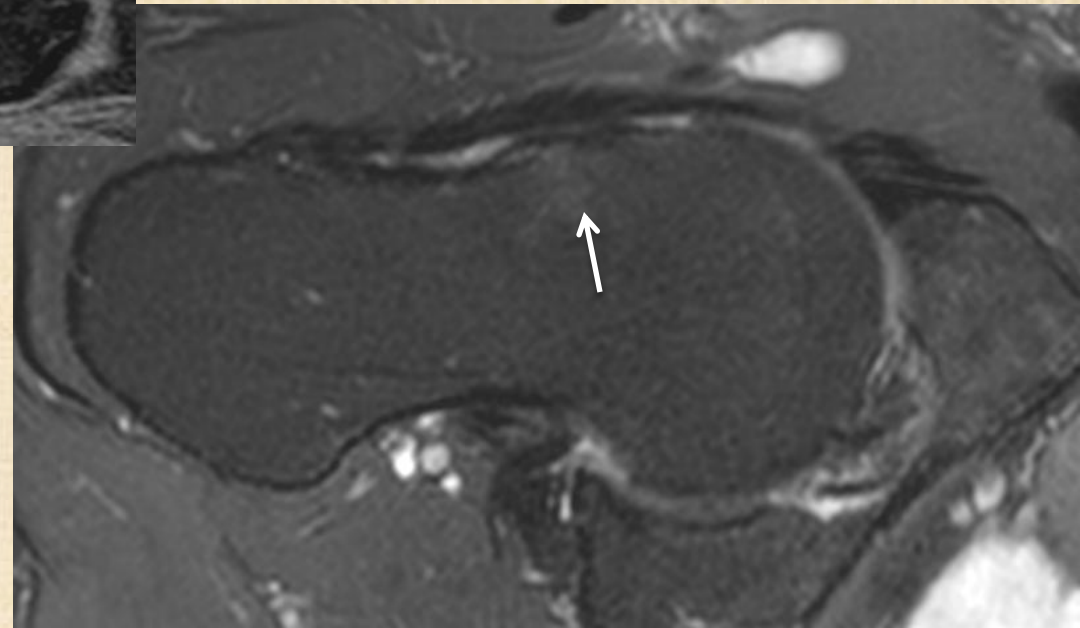
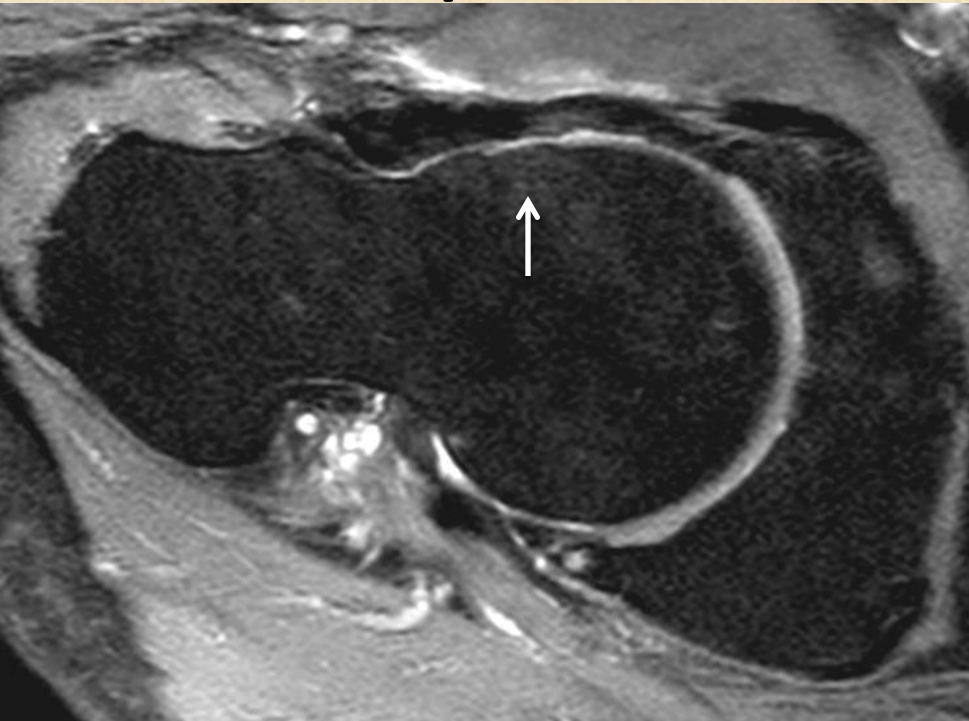
Osseous bump head neck junction



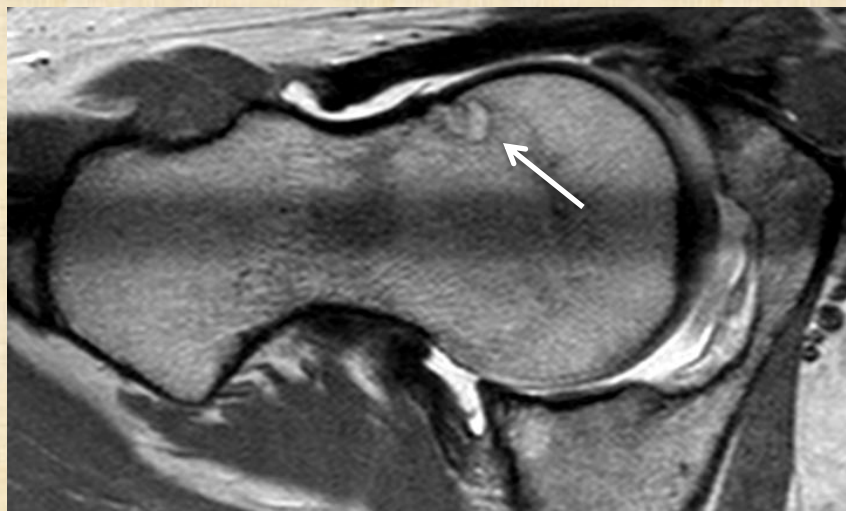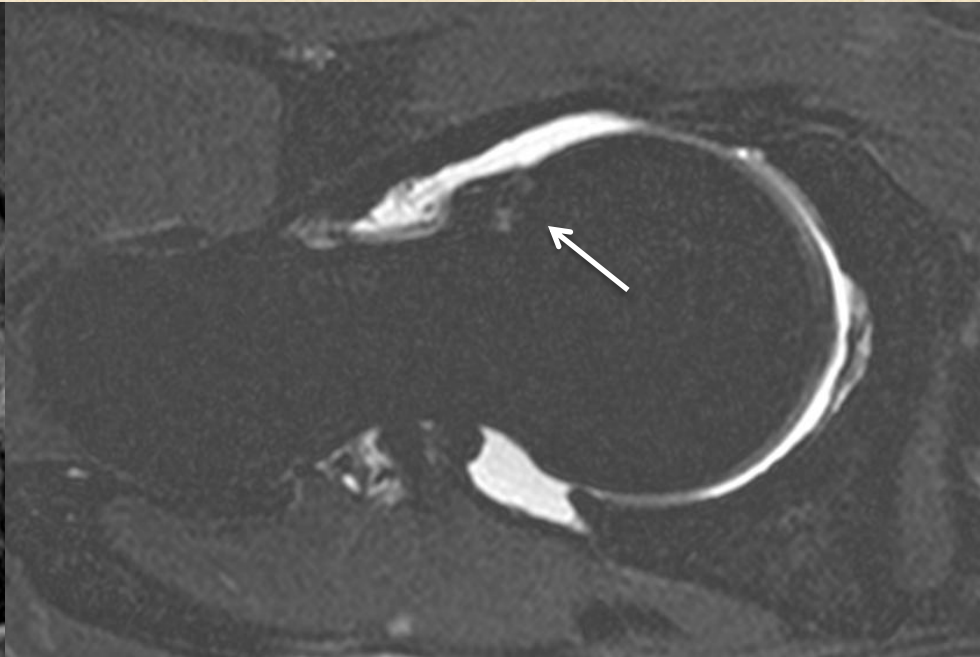
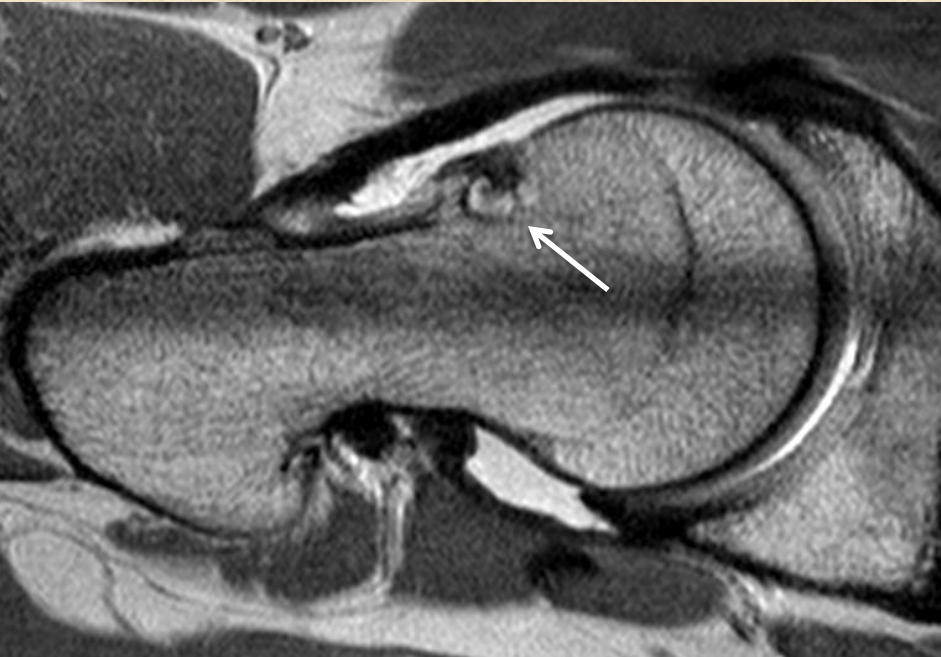Pseudo osseous bump



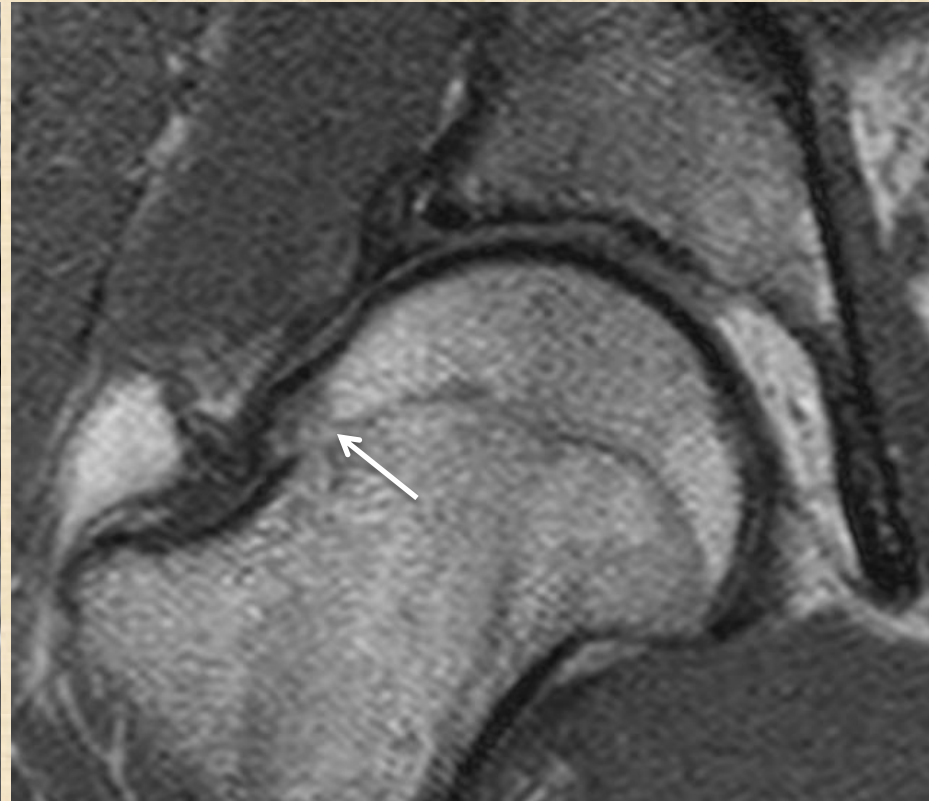
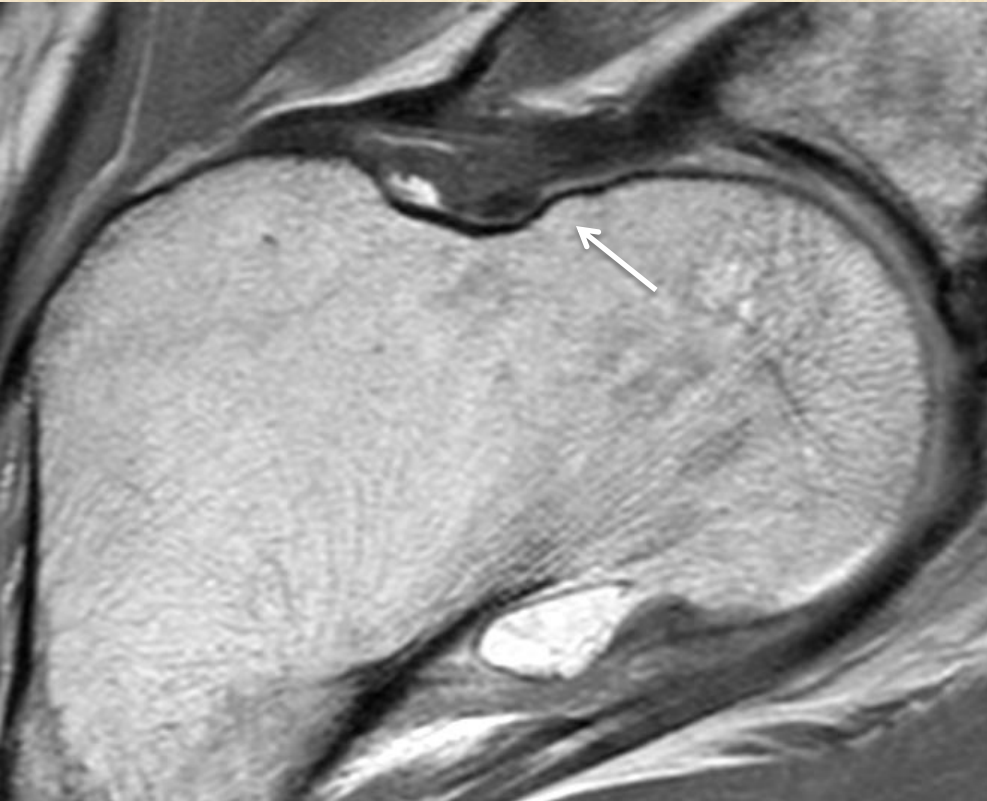
Bump with subchondral edema



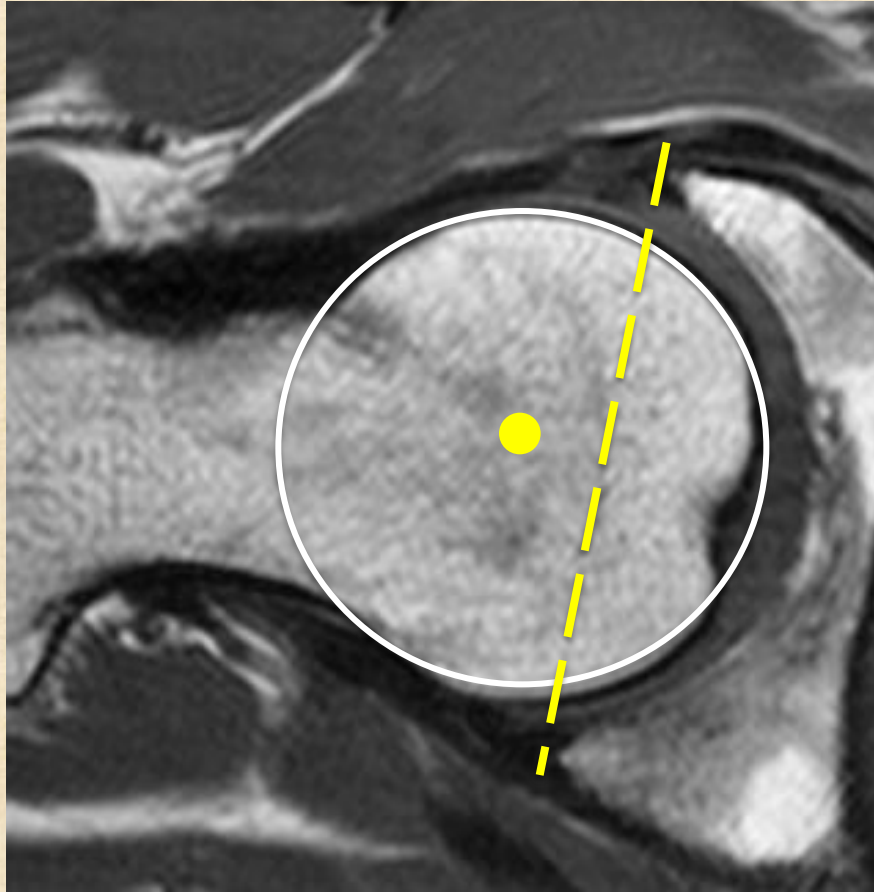
Bump with cystic change



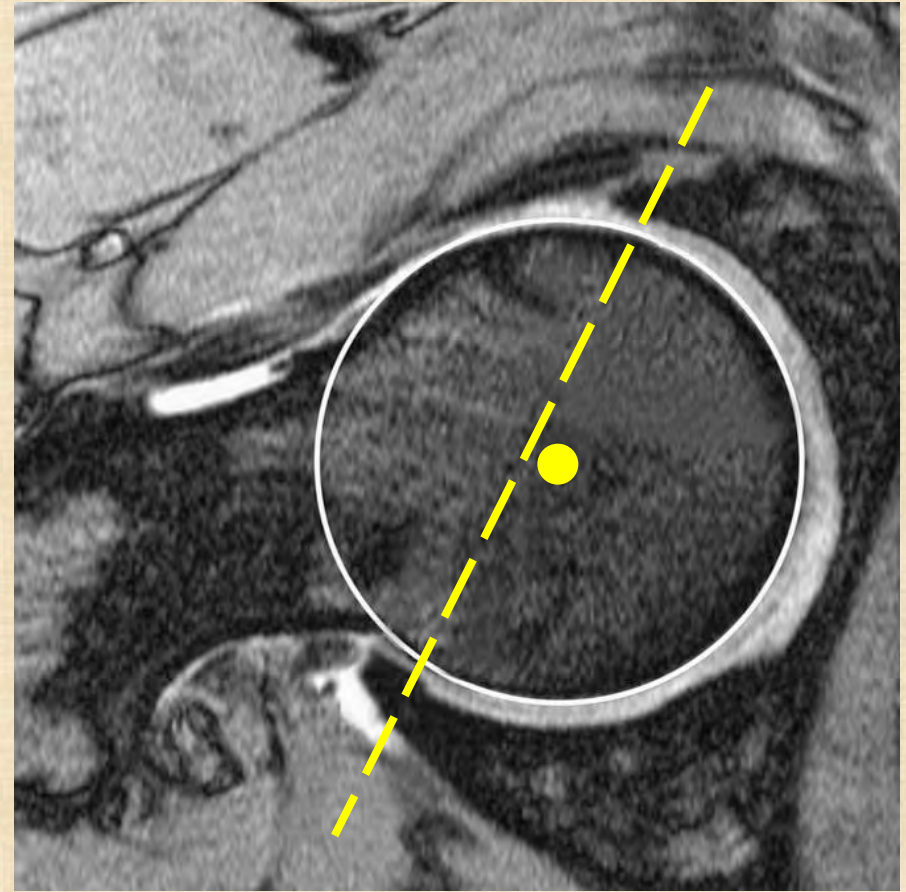
B. Pistol grip



PINCER type : Acetabular overcoverage

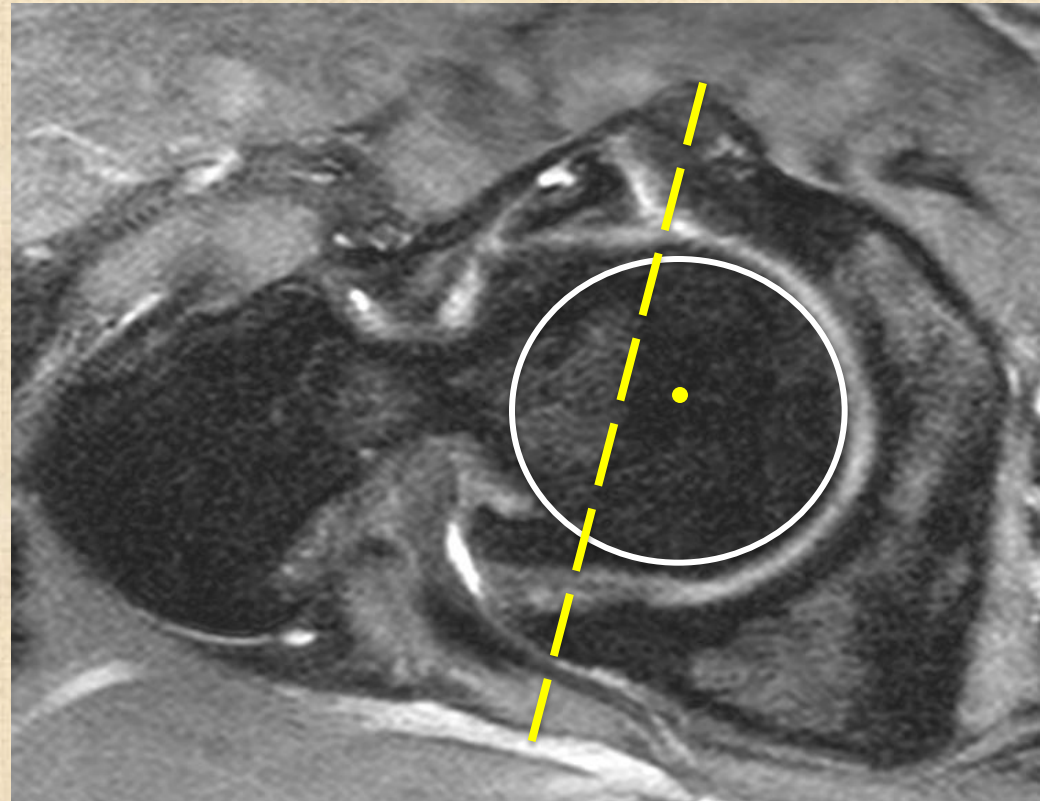
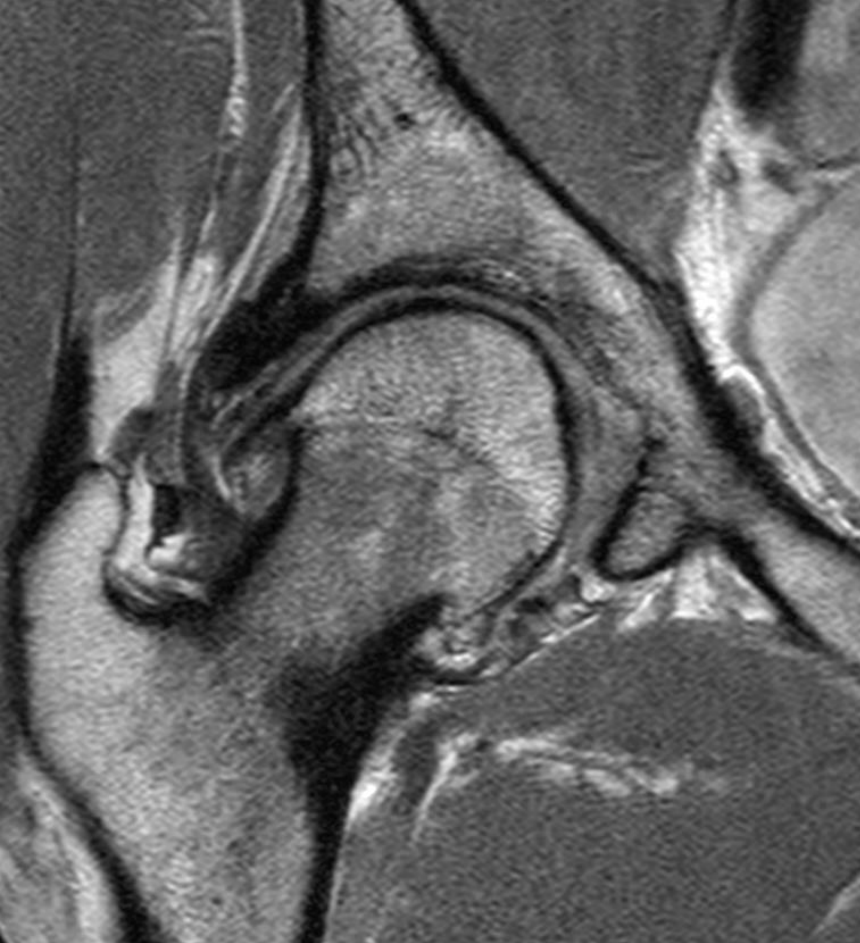


Normal

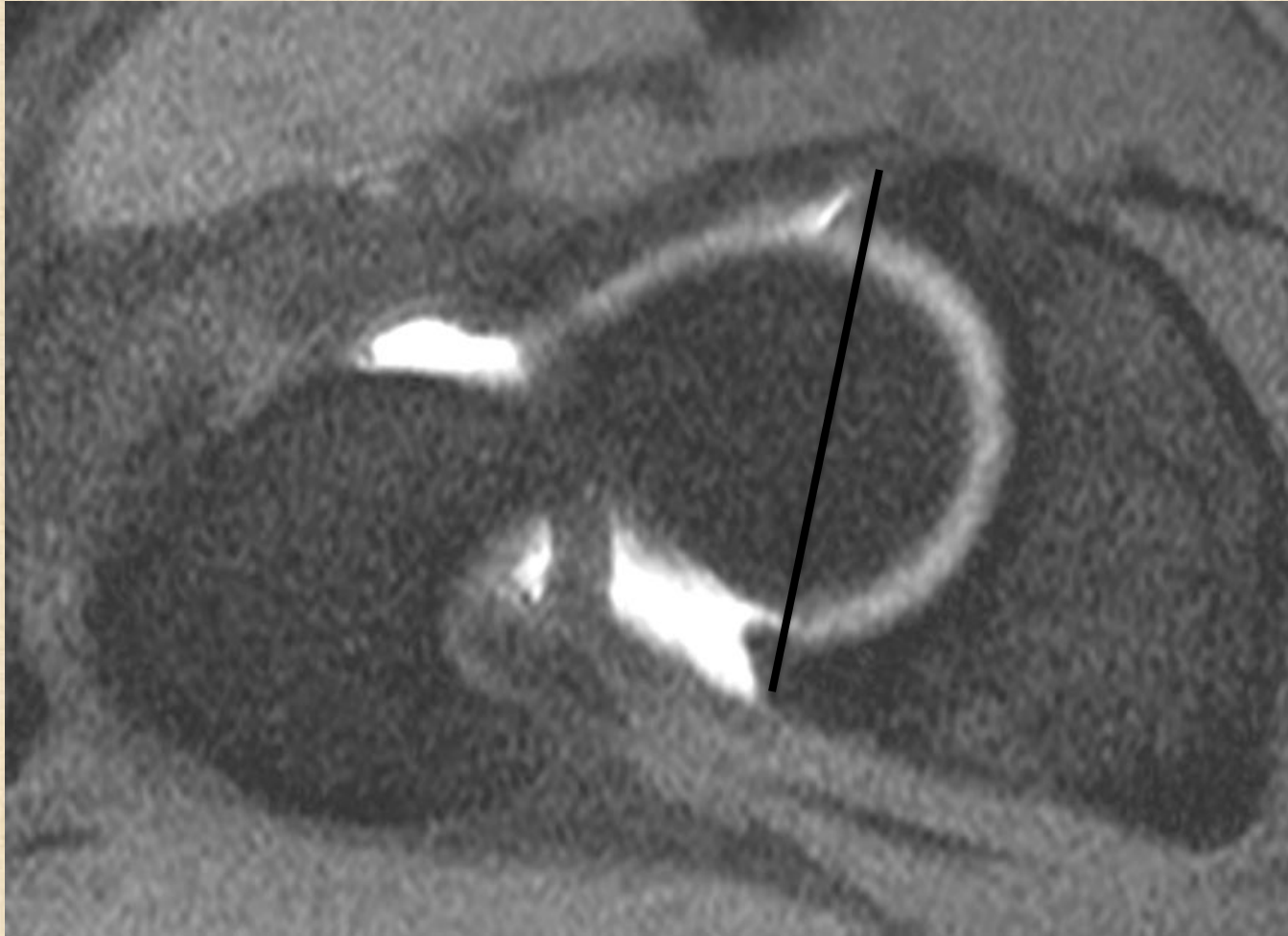


Protrusio

PINCER TYPE : acetabular overcoverage

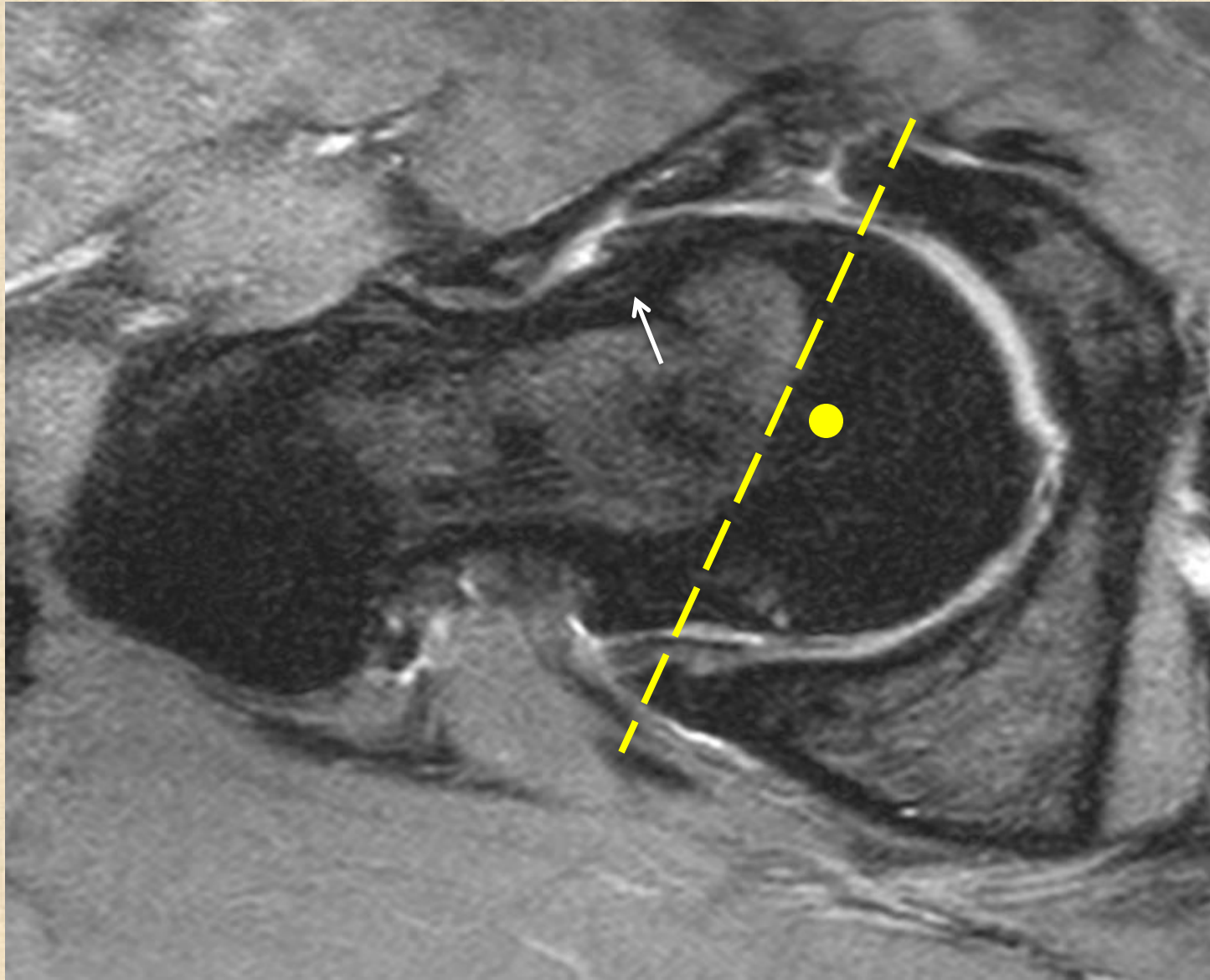


PINCER type - Retroversion

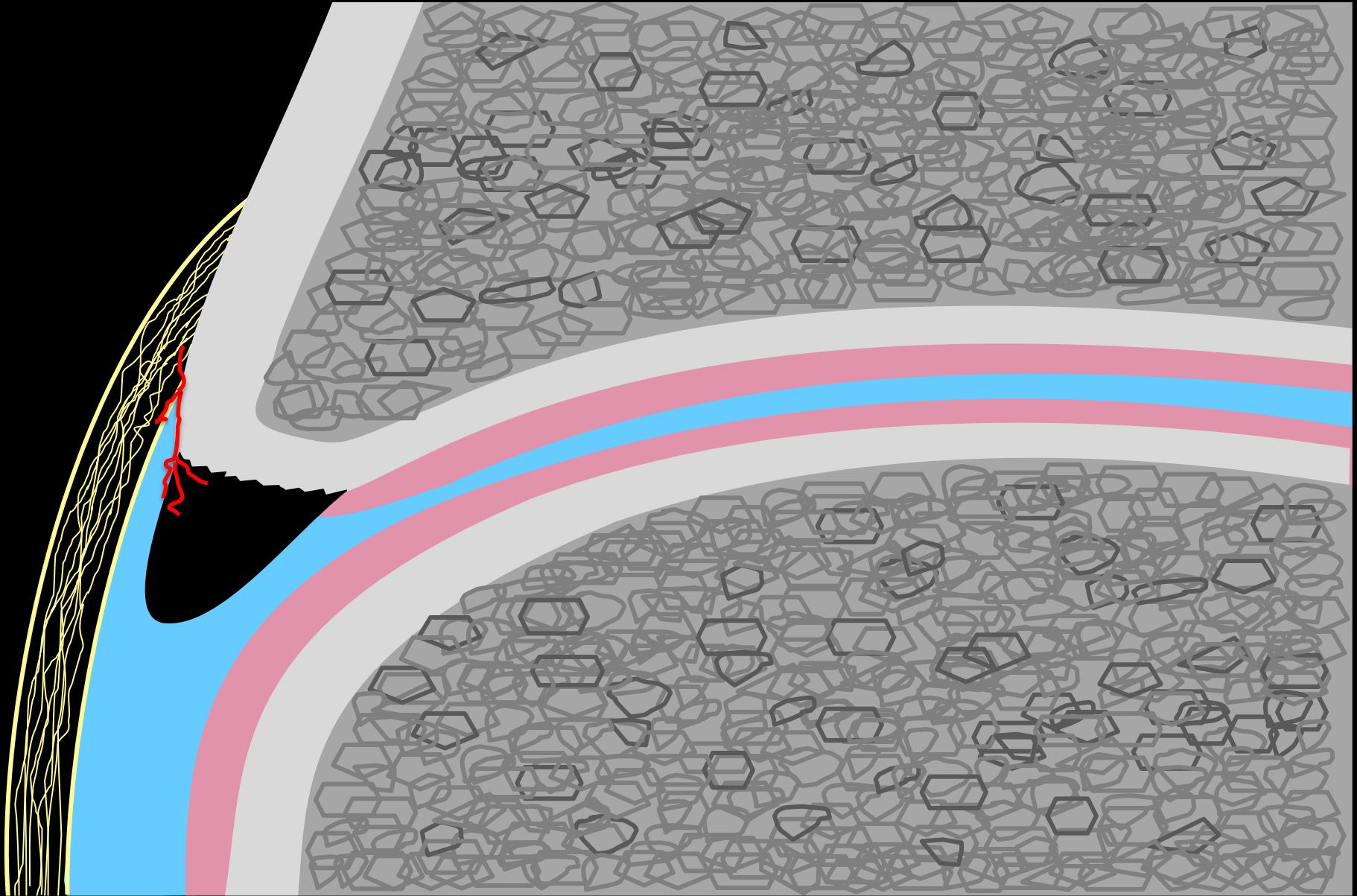


Anterersion : normal

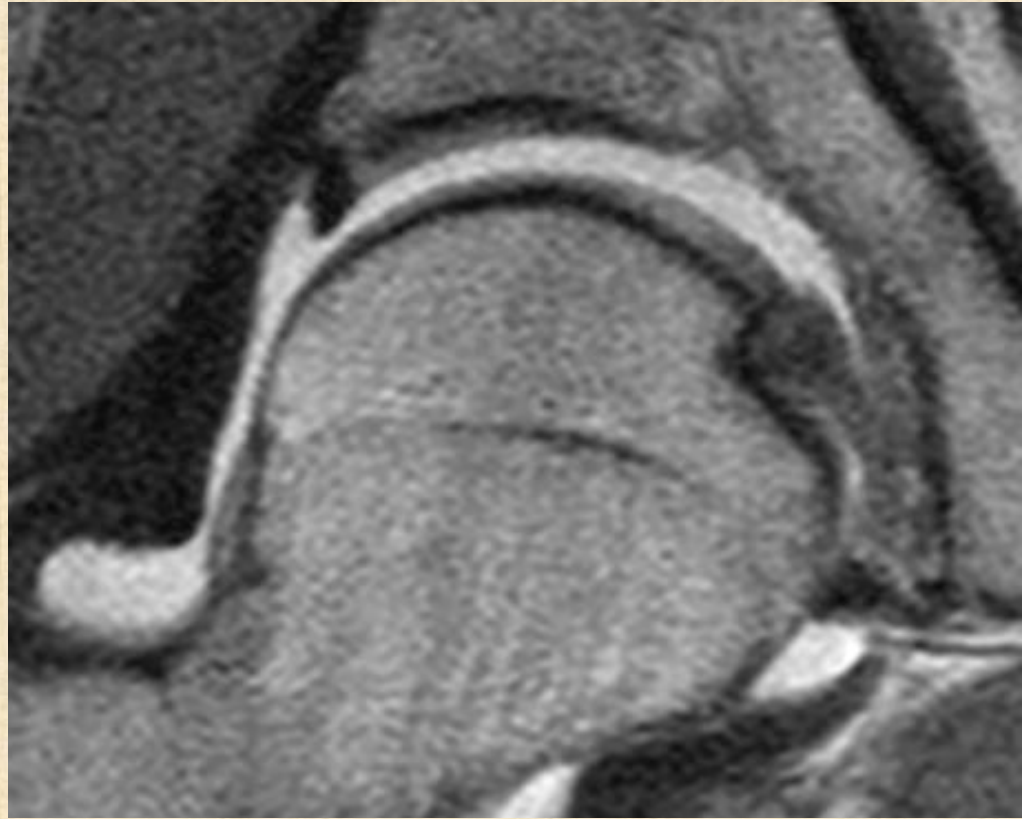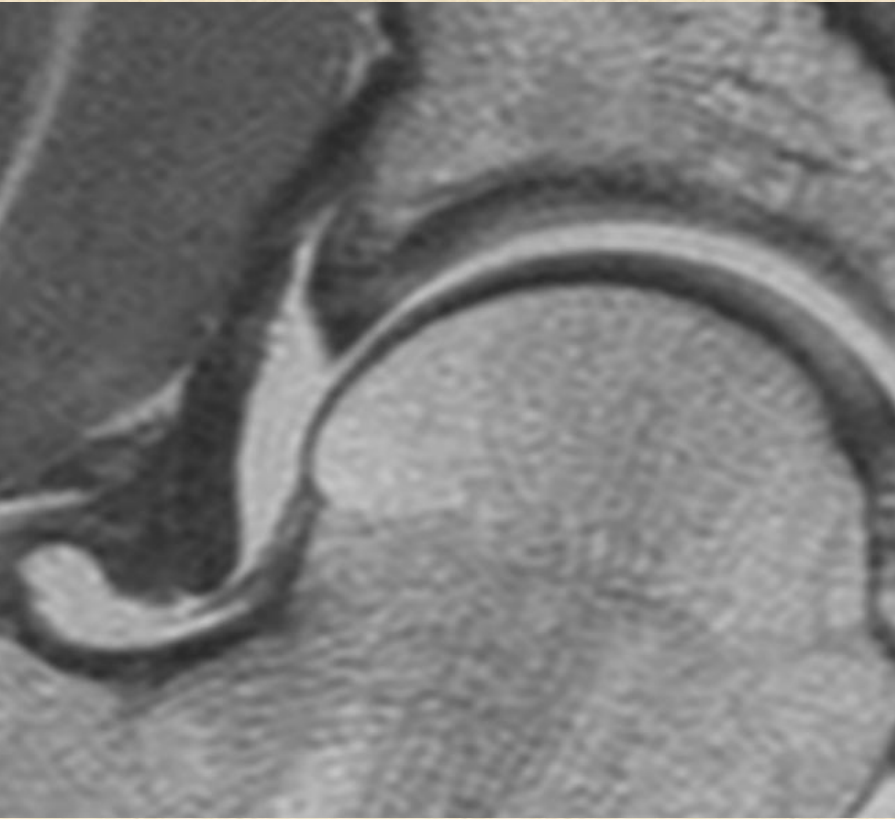
Mixed type (CAM + PINCER)

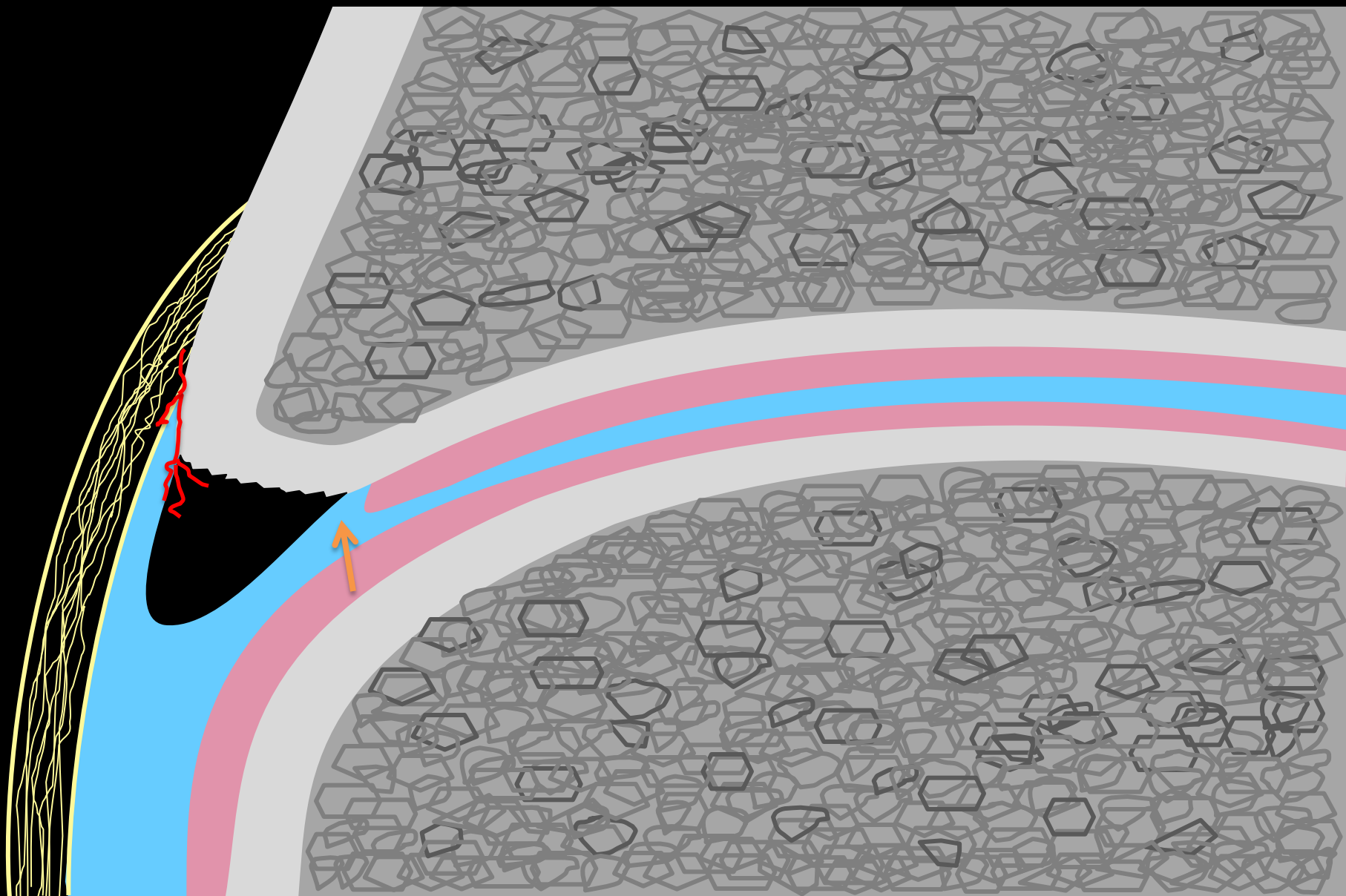


Normal labrochondral junction

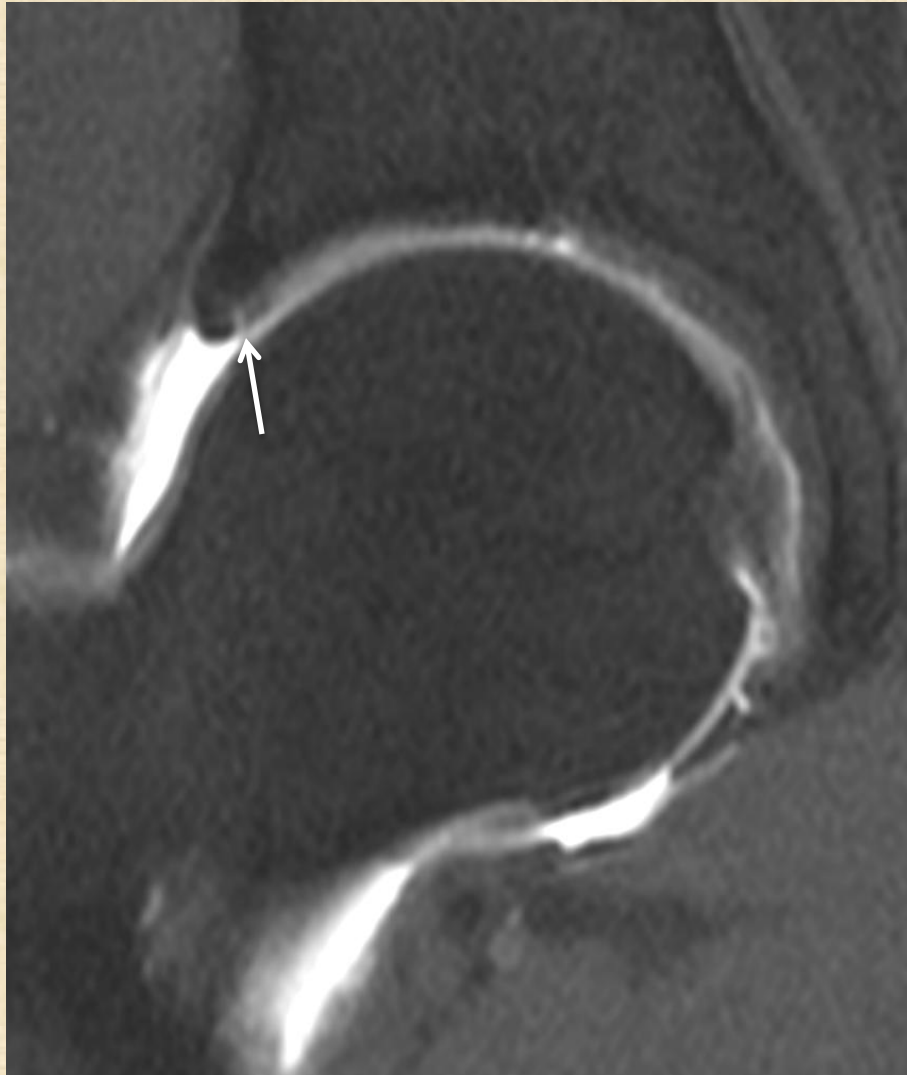


Normal labrochondral junction

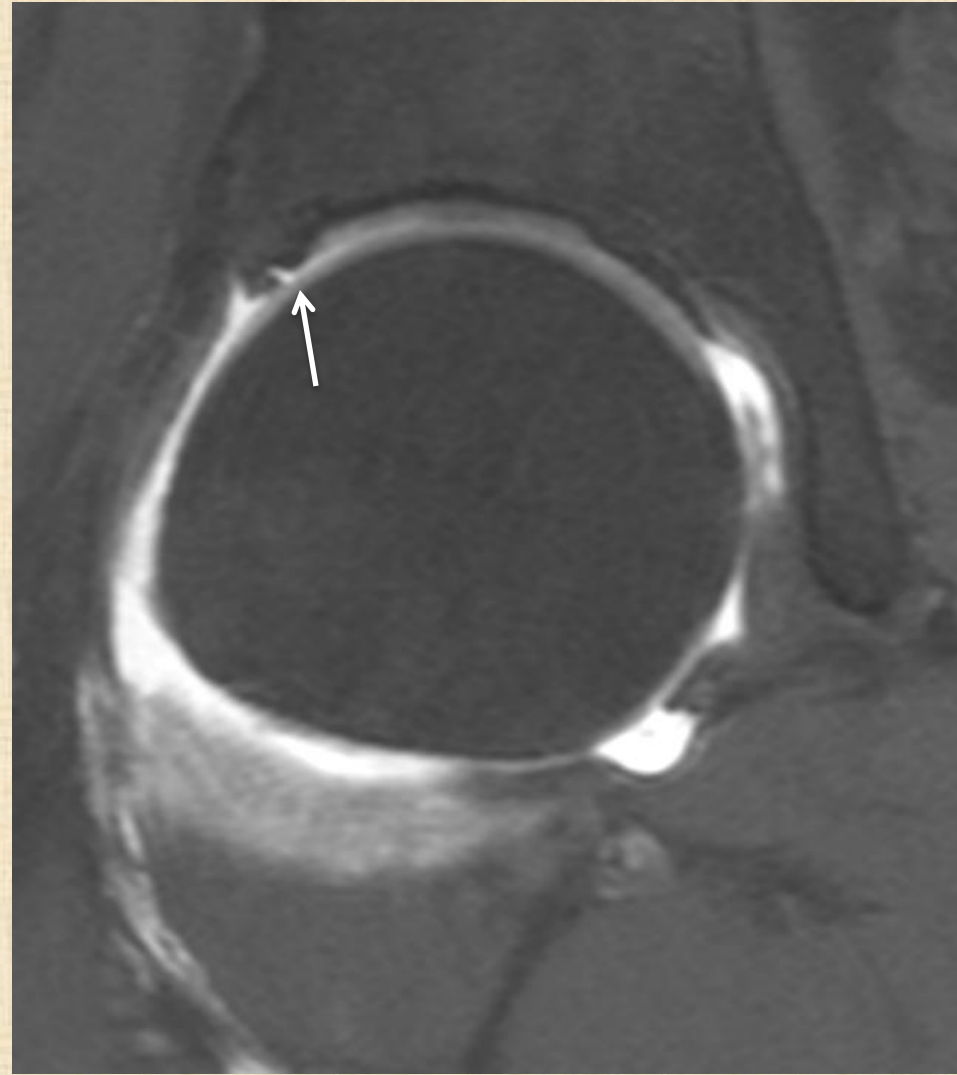




Chondrolabral separation



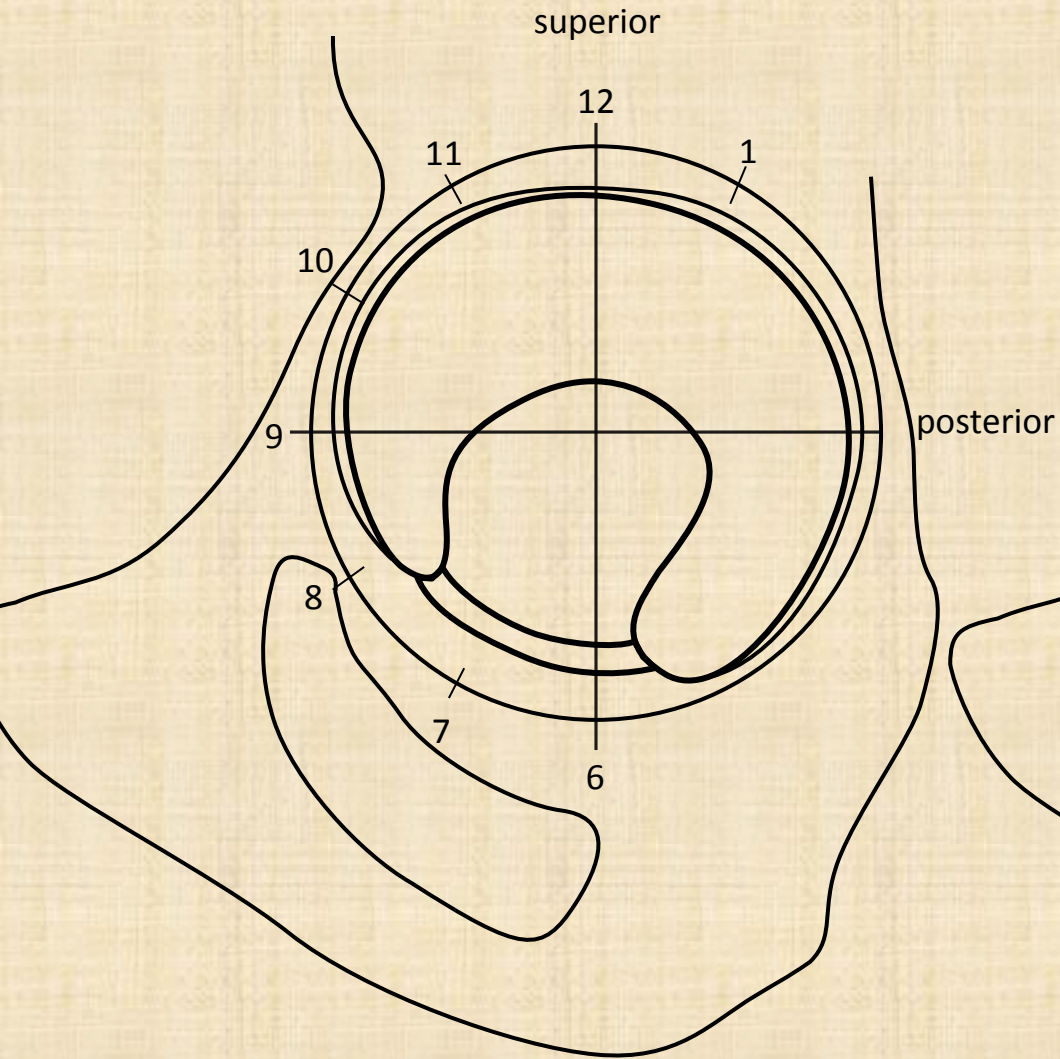
Subtle



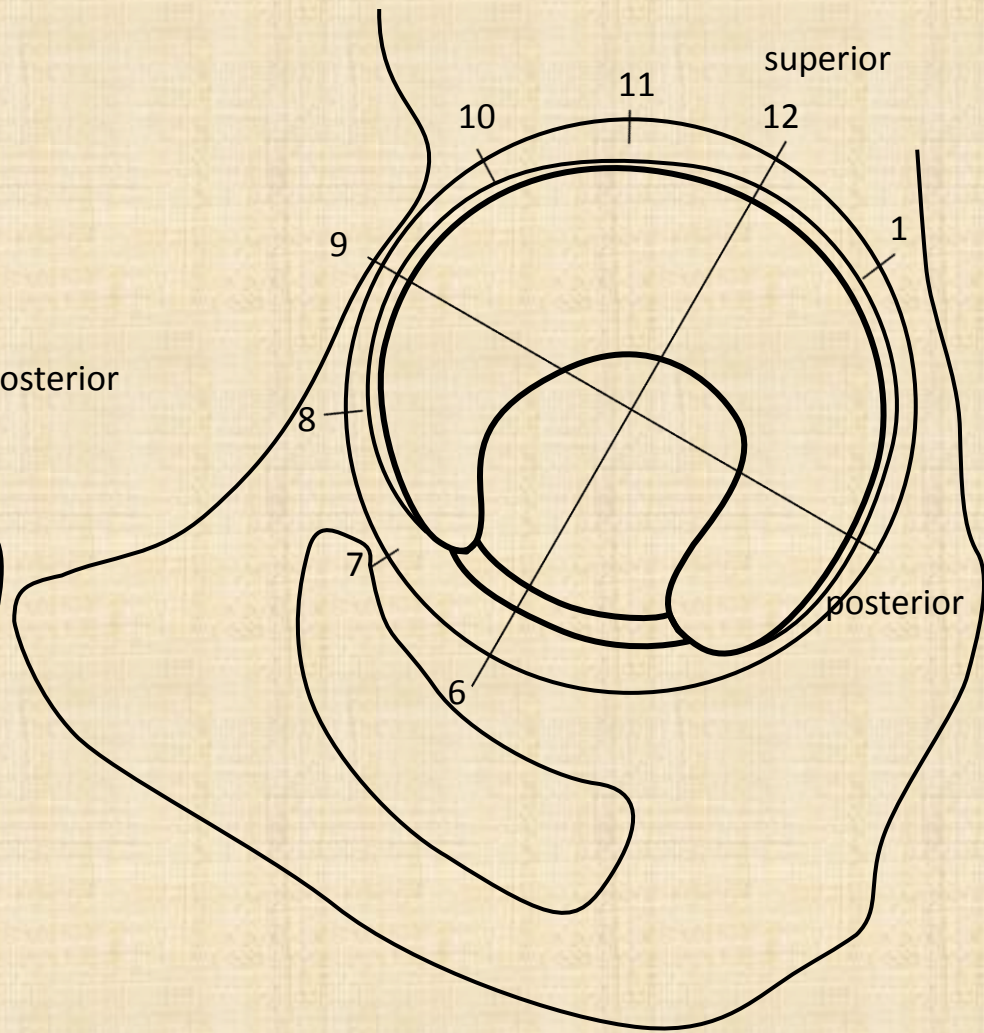
Obvious

Labral tear description

- Location (quadrant + o'clock)
- Type (basal, intrasubstance)
- Underlying degeneration
- Para-(or intra-)labral cyst

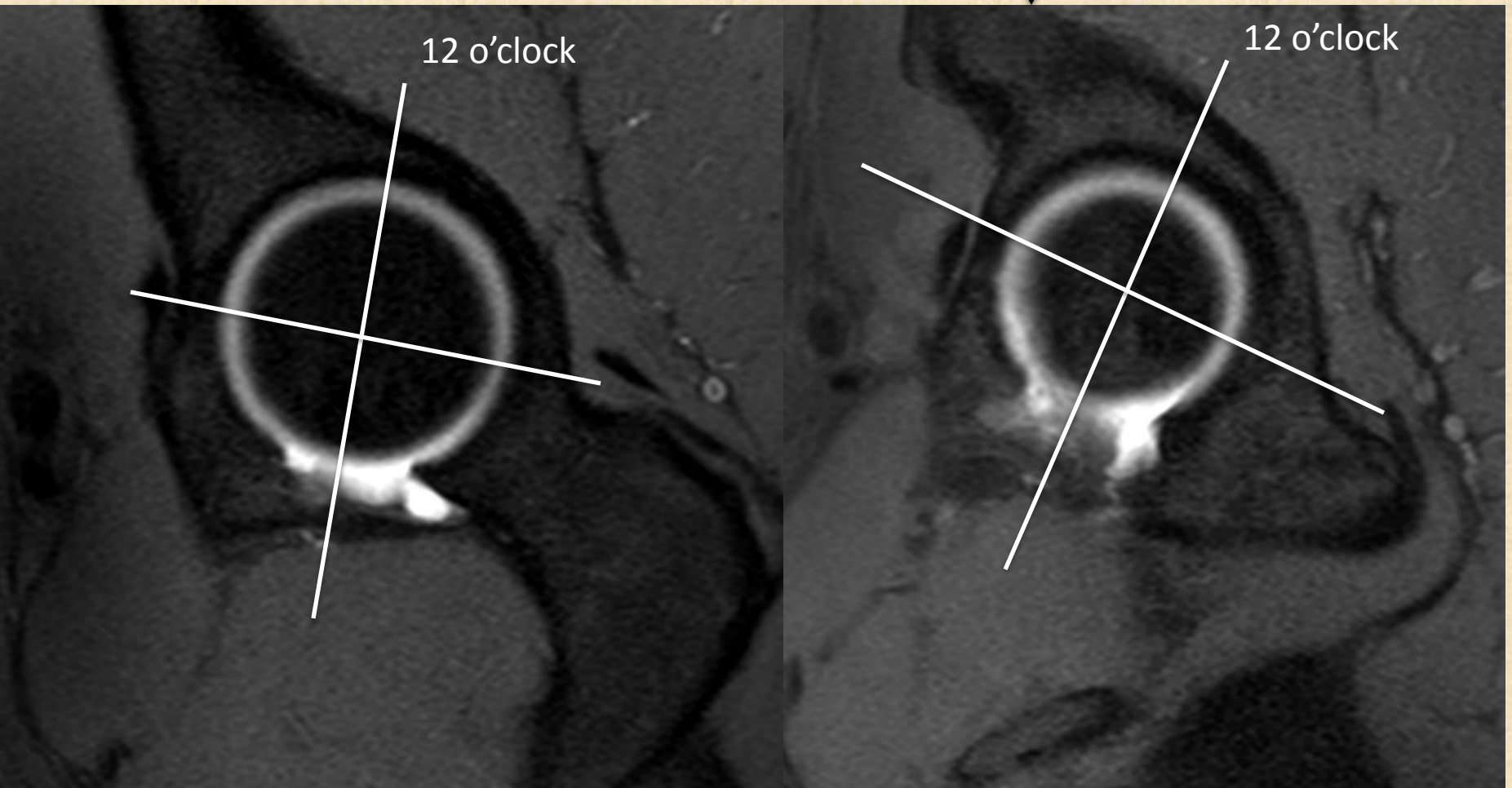
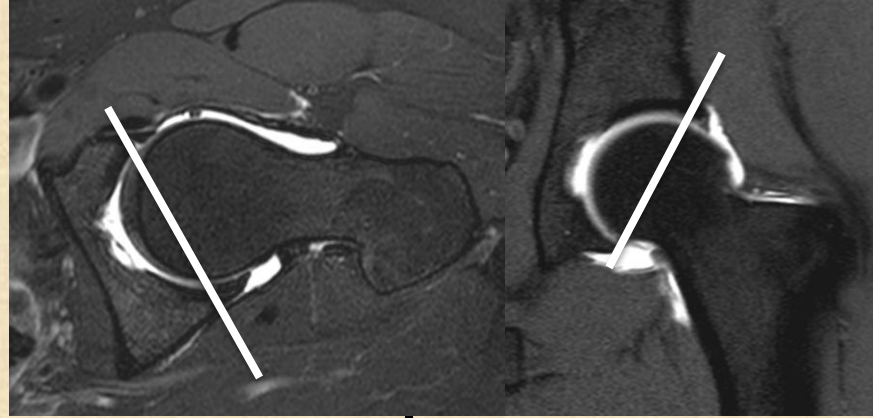


Method 1



Method 2 : preferred

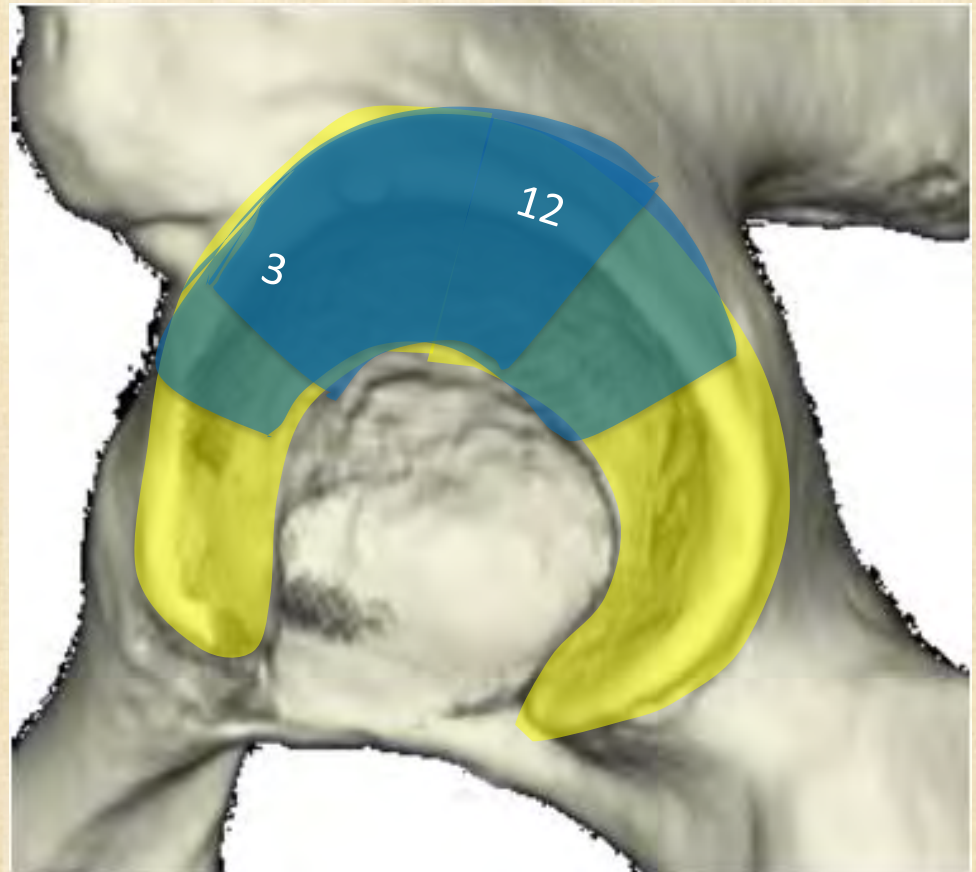
Double oblique sagittal



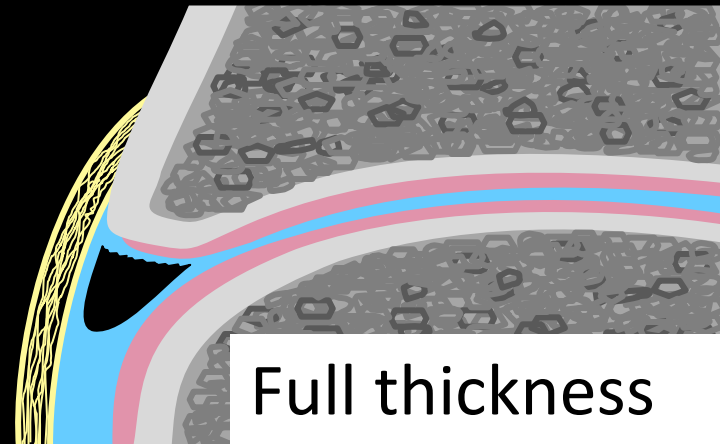
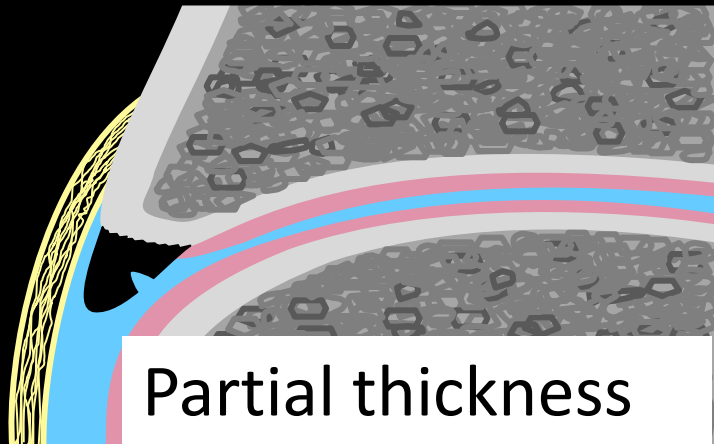
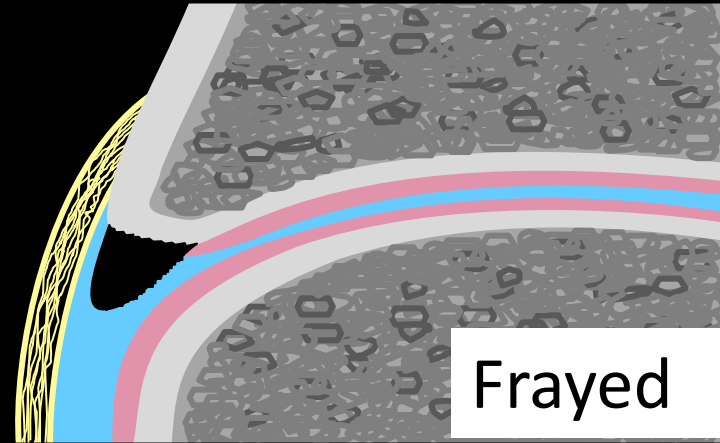
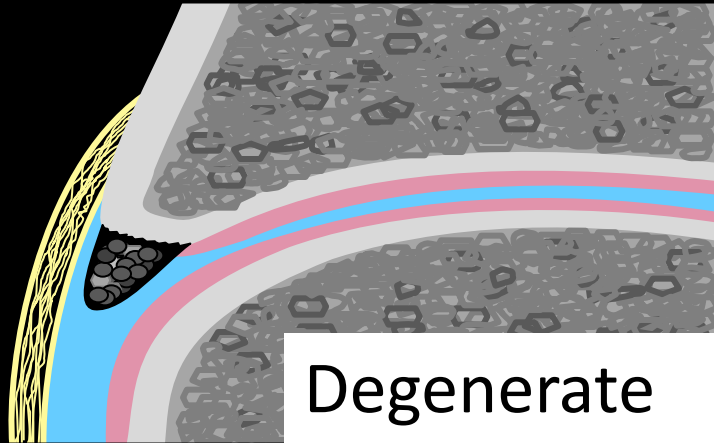
Labral tear location

55% tears occur just between 3 – 12 o'clock

95% occur between 3-12 o'clock & beyond

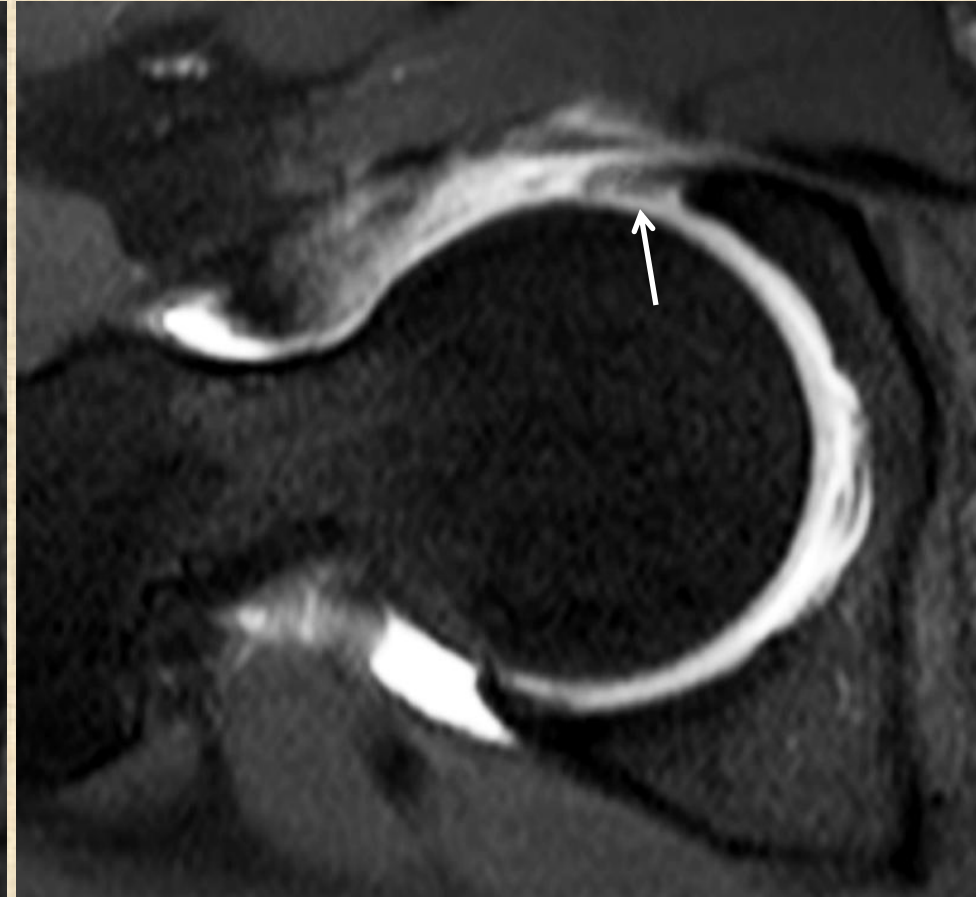
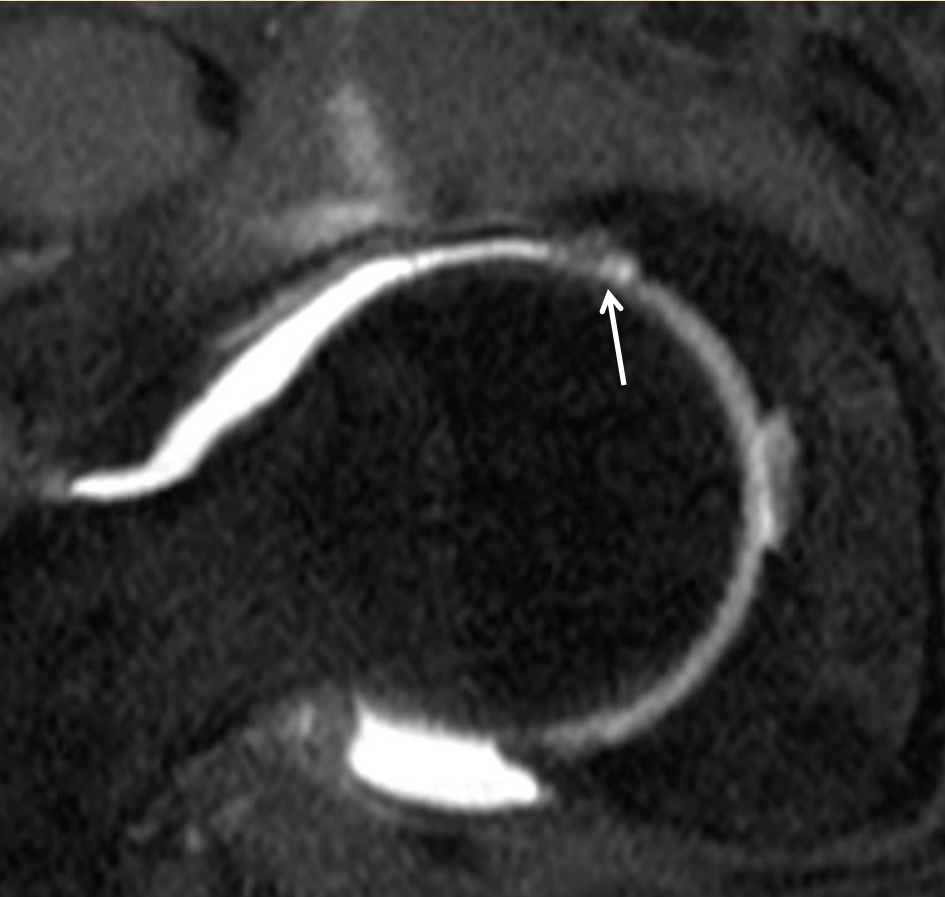


Labral tear description

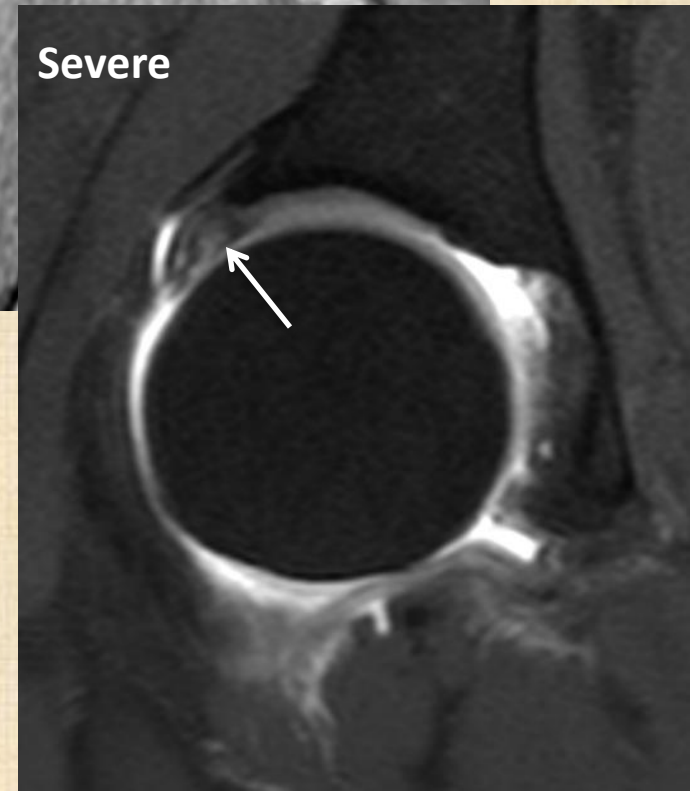
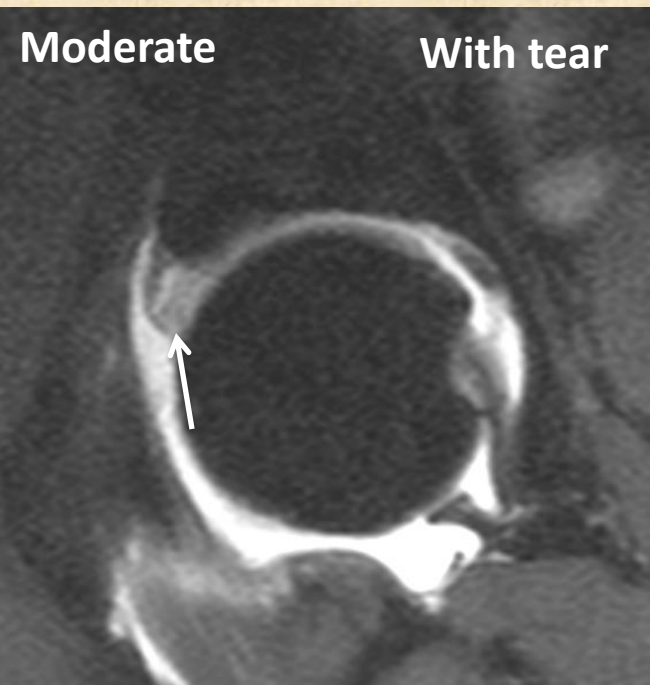
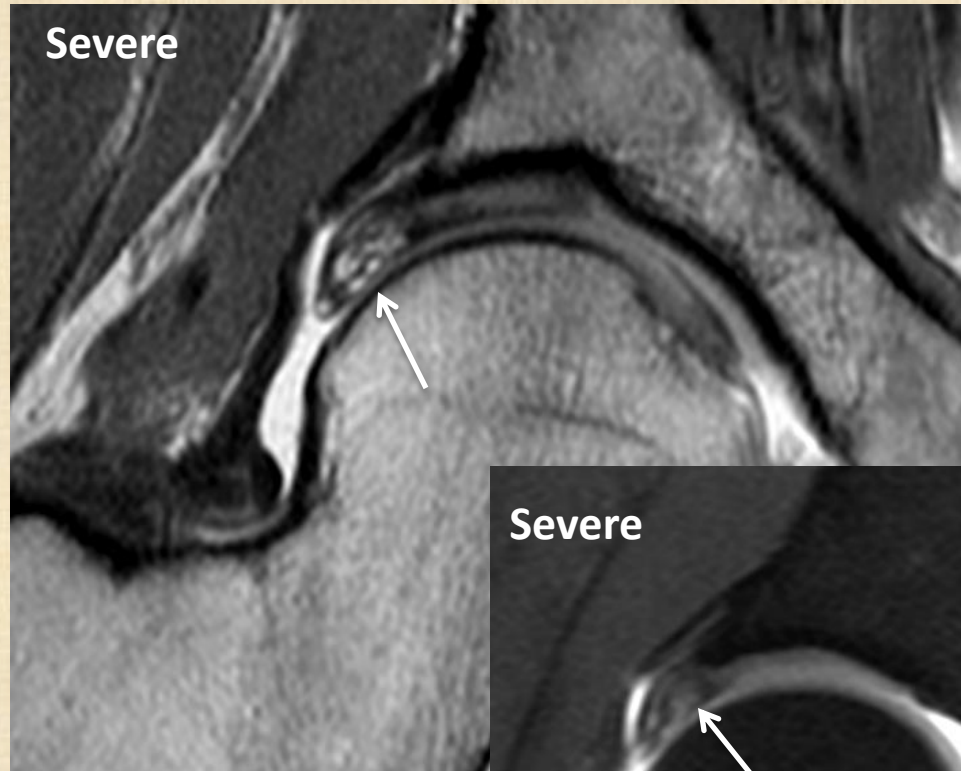
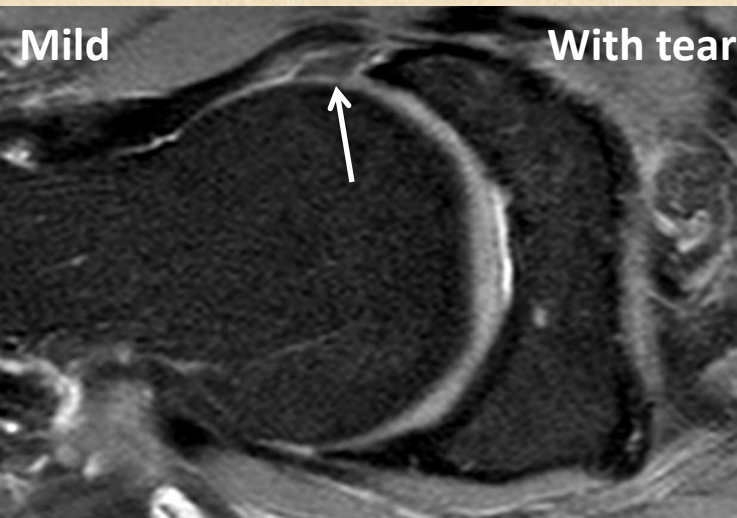


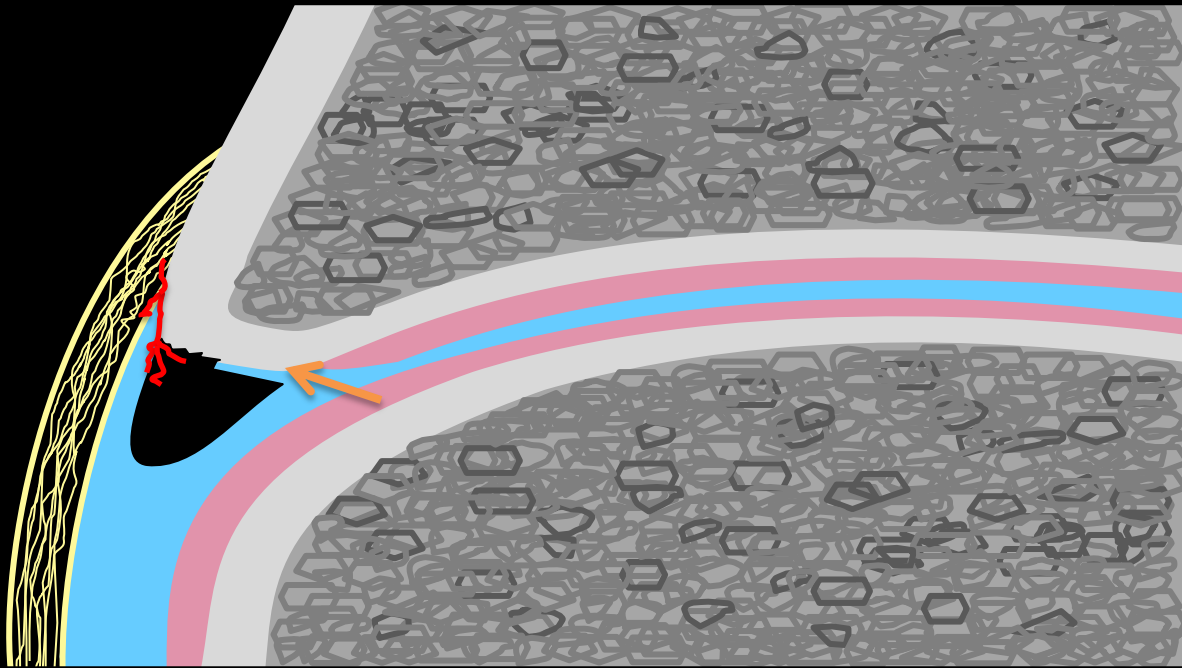
Basal or intrasubstance

Labral fraying

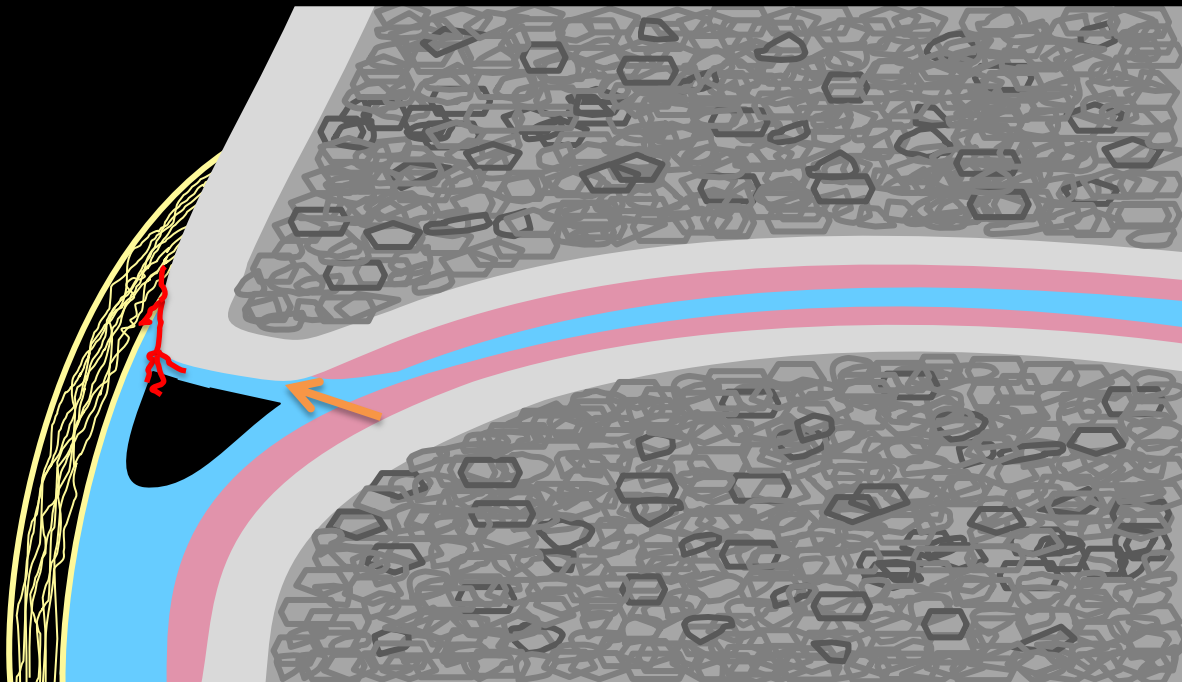


Labral degeneration





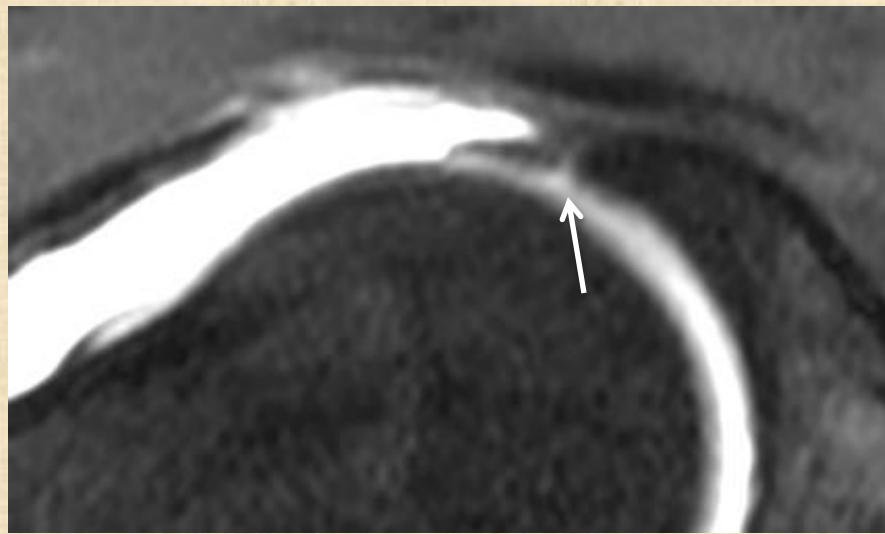
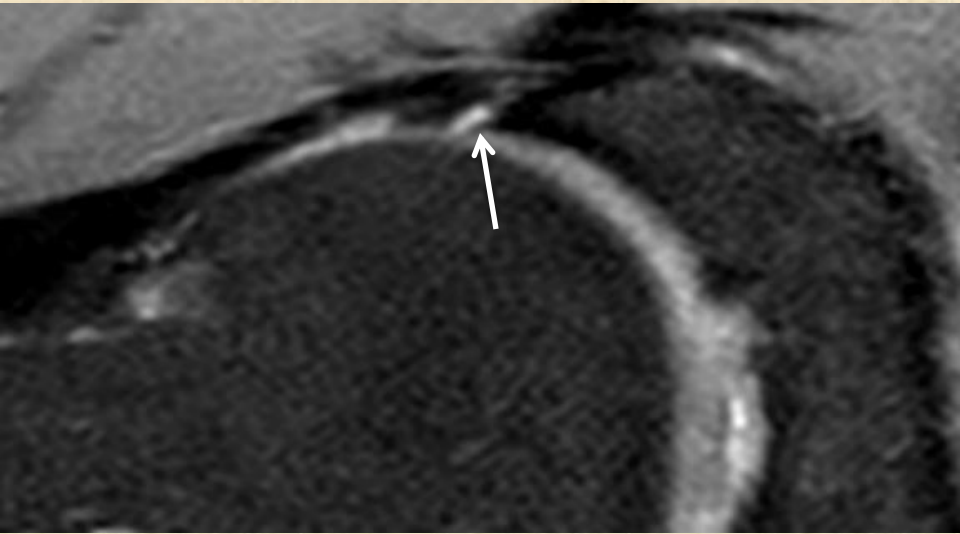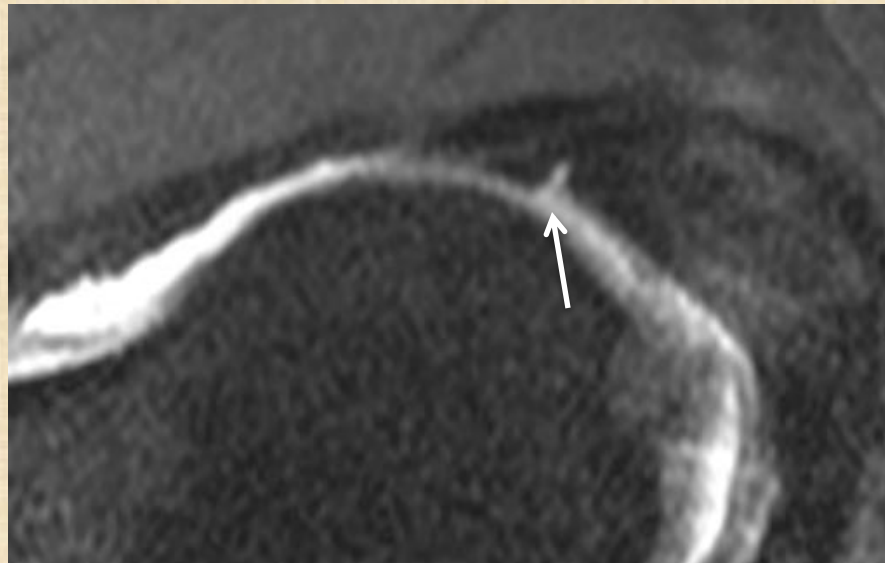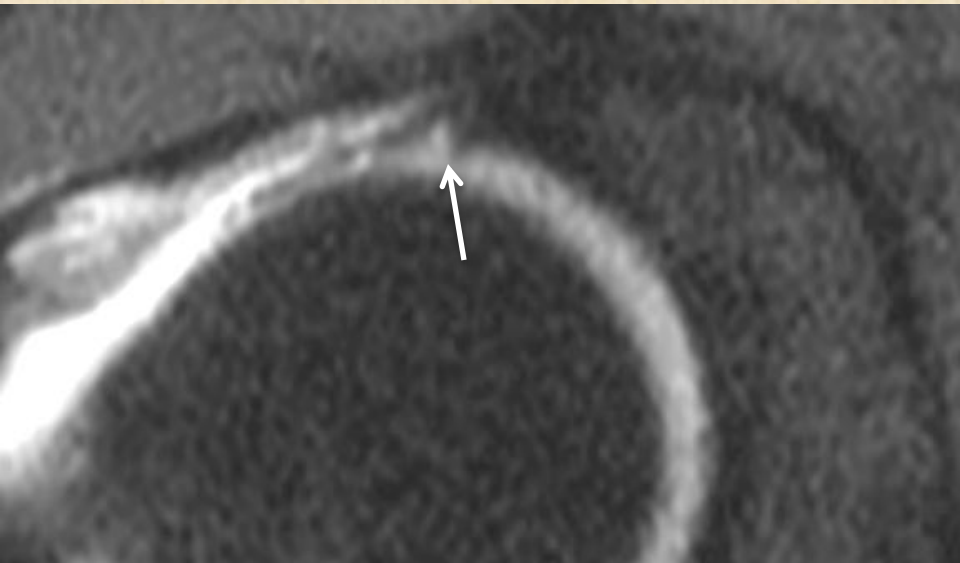
Partial thickness



Full thickness

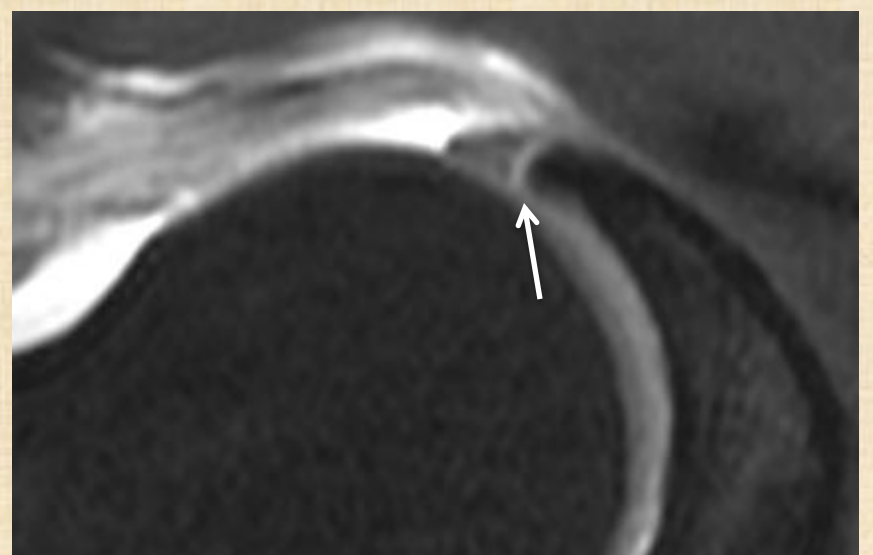
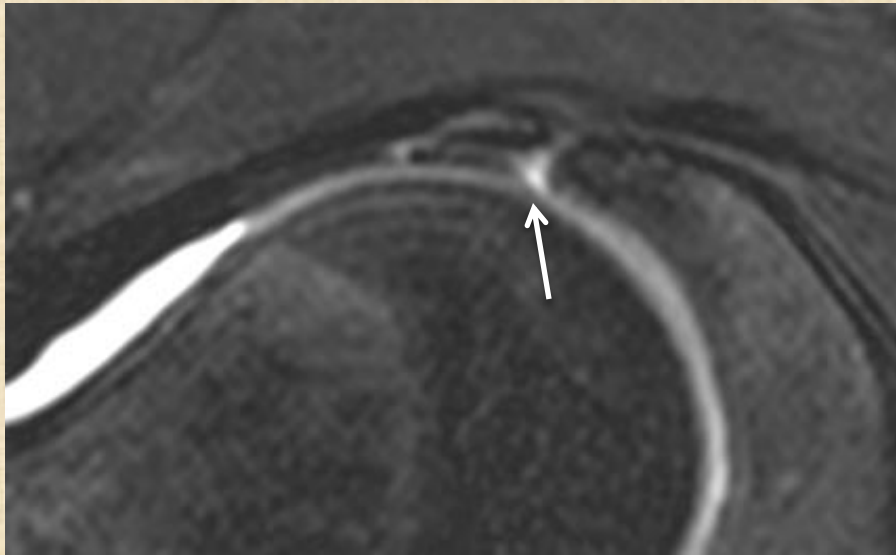
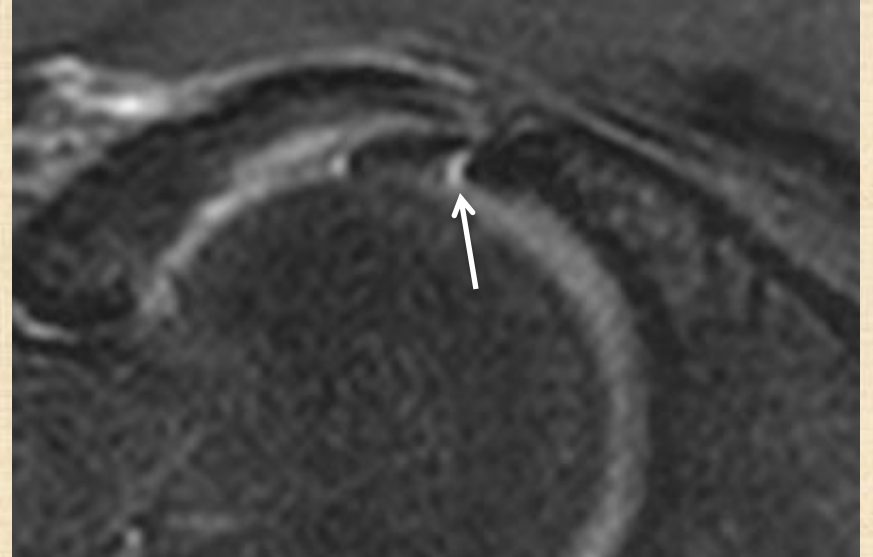
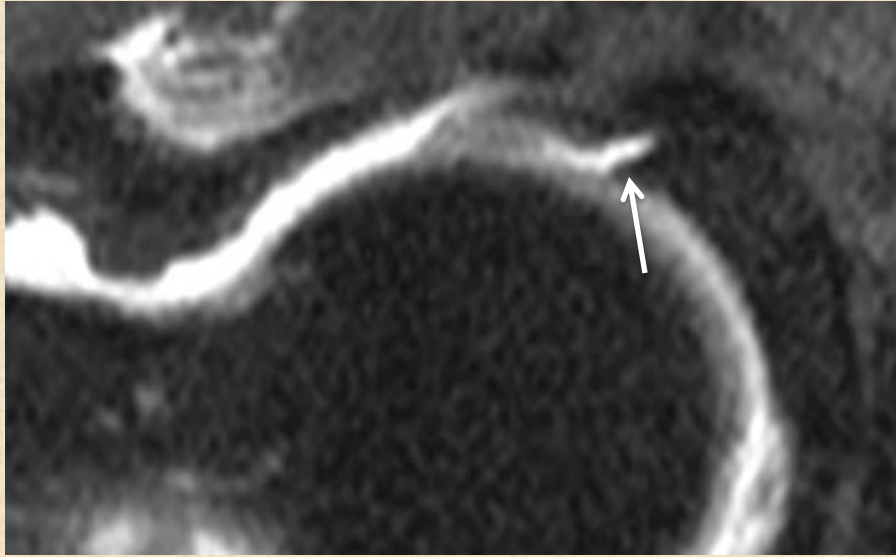Partial thickness

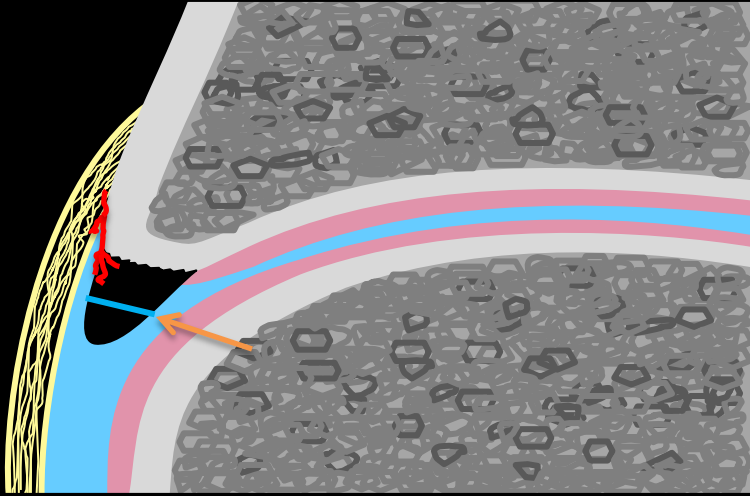
Labral tear : Basal type



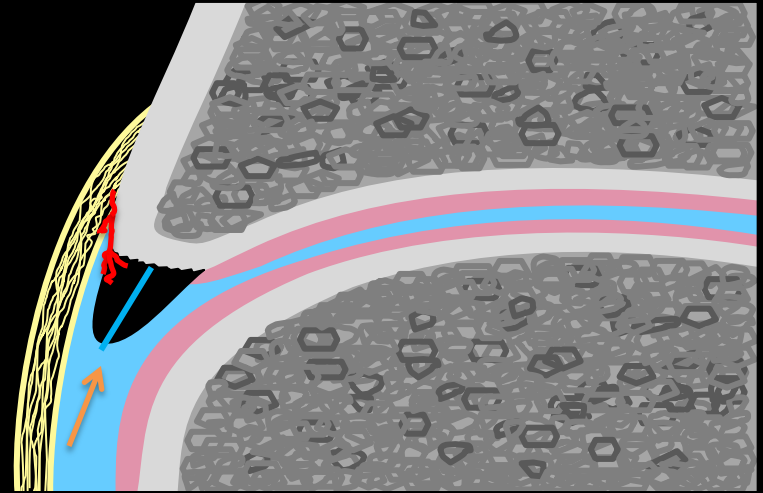
Labral tear : basal type

Full thickness

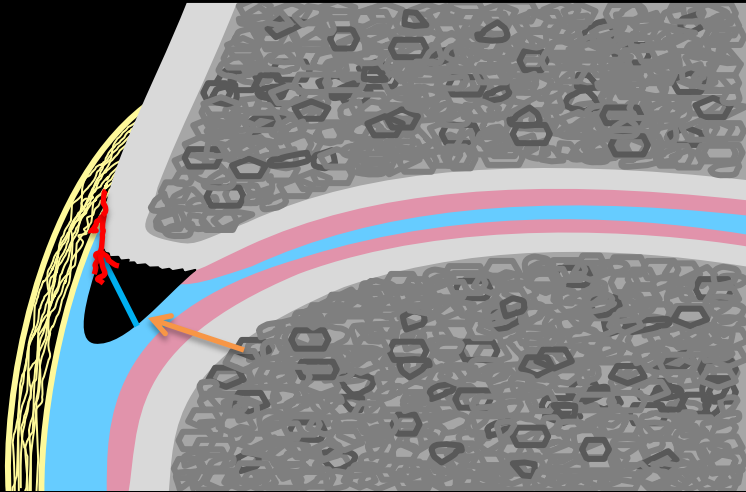




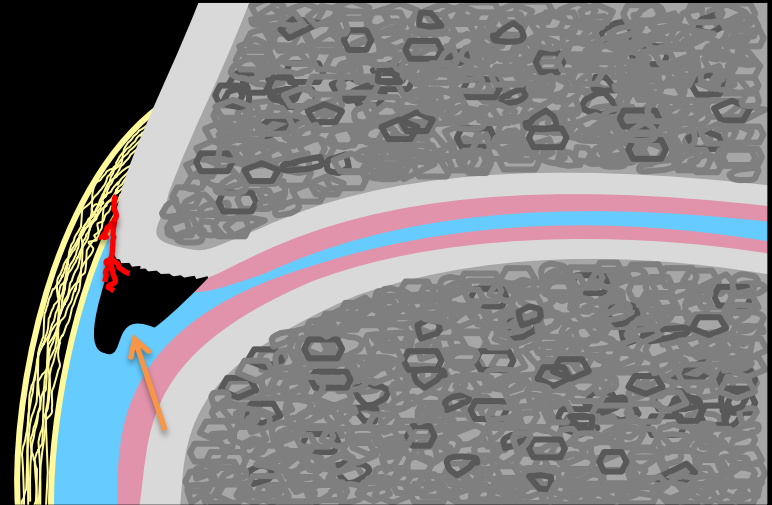
Horizontal



Vertical

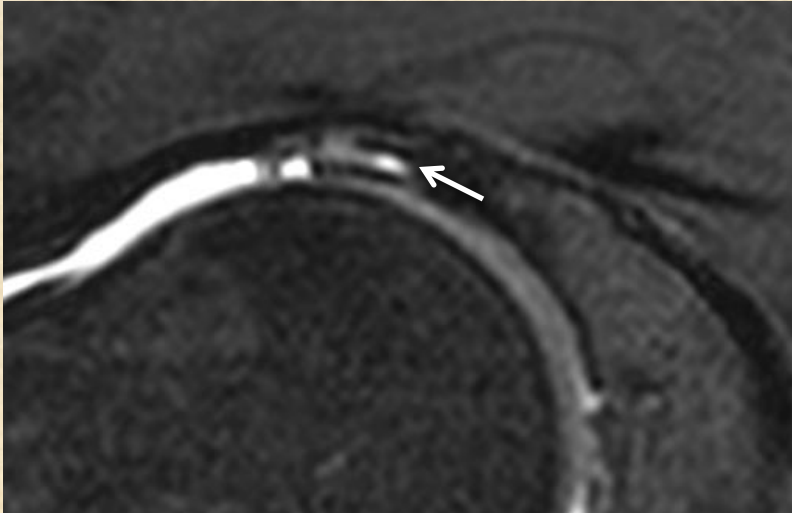


Oblique

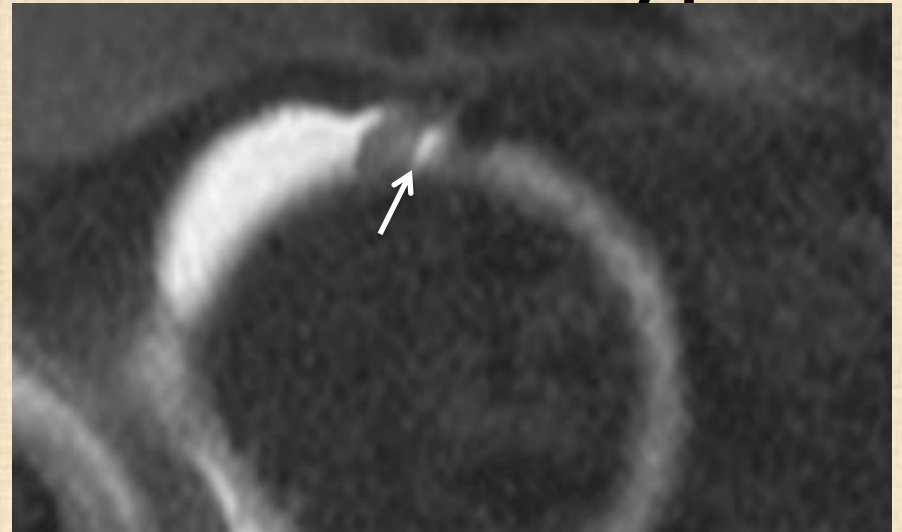

Radial

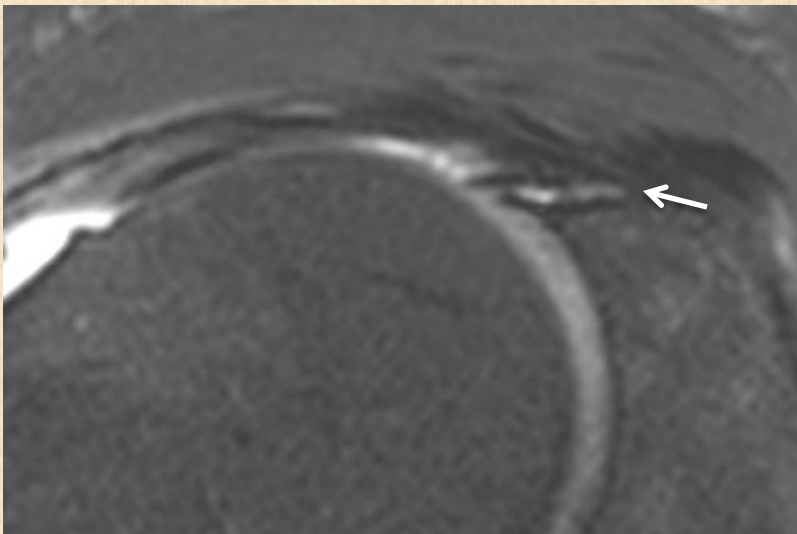
Labral tear : Intrasubstance type



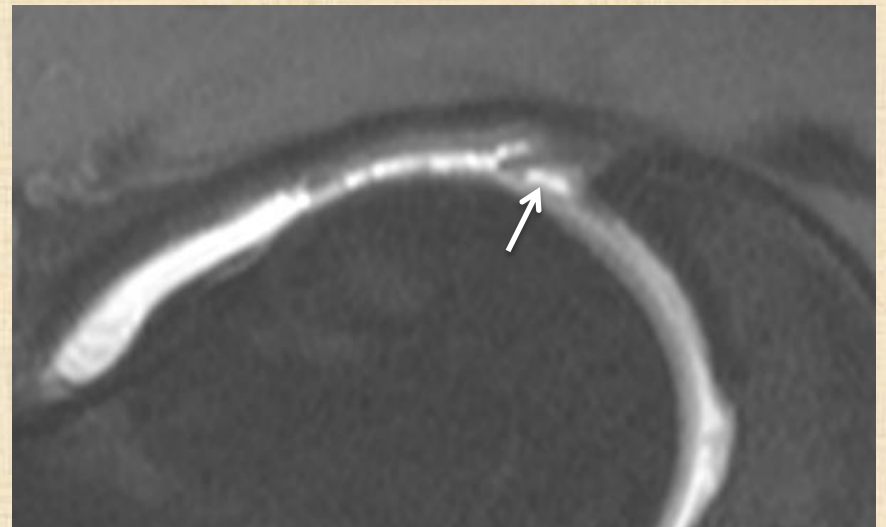
Horizontal



Vertical

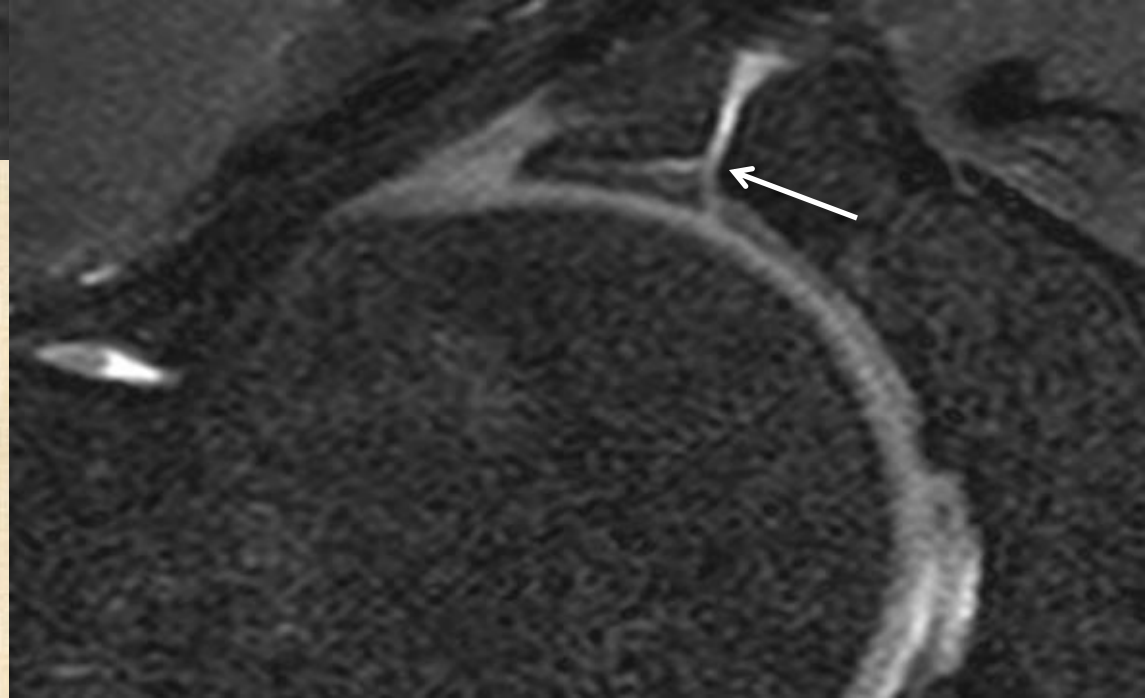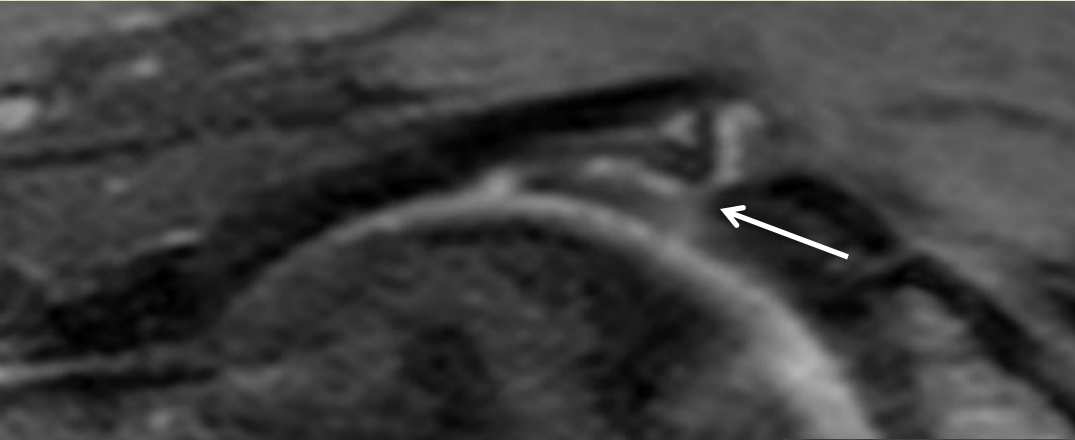


Oblique

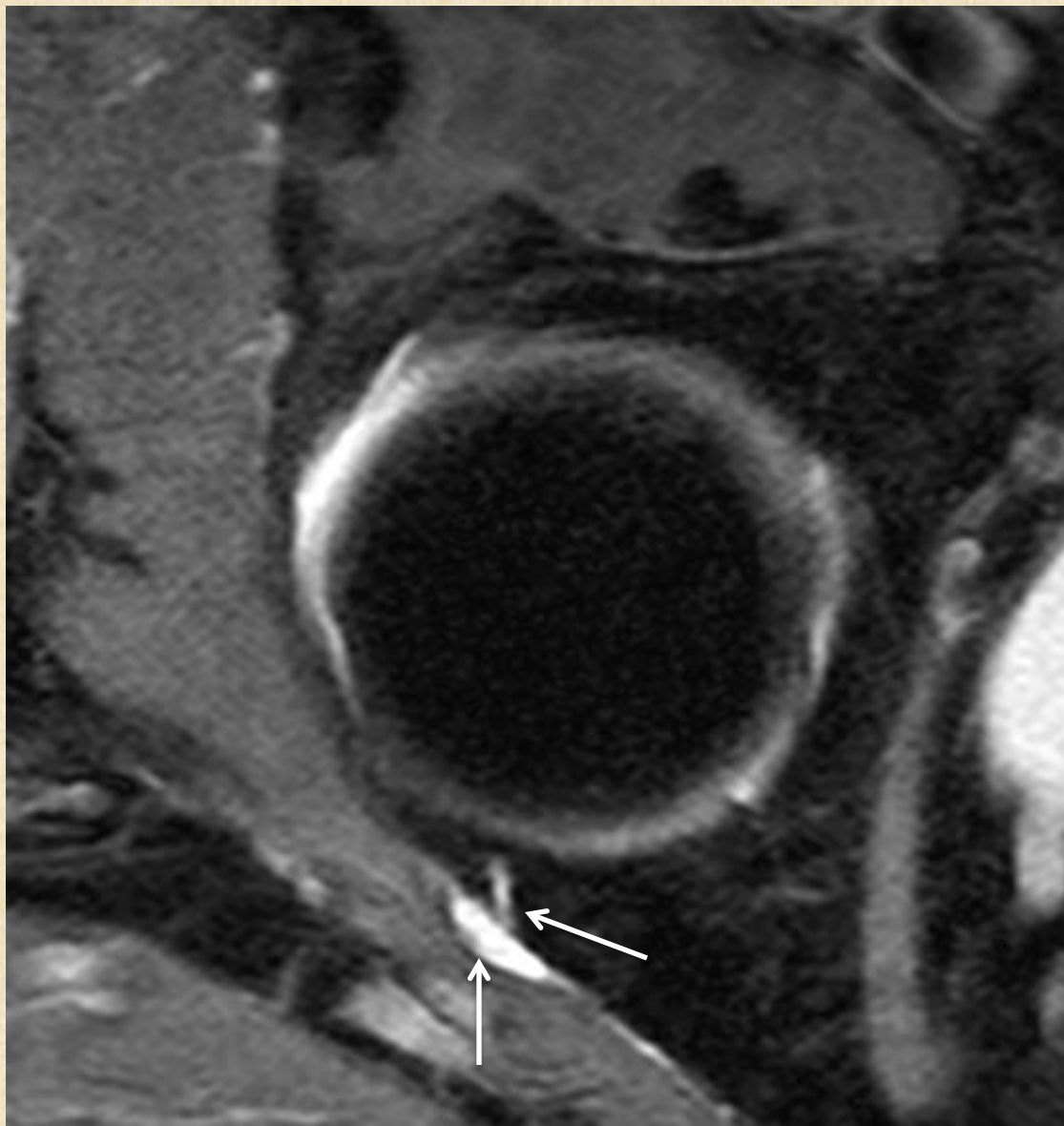


Radial

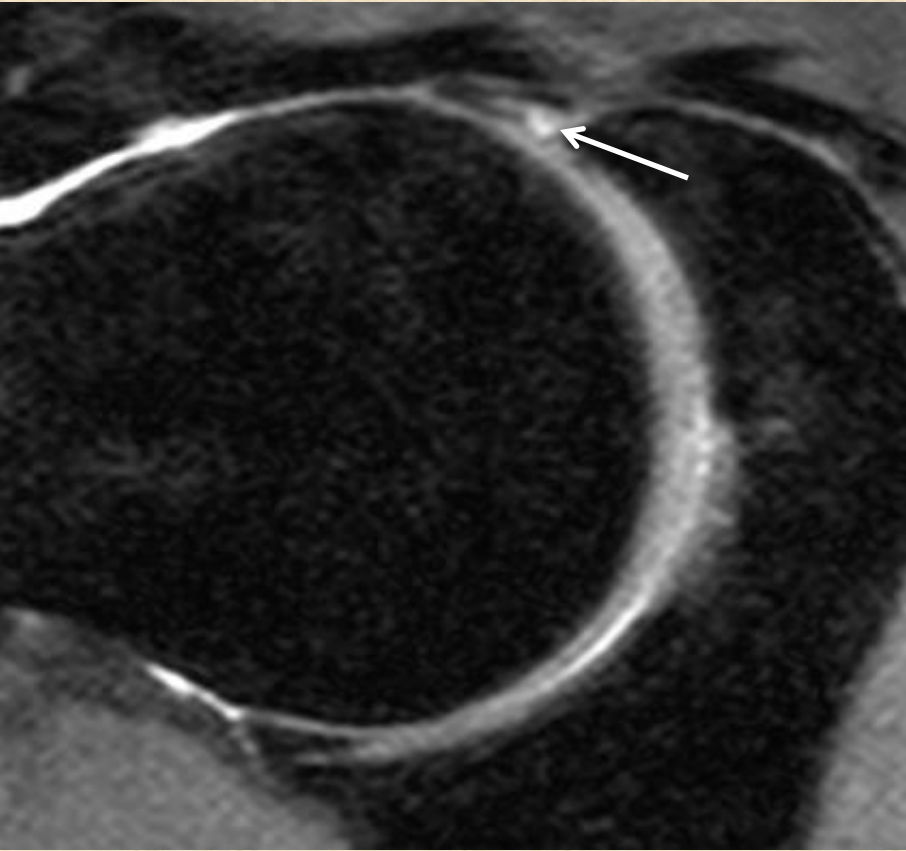
Labral tear : mixed basal and intrasubstance type



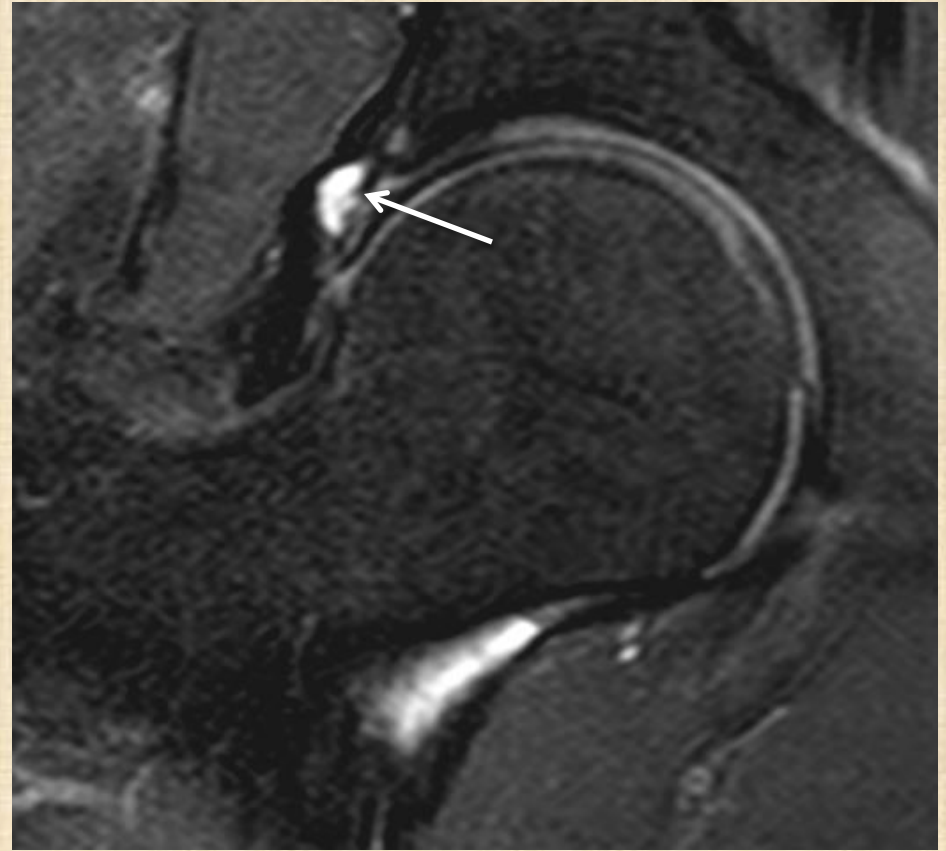
Posterior tear



Intralabral and paralabral cyst

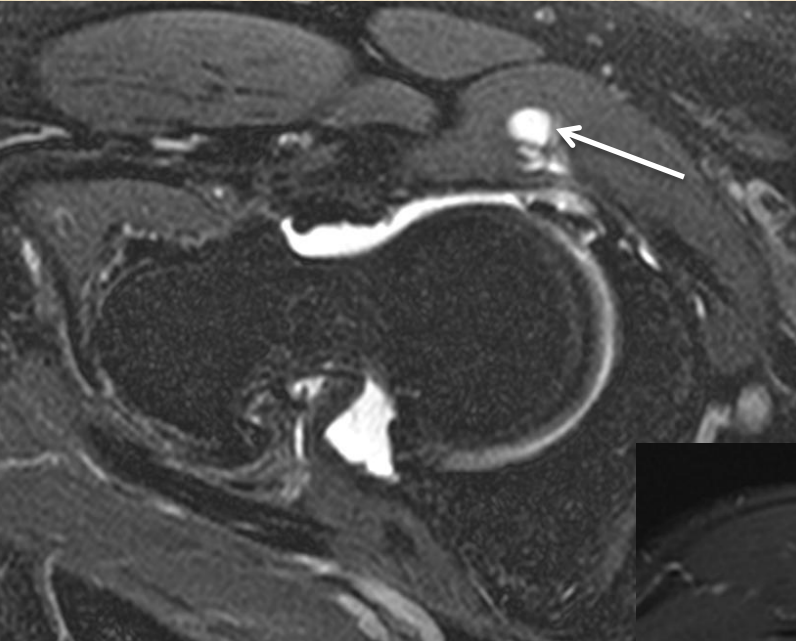
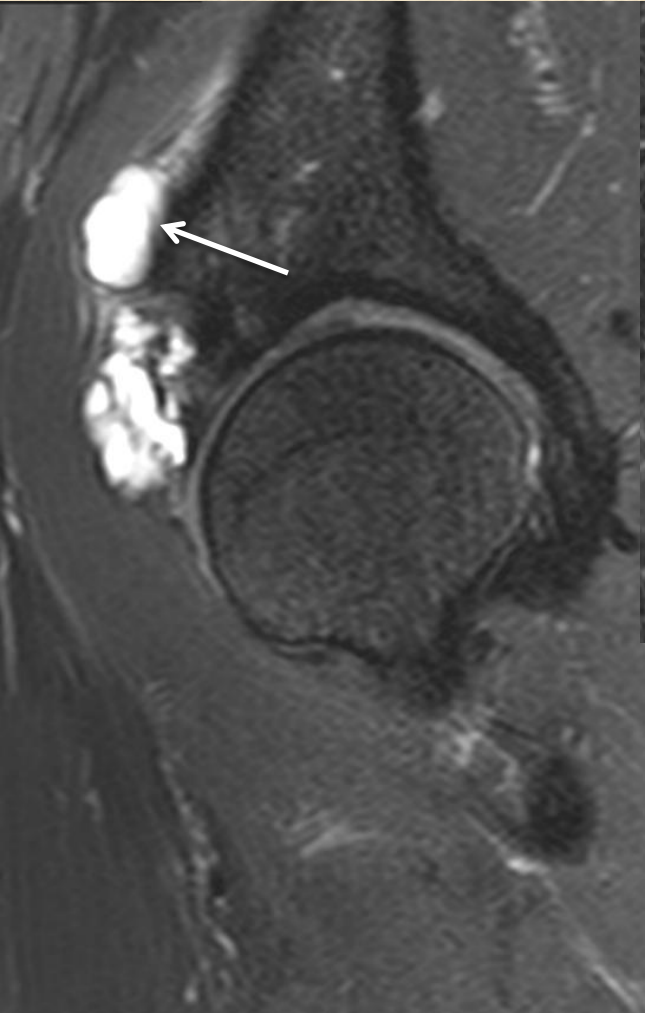


Intra-labral cyst



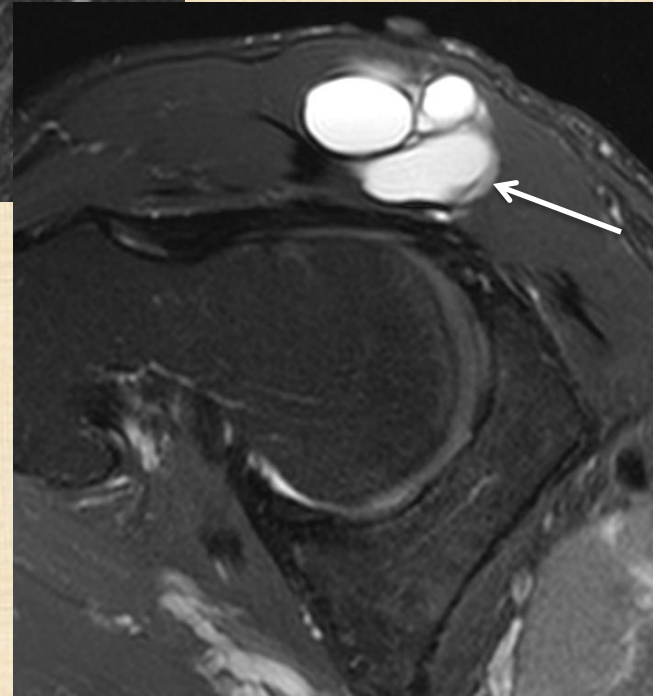
Para-labral cyst

Paralabral cysts

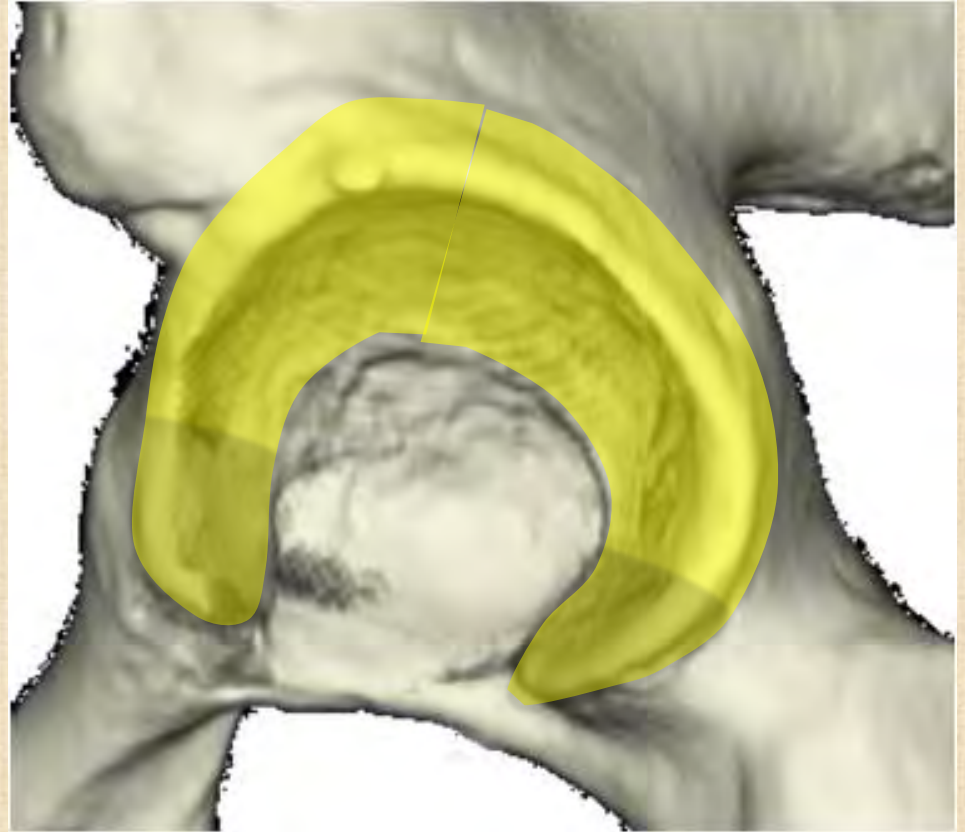
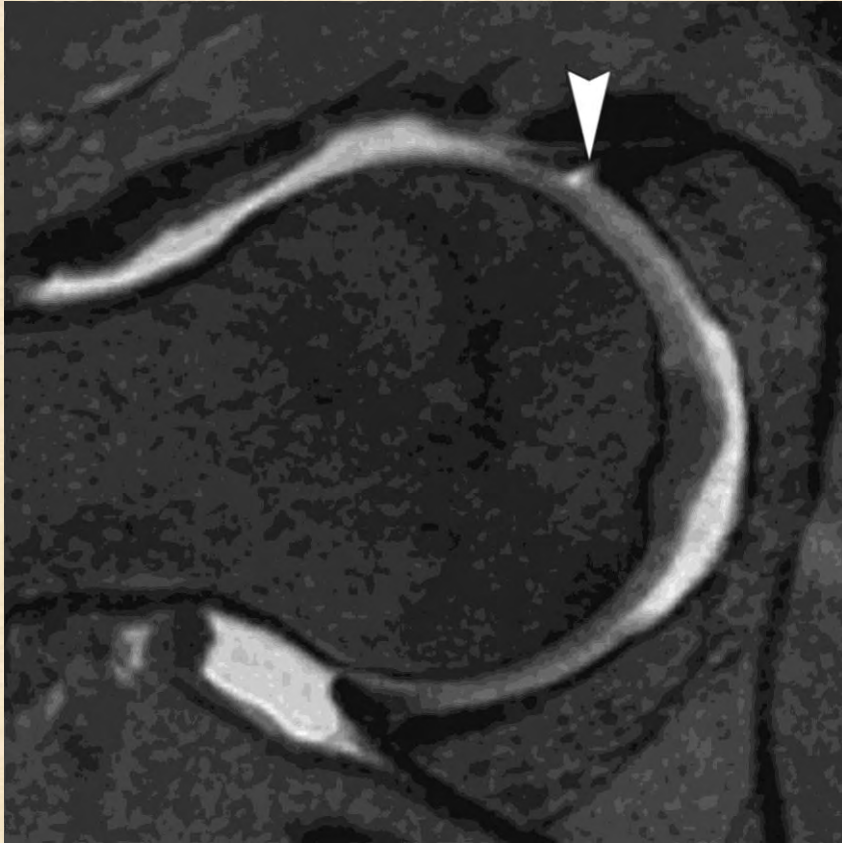
Within rectus femoris
muscle

Within iliopsoas
muscle

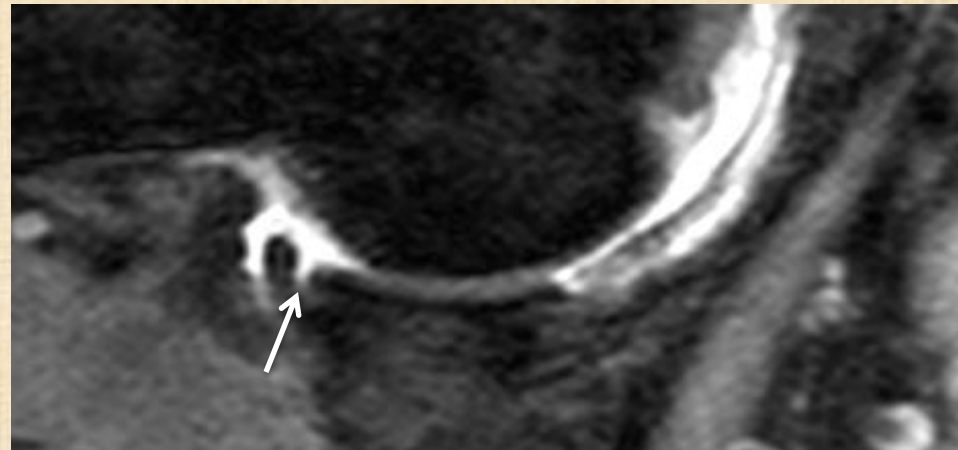
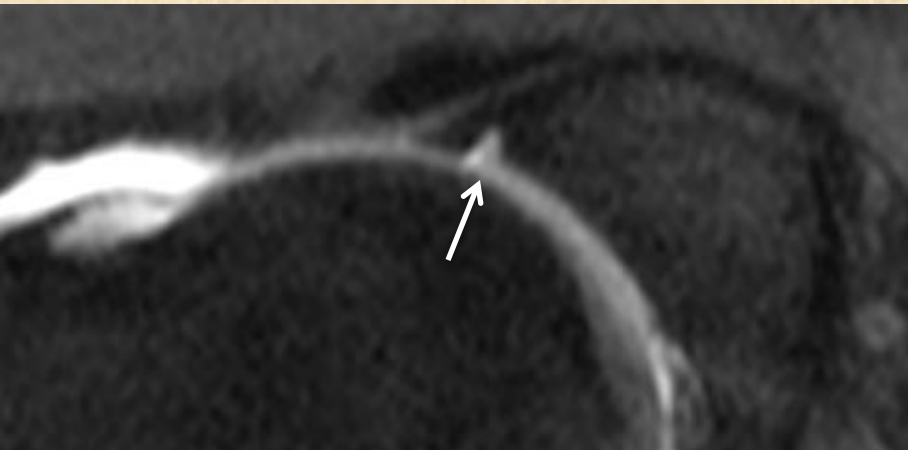
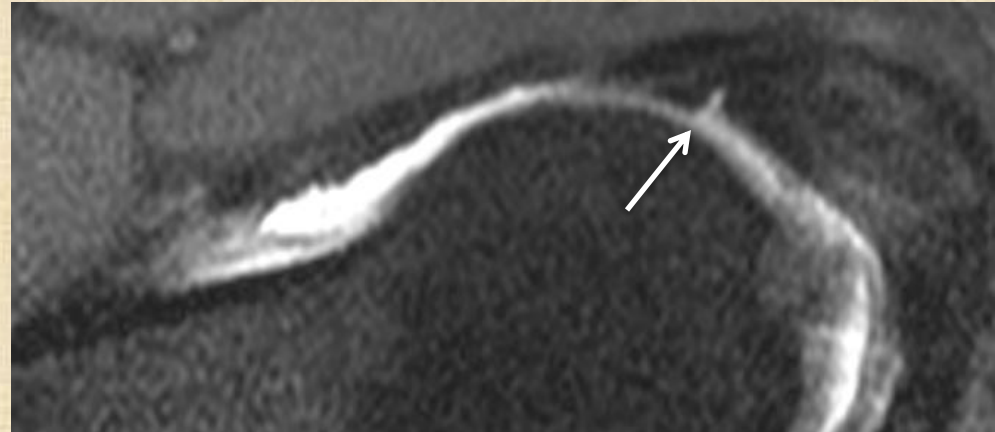
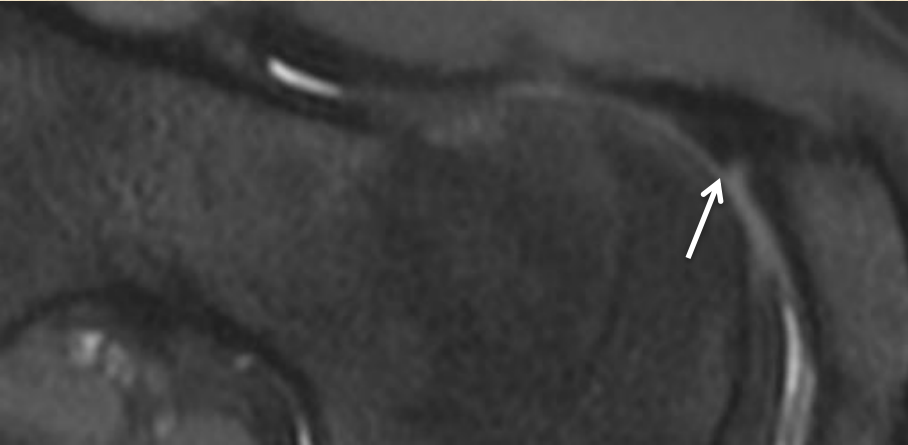


Sublabral sulcus

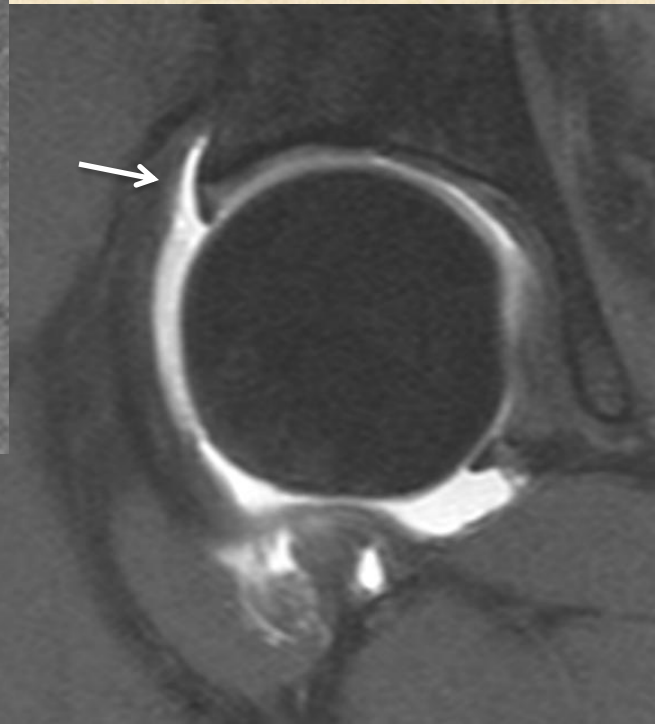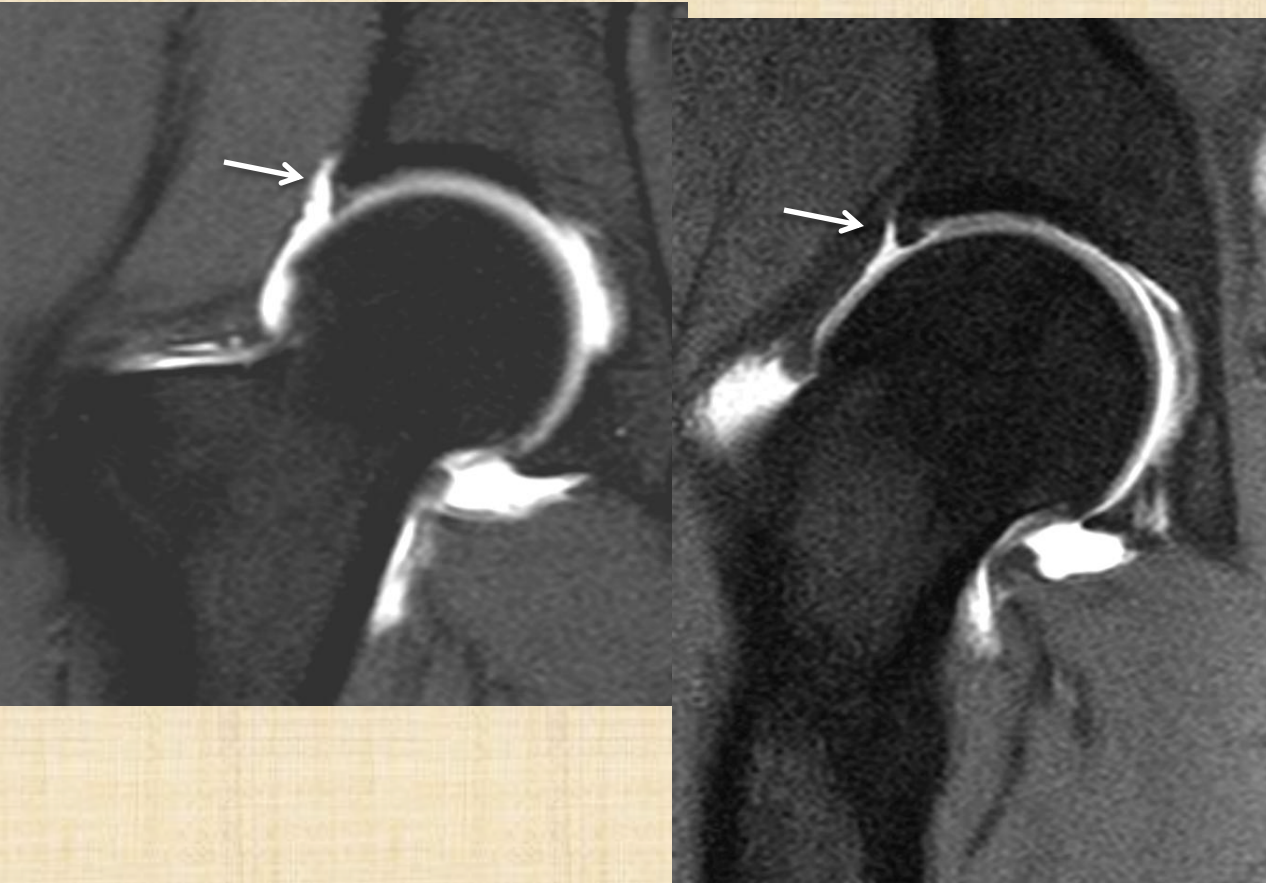


Anywhere but more commonly inferiorly
20% of normal population ?

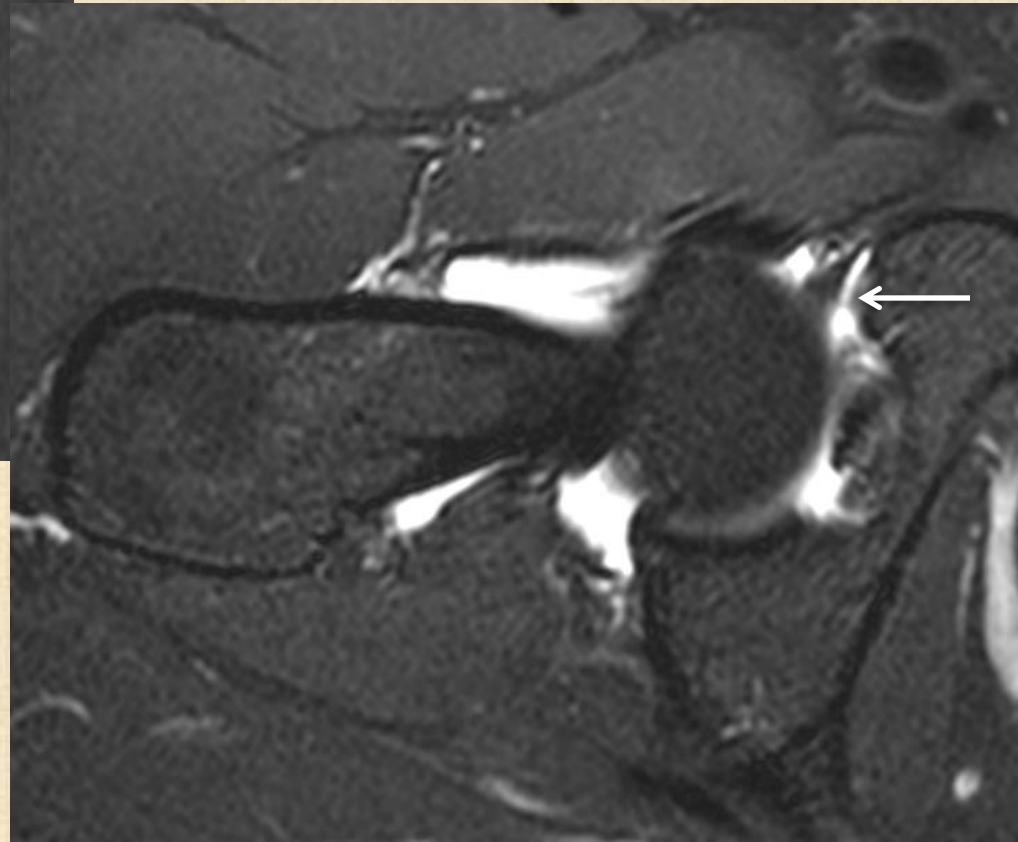
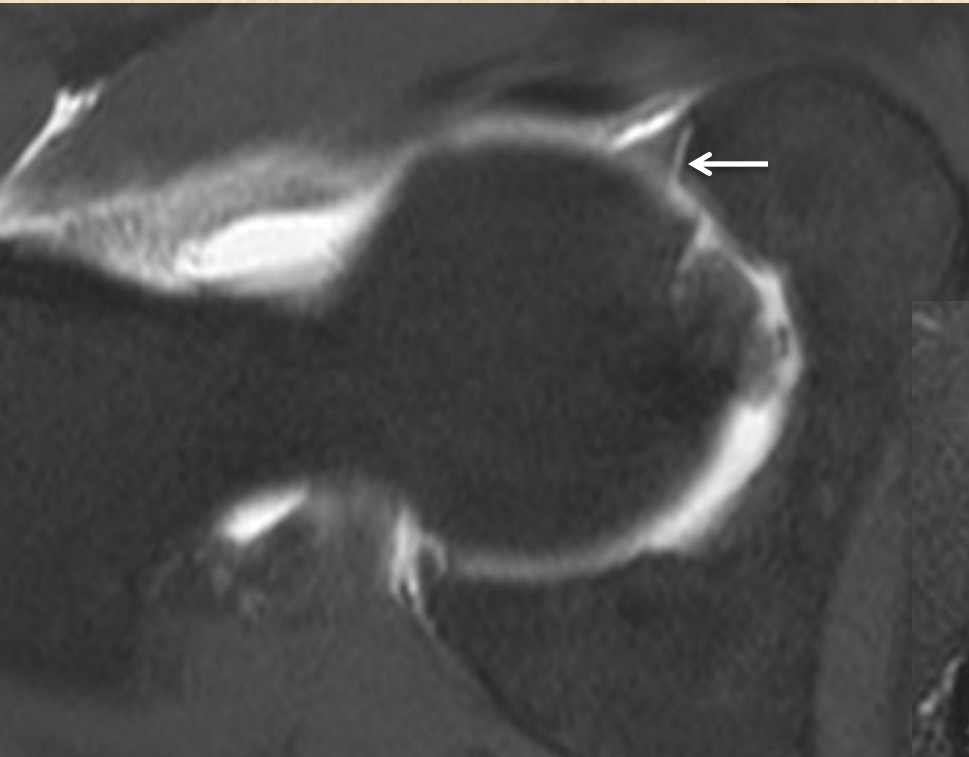
Sublabral sulcus/recess



Para (peri)labral recess/sulcus



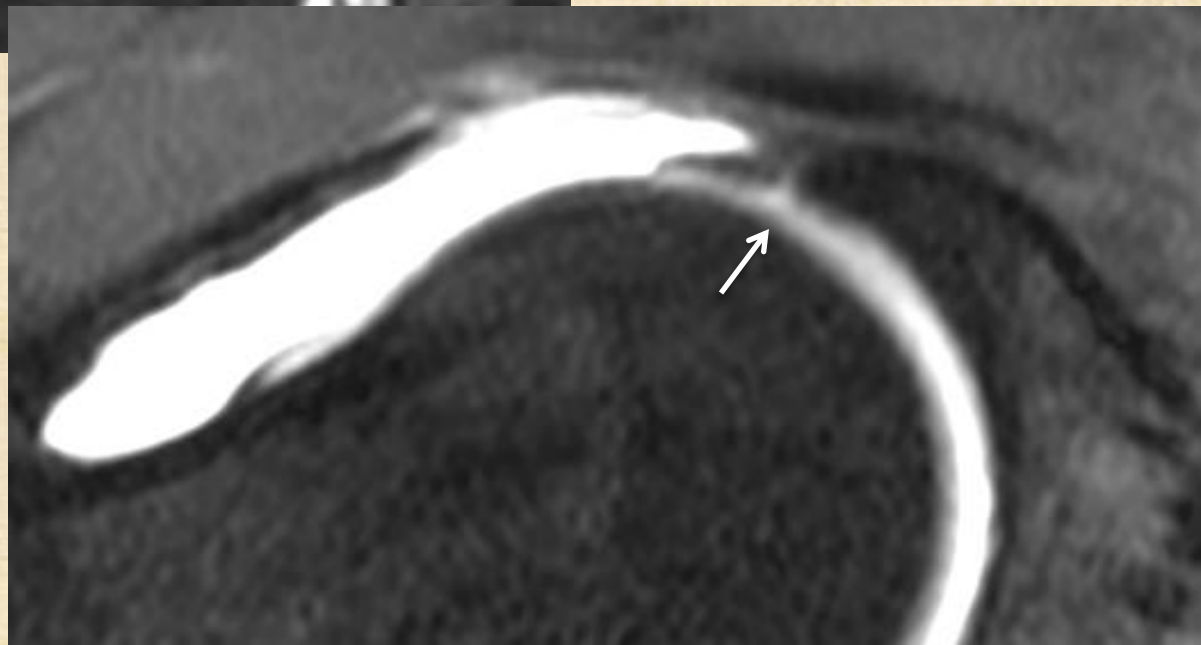
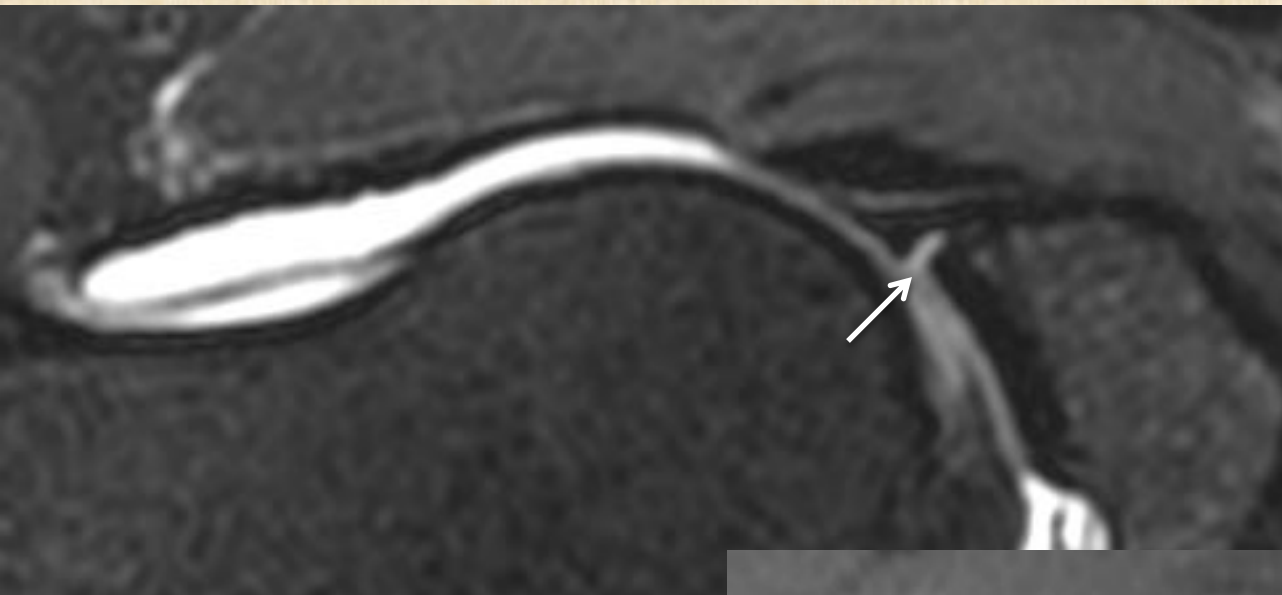
Labroligamentous sulcus



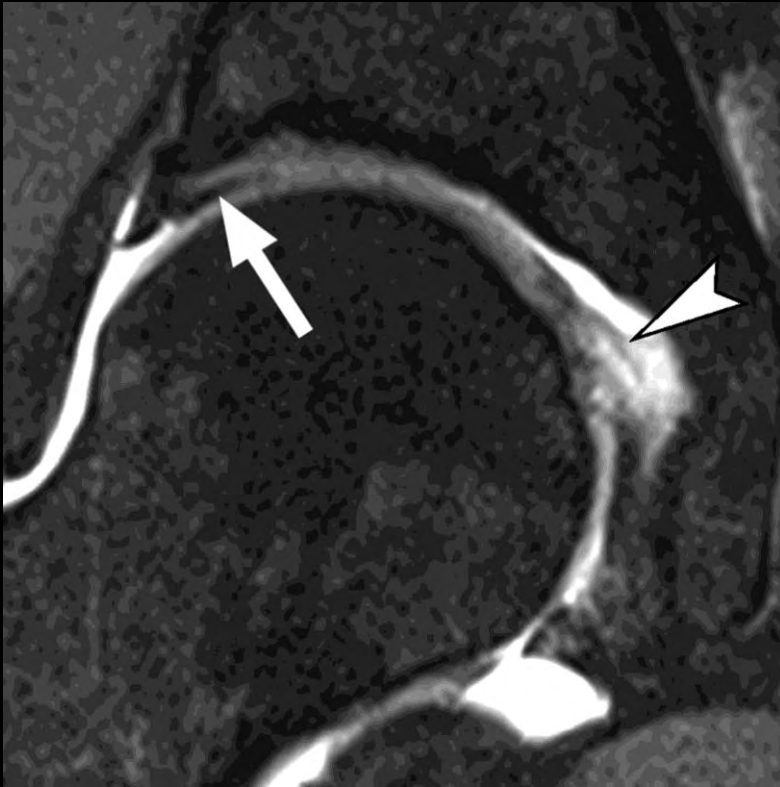Sulcus or tear

	Sulcus	Tear
Outline	Smooth	Irregular
Location	Inferiorly or posteriorly Base	Anterosuperiorly Base or intrasubstance
Depth	More shallow (< ½ depth)	Deeper
Shape	Non Linear (triangular) Wider than depth	Linear
Associated findings	No paralabral cyst	Paralabral cyst

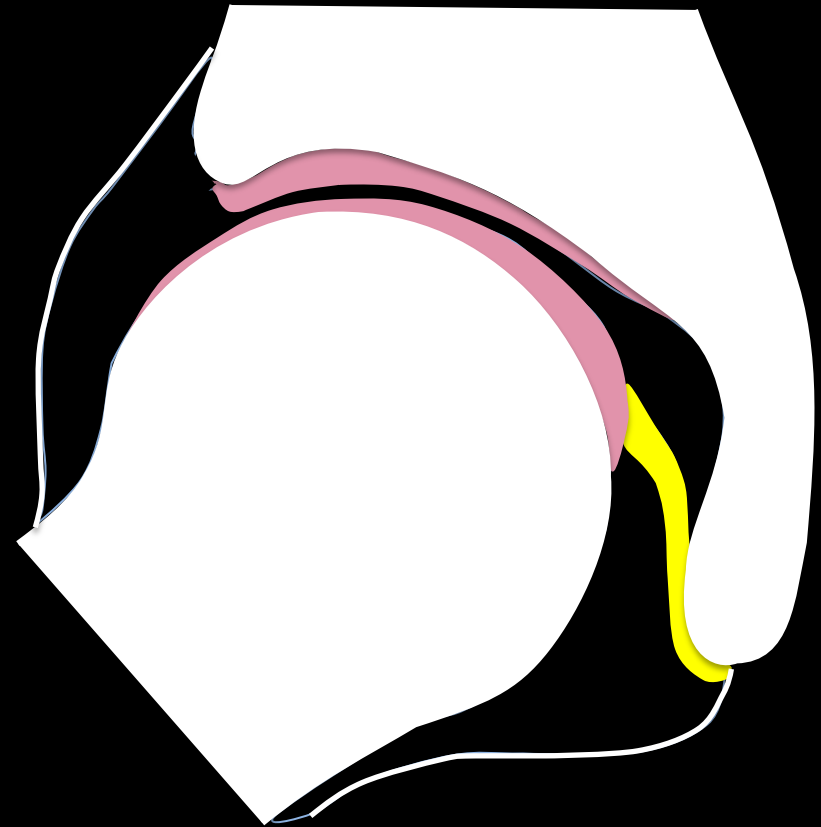
Sulcus vs partial tear



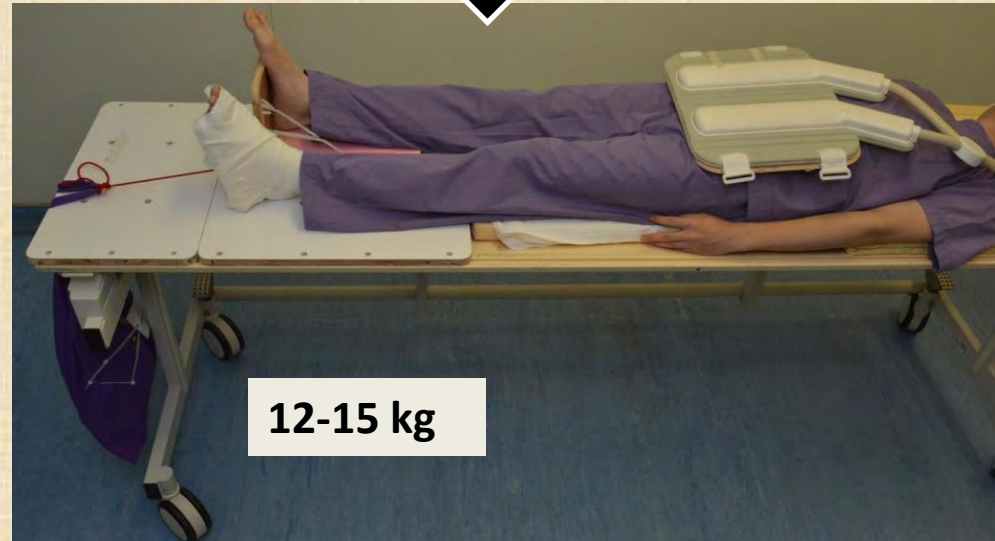
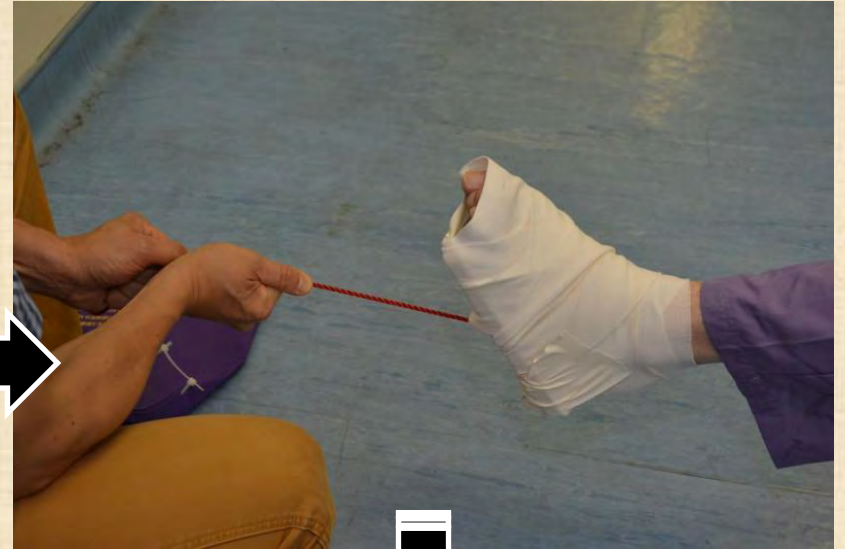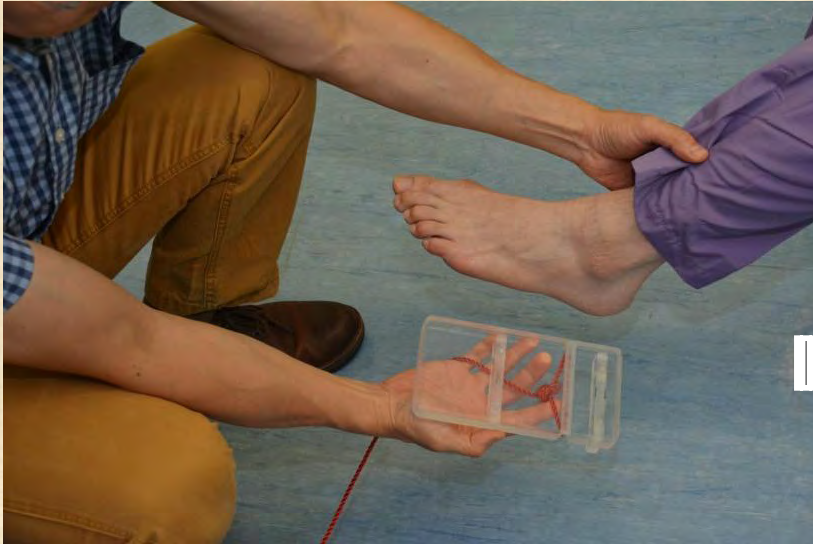Chondral cartilage



Cartilage delamination
& ligamentum teres tear

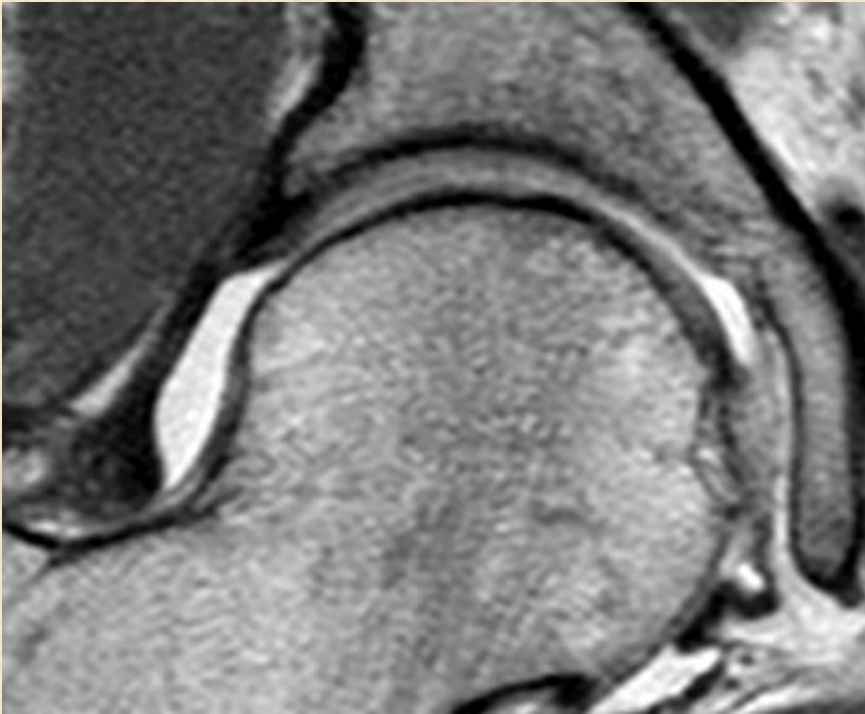


Hip traction

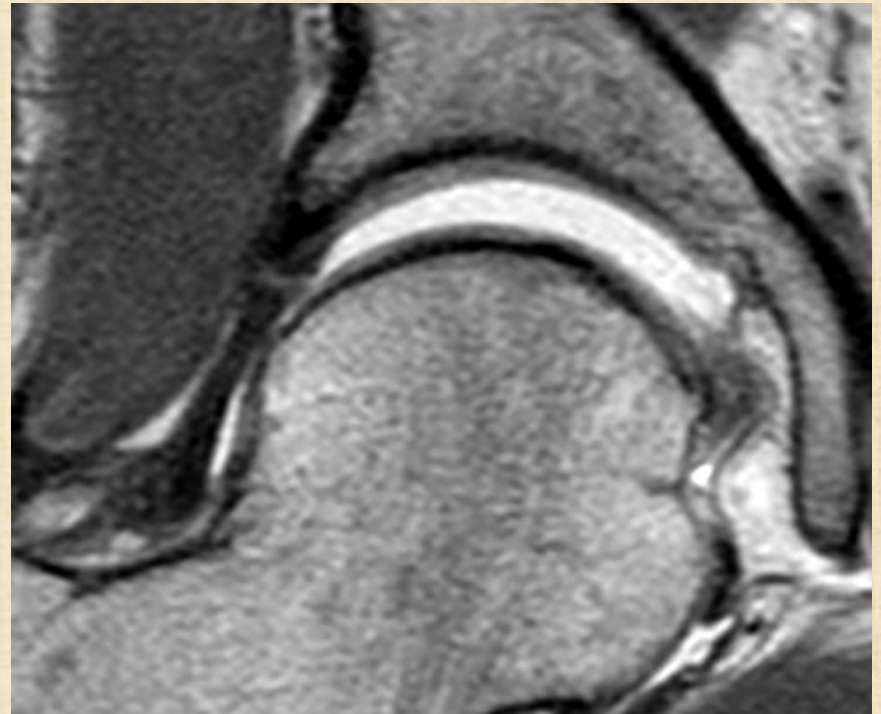


12-15 kg

Better cartilage visibility

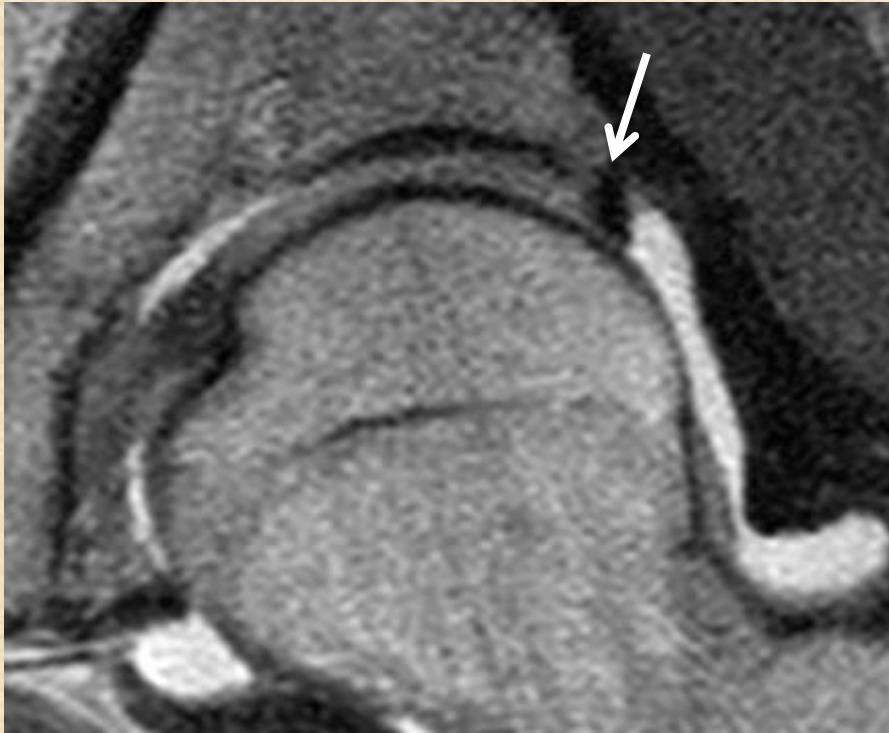


Pre-Traction

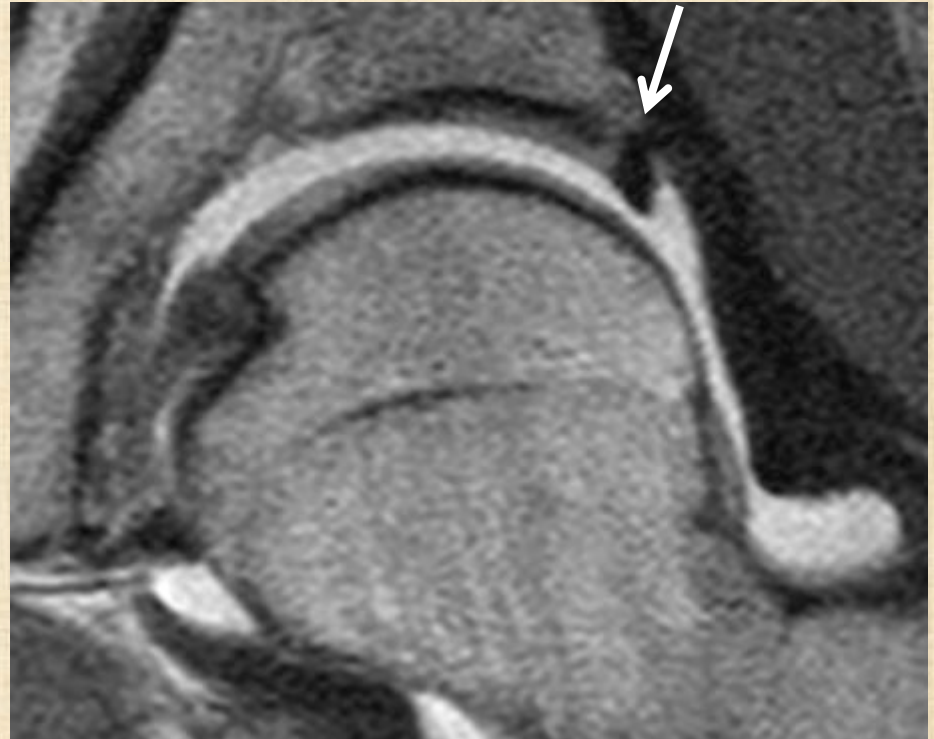

Post-Traction

Better labrochondral visibility

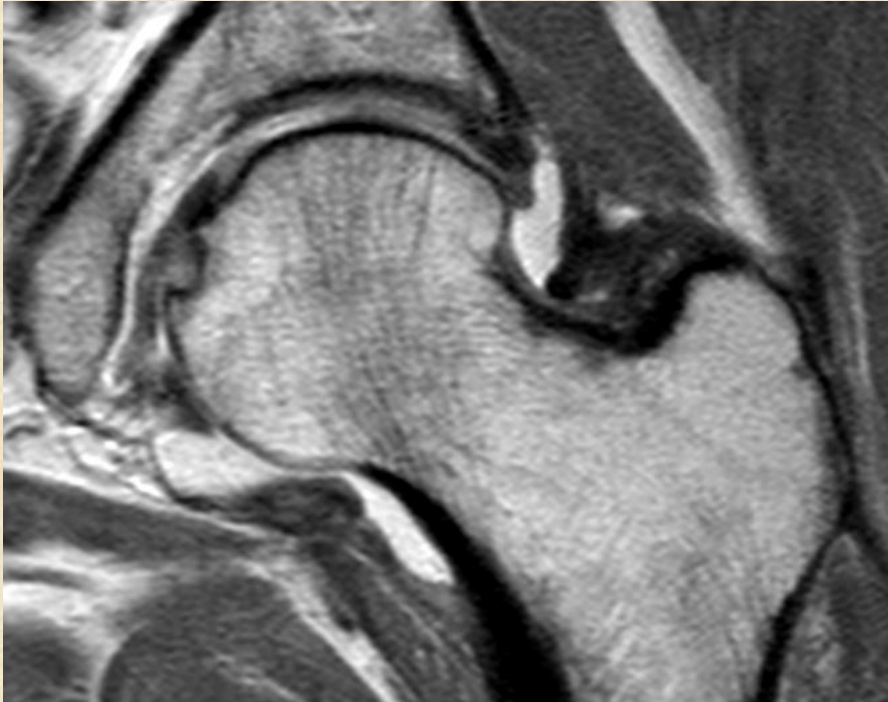


Pre-Traction

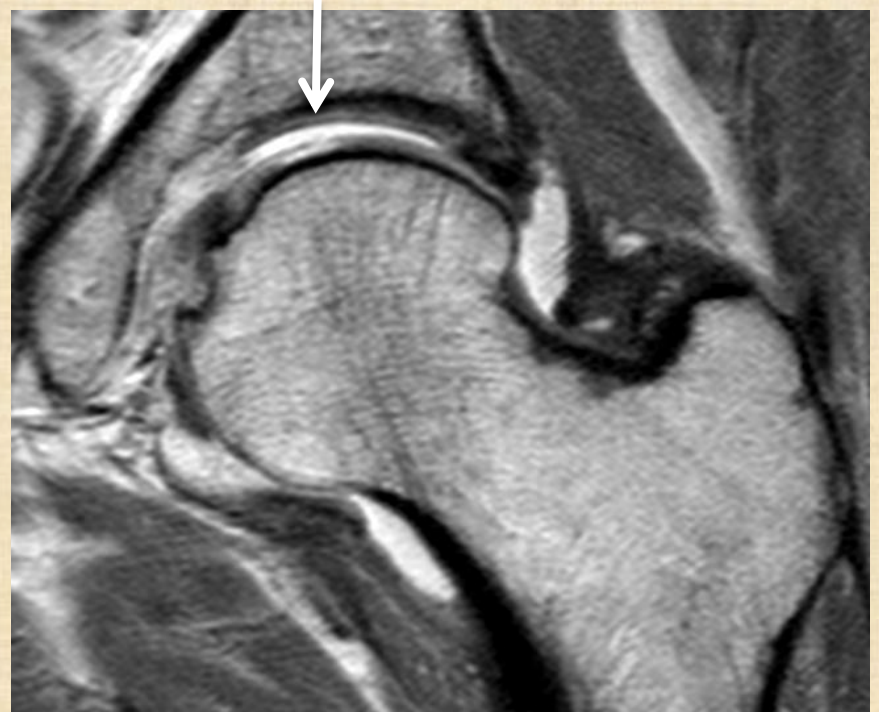


Post-Traction

Better cartilage defect visibility

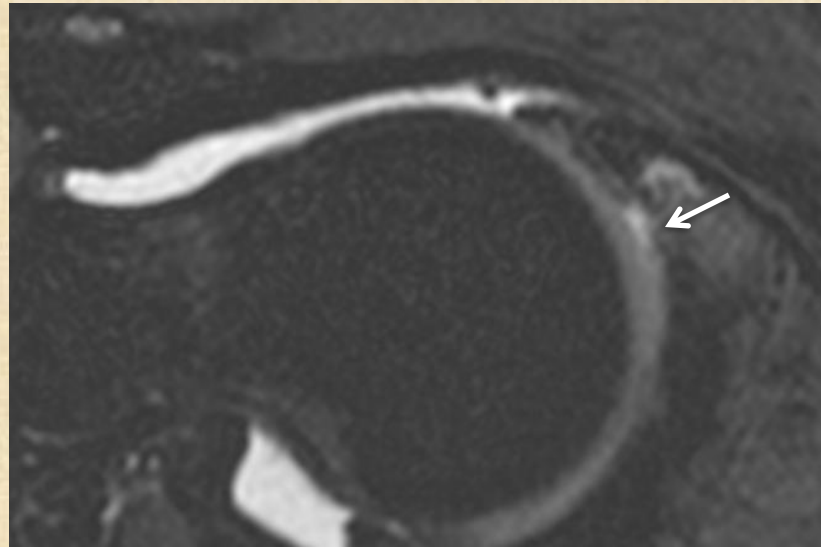
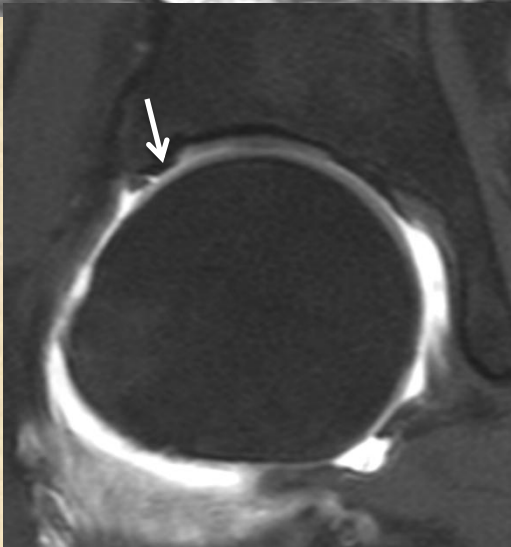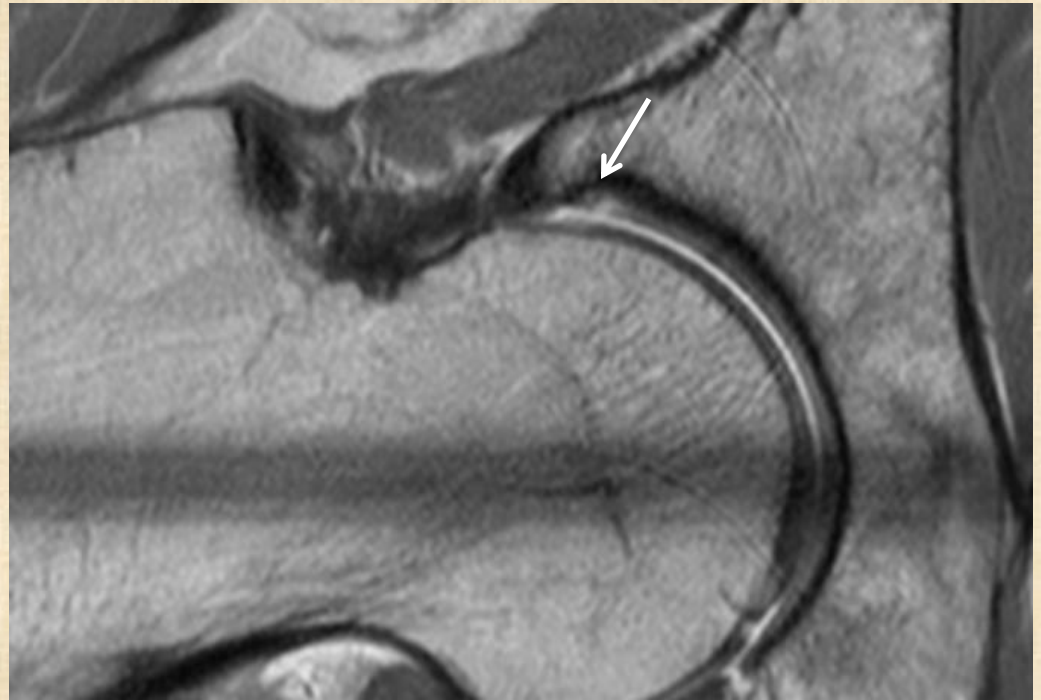
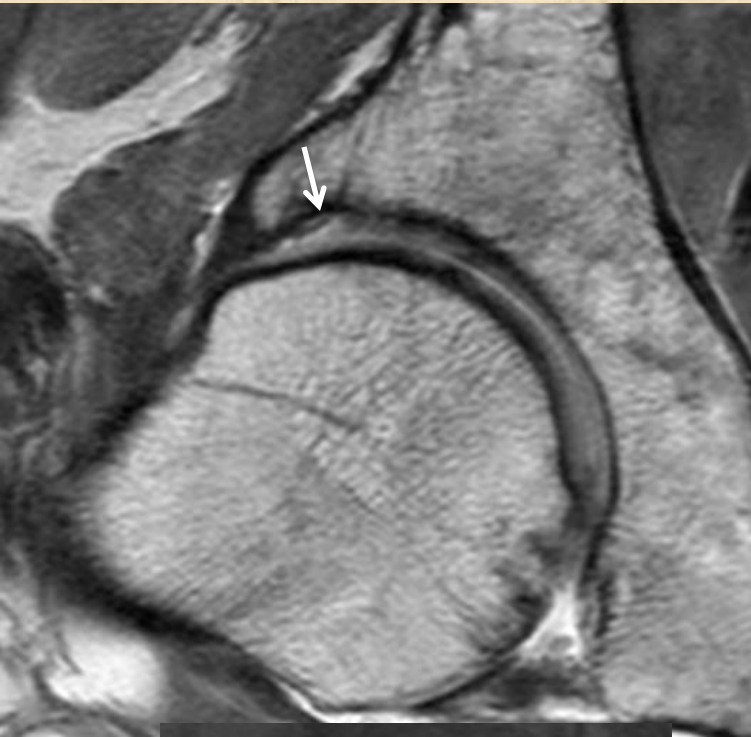


Pre-Traction

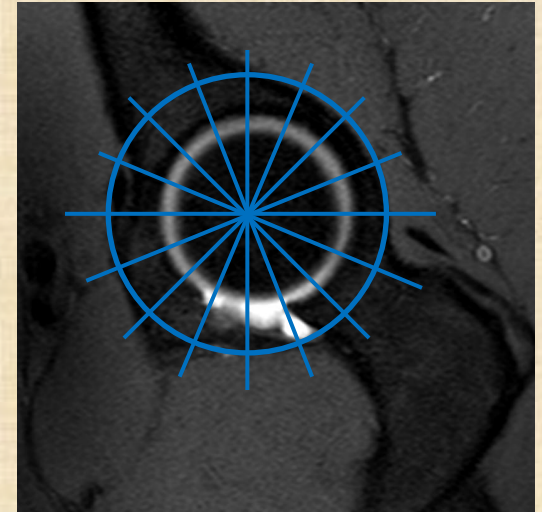
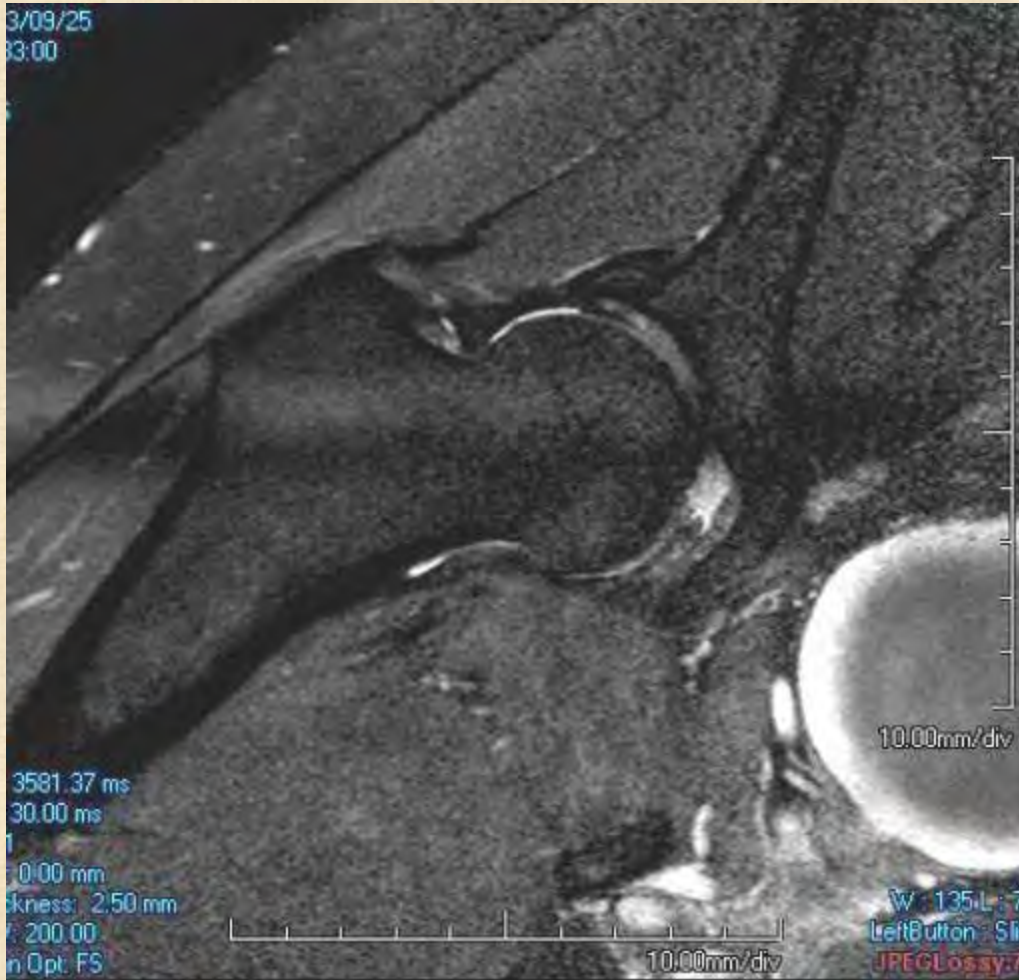


Post-Traction

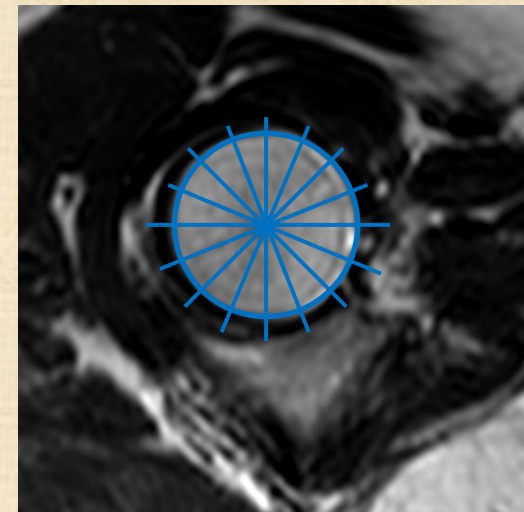
Chondral delamination



Radial scan or 3D scan ?



Along acetabulum axis



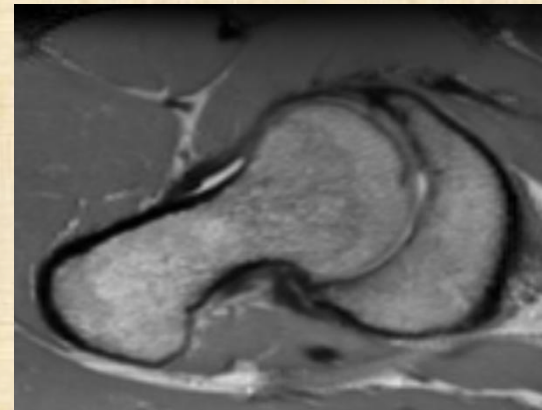
Along femoral head neck axis

Radial scan

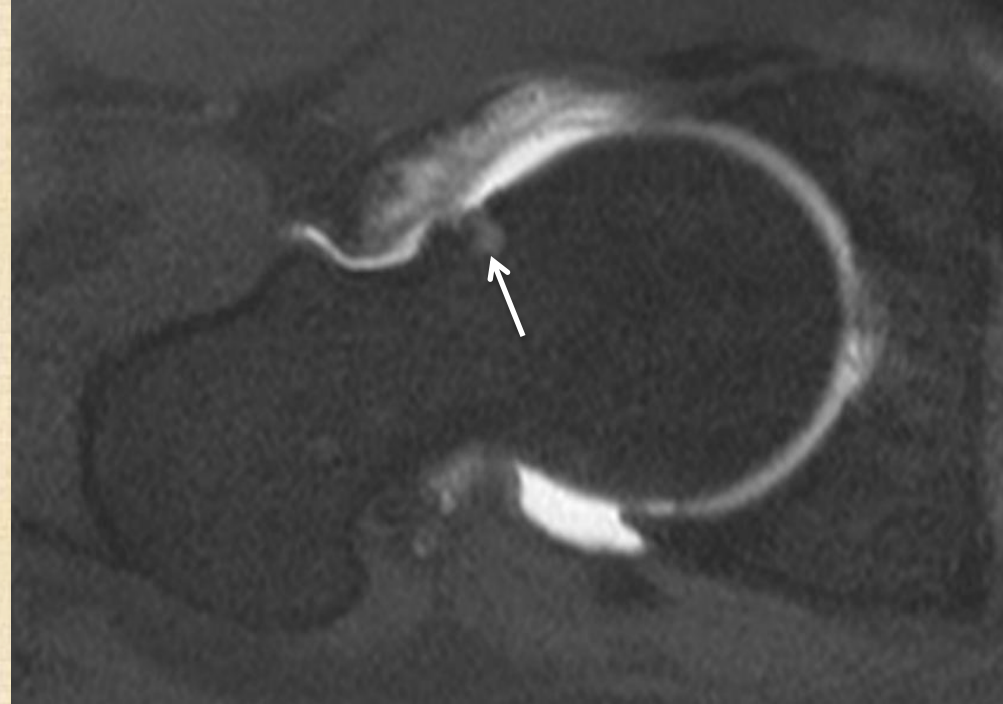
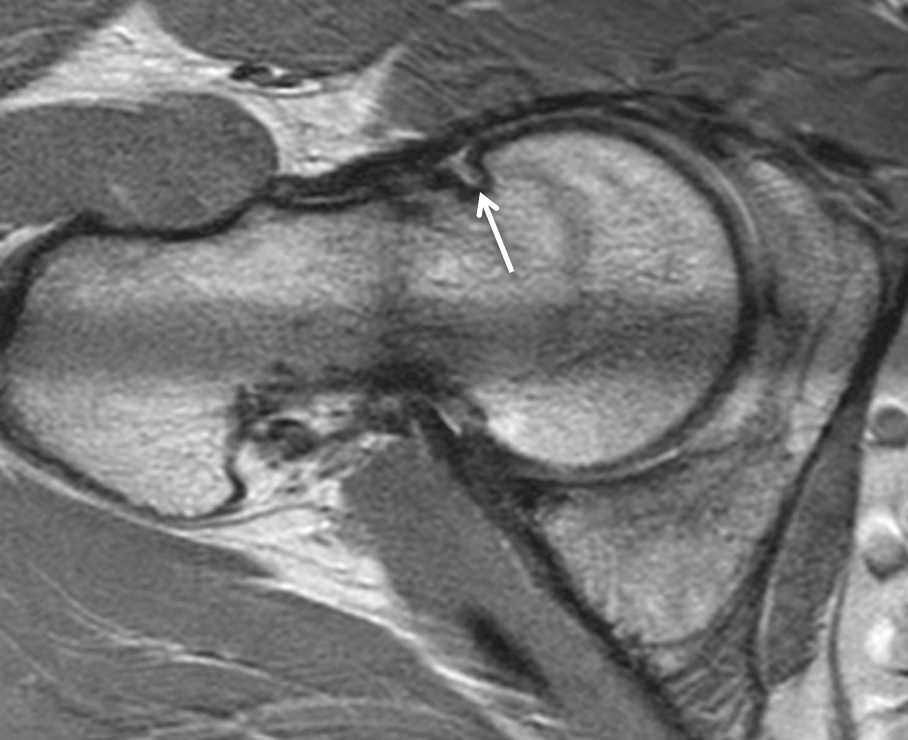


Better labral, labrochondral junction and cartilage visibility

3d VISTA

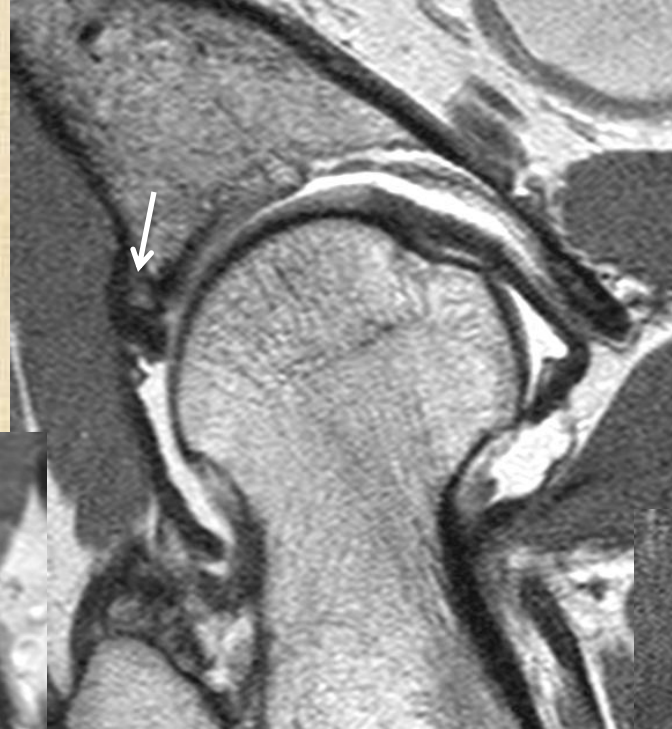

Herniation pit

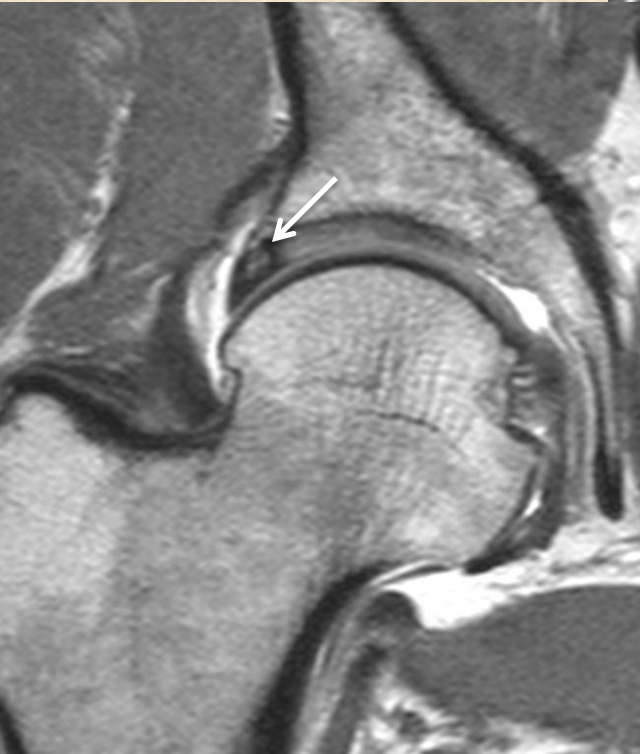


Os acetabuli (periacetabular ossicle)

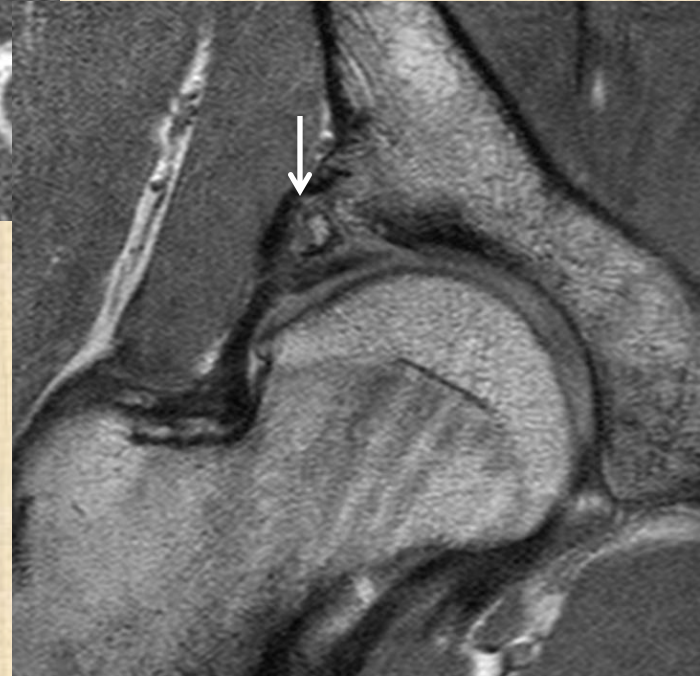
Within labrum



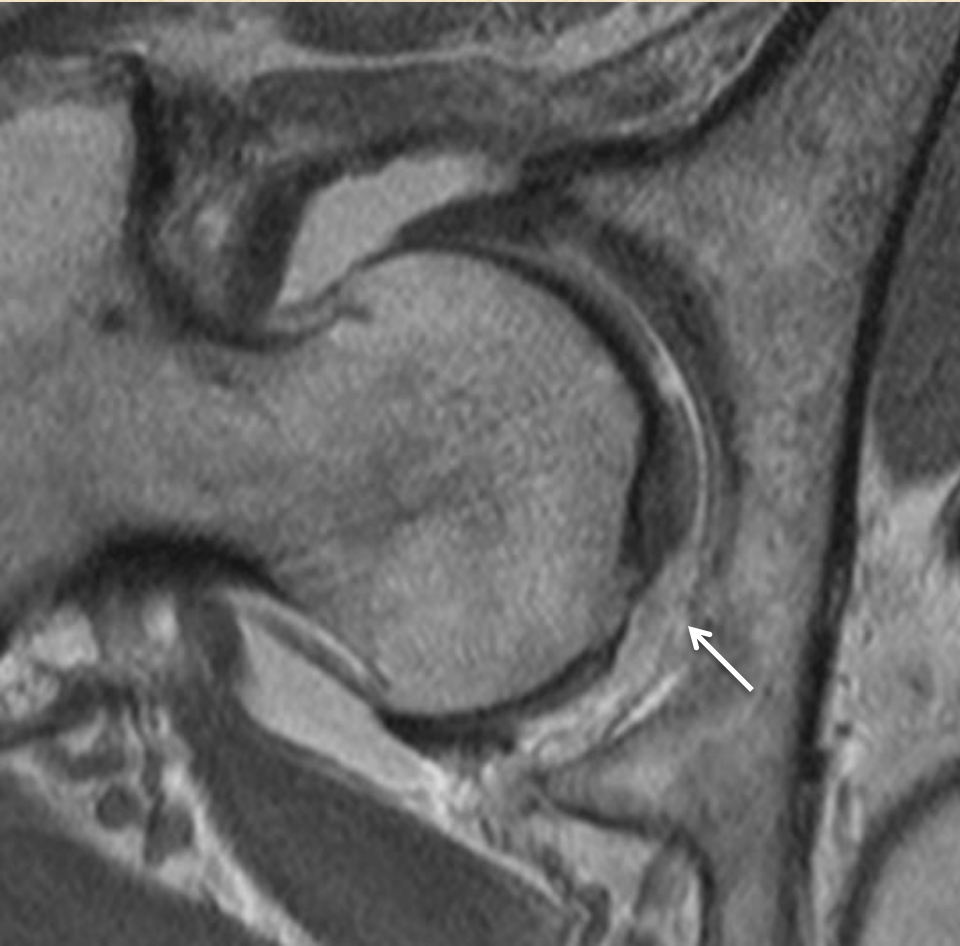
Fragmentation ?



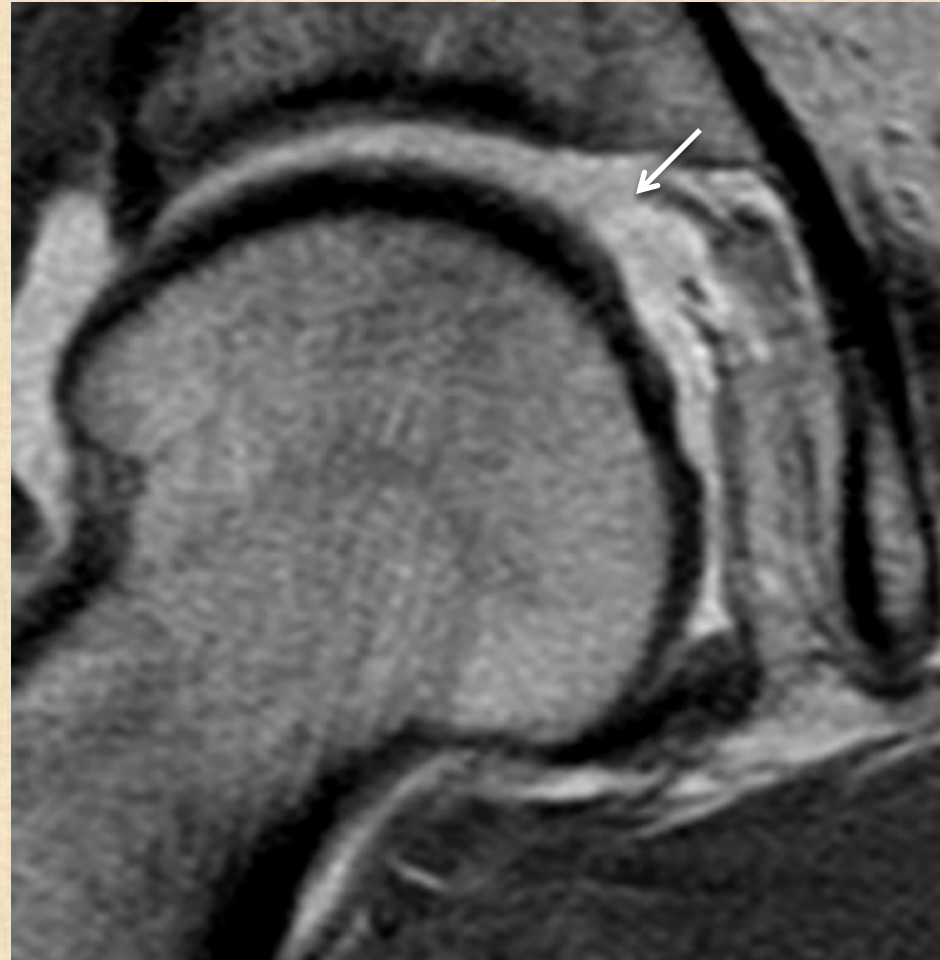
Above labrum



Ligamentum teres tear

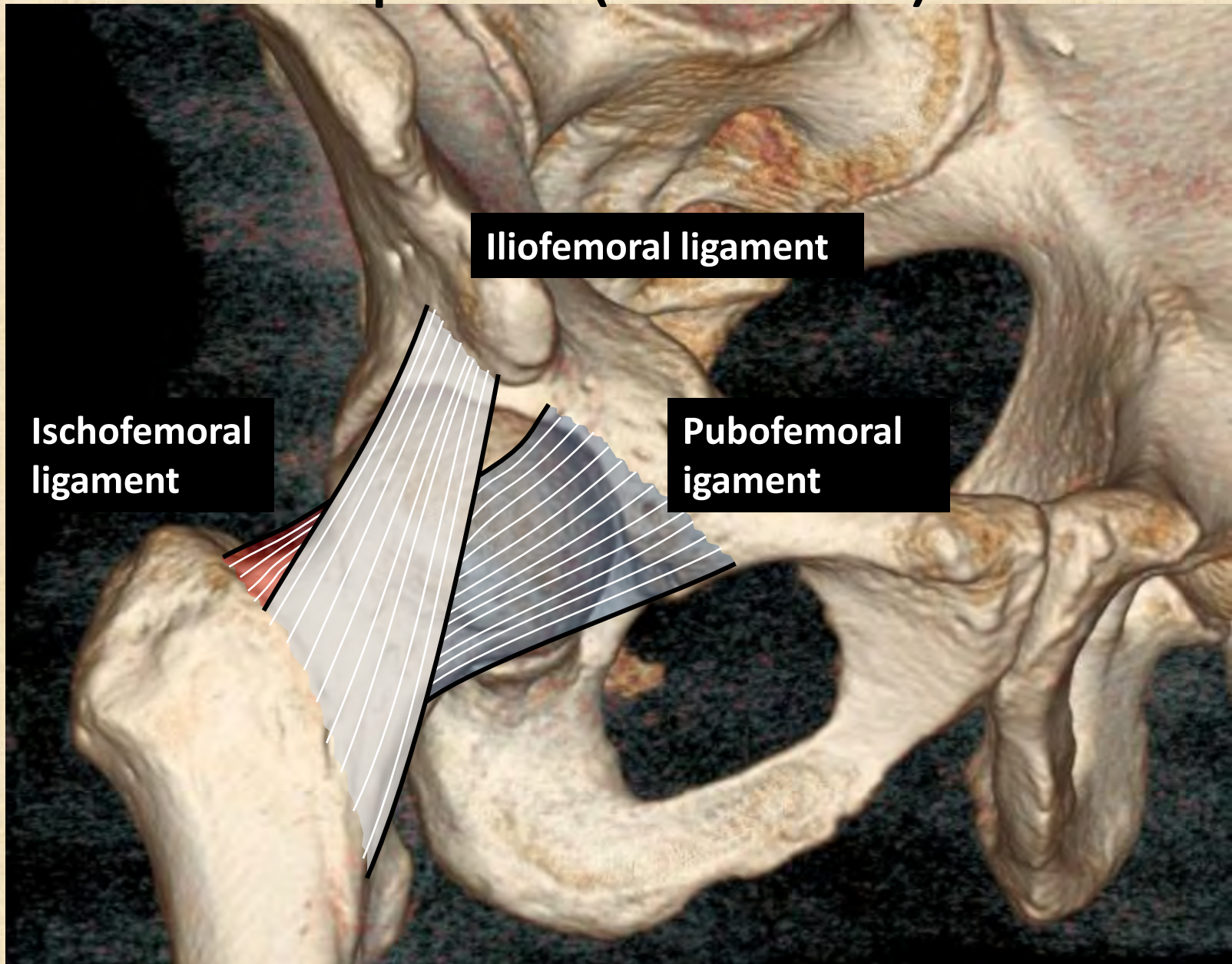


Partial tear

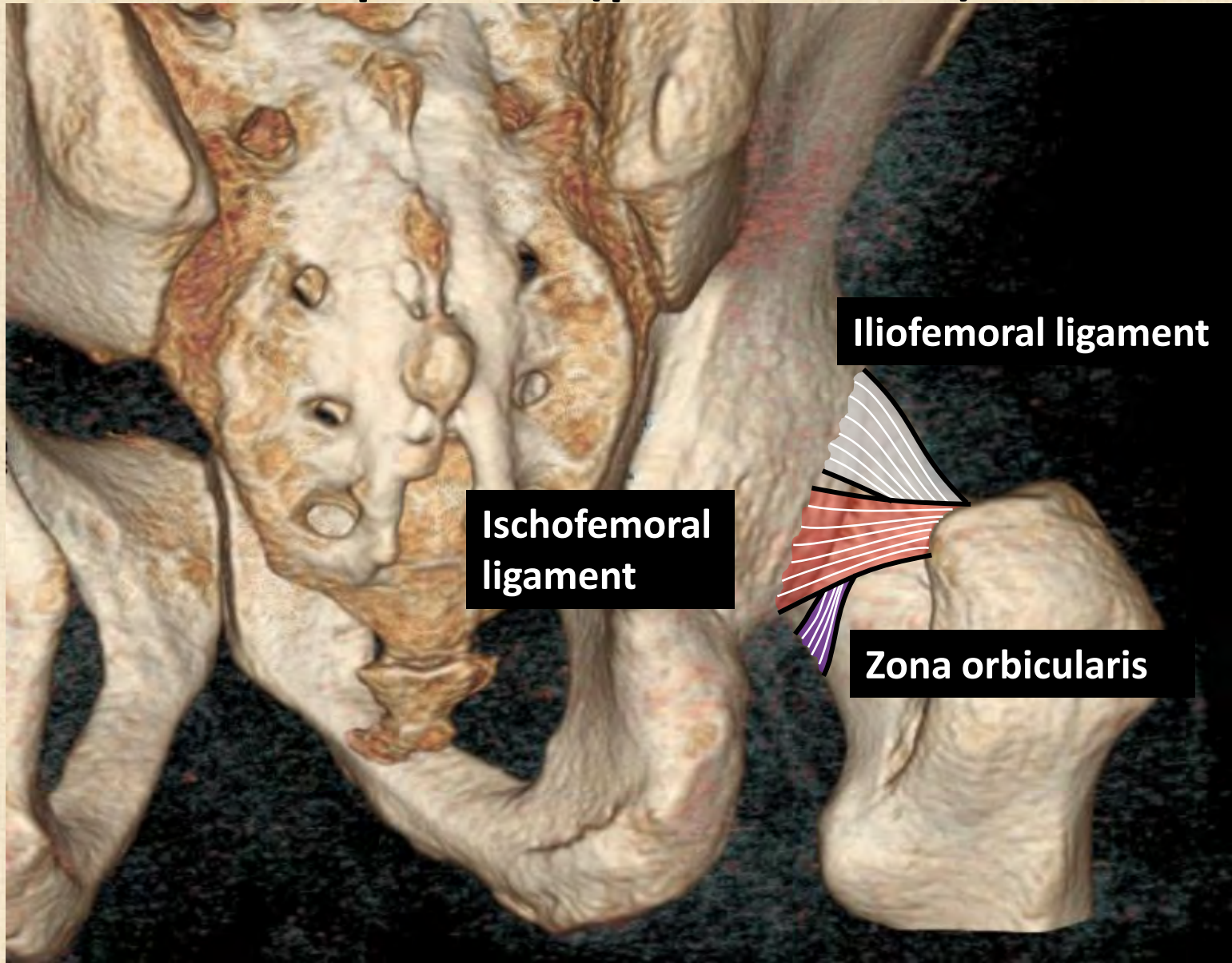


Complete tear

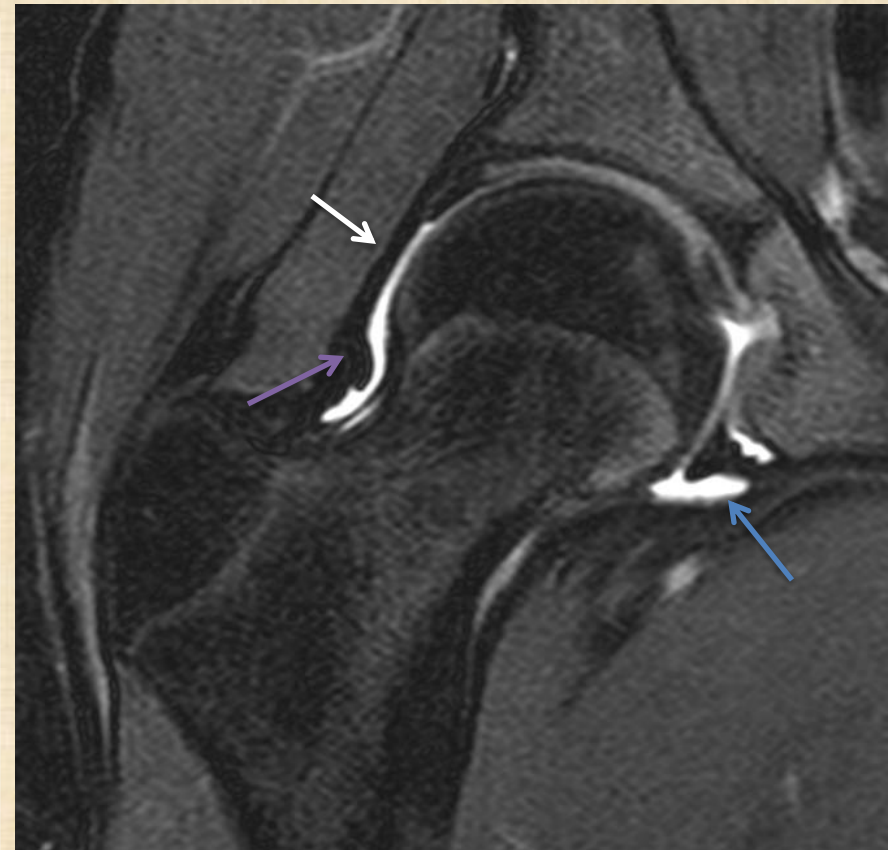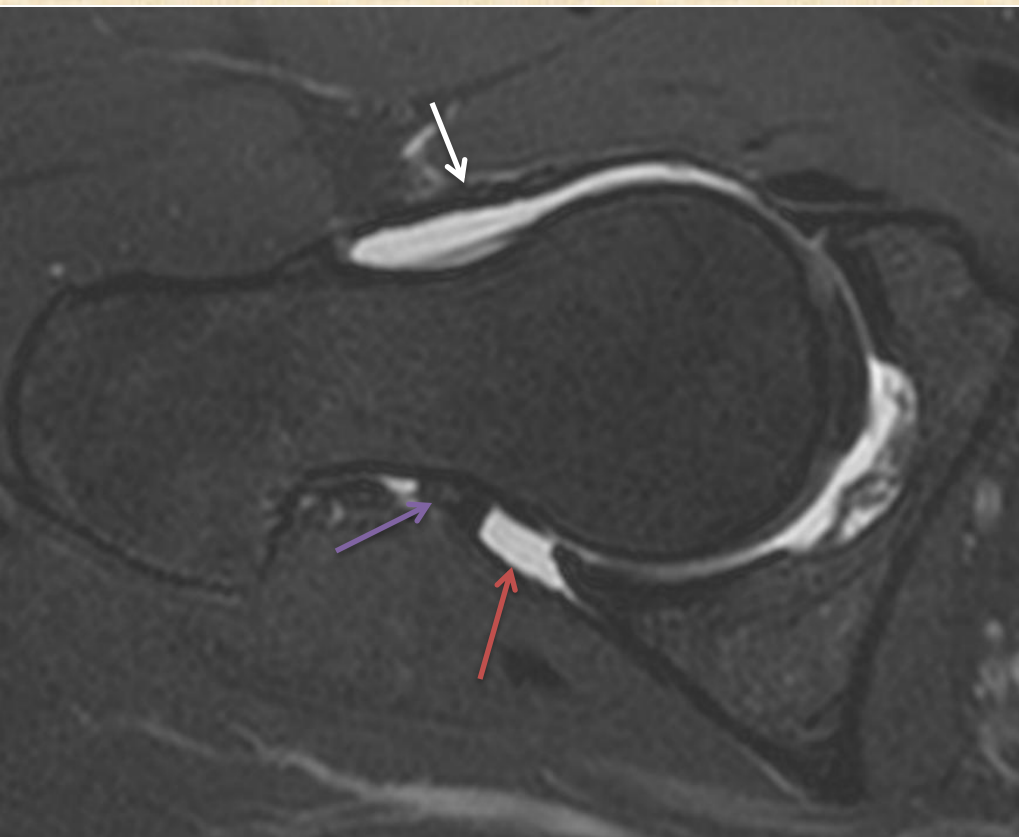
Capsule (anterior)



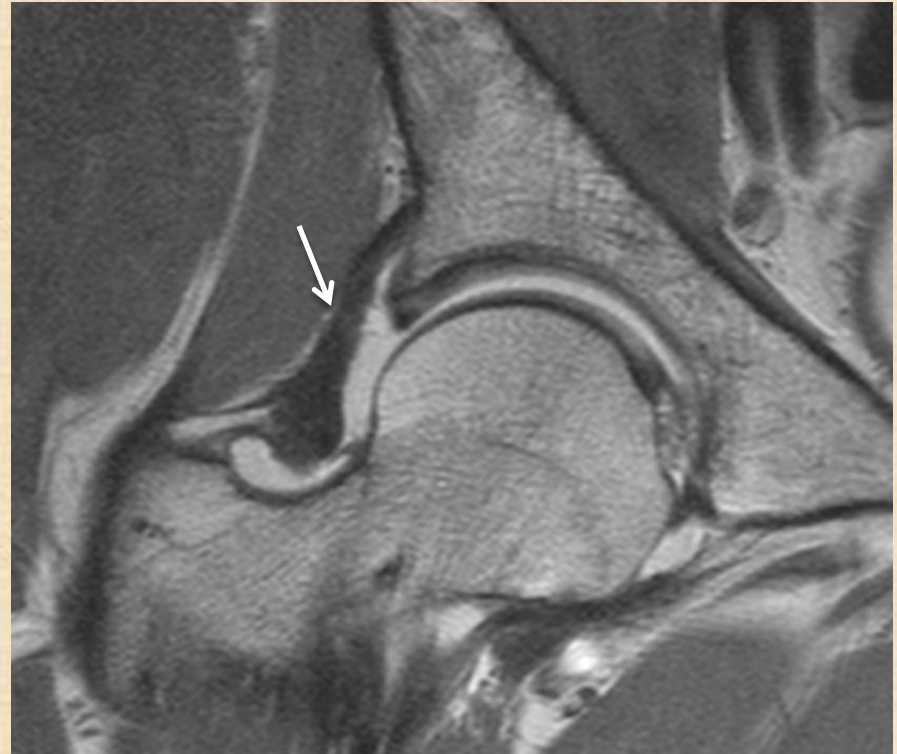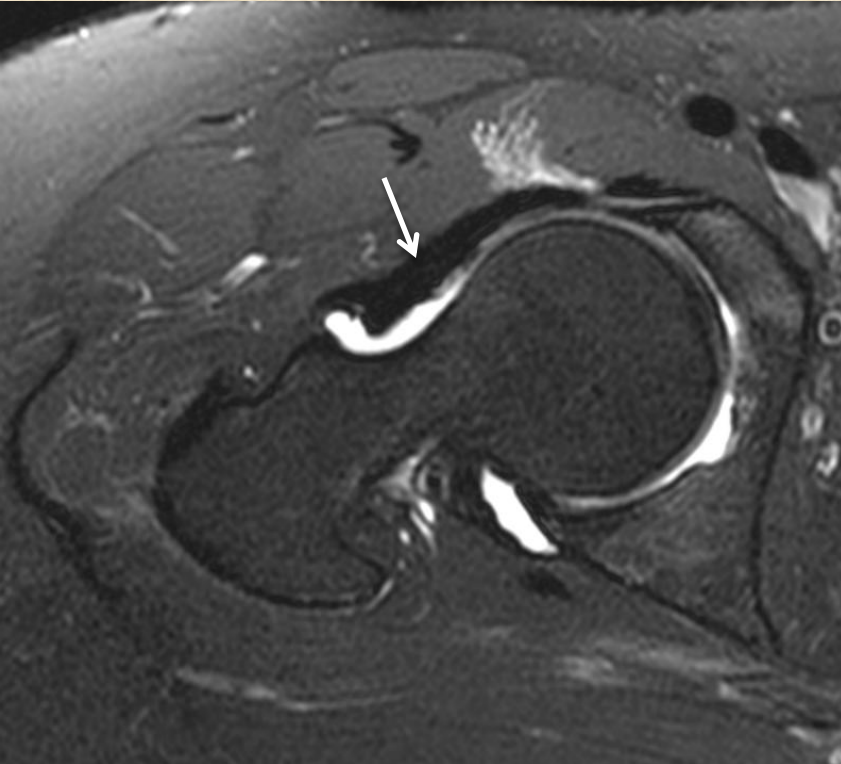
Capsule (posterior)



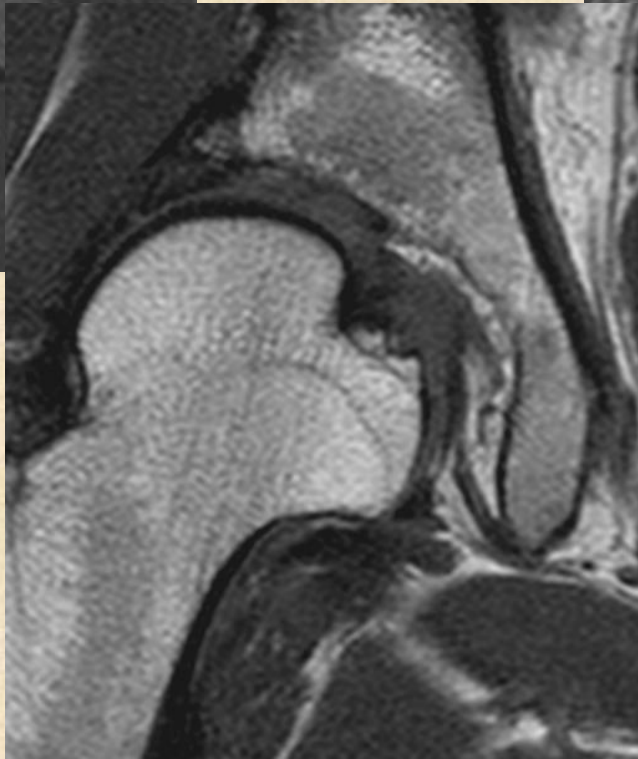
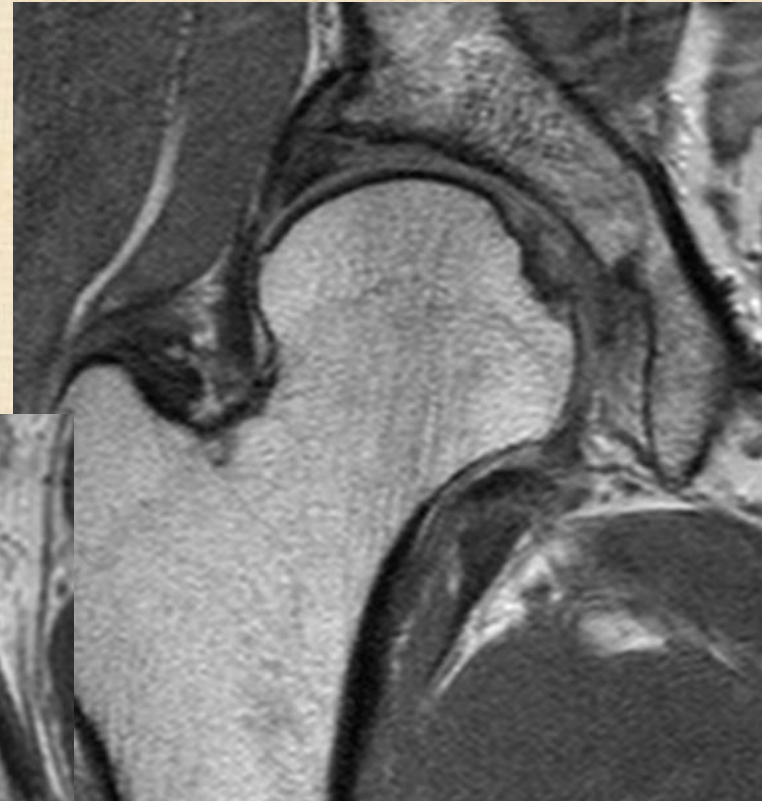
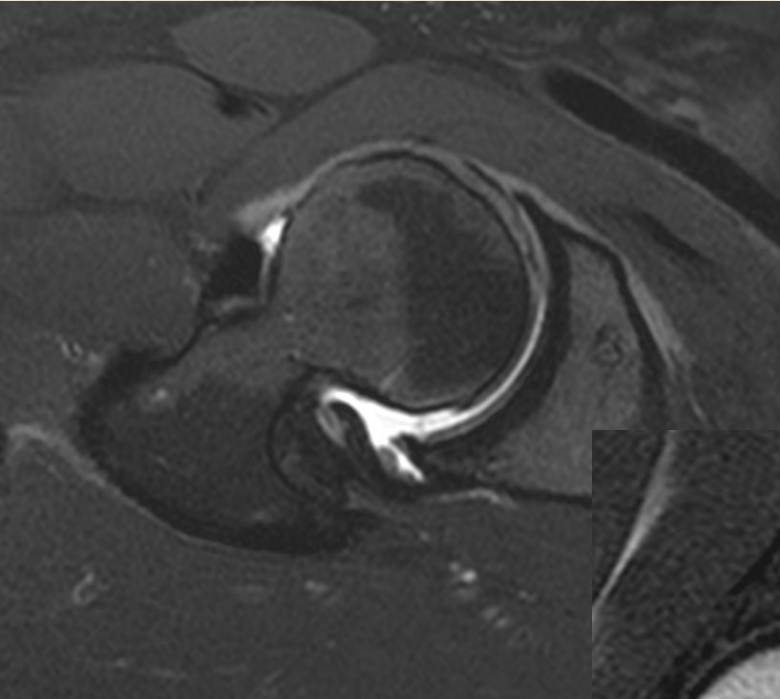
Normal capsular ligament



Capsular thickening and tear



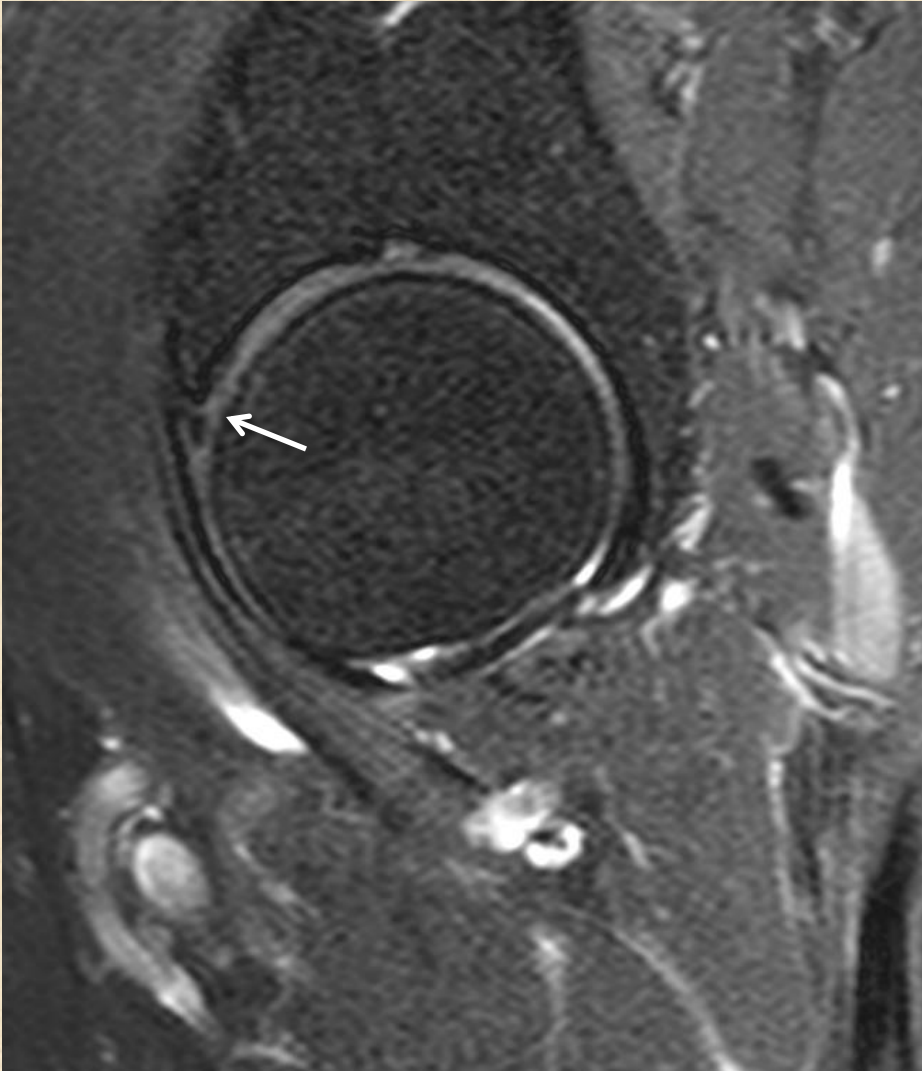
Dysplastic hip



Check list of hip arthrogram

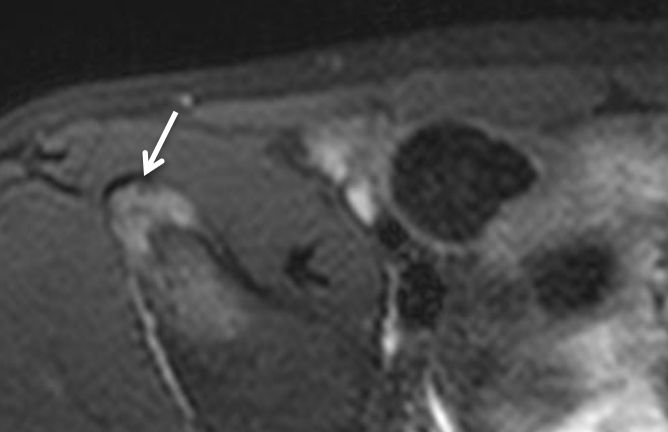
- Labrum
- Cartilage
- Chondrolabral junction
- Osseous abnormalities
 - Femur: osseous bump
 - Acetabulum: overcoverage, anter/retroversion
 - Dysplastic hip
- Capsular ligament (iliofemoral, pubofemoral, ischiofemoral, zona orbicularis)
- Ligamentum teres

Iliopsoa impingement

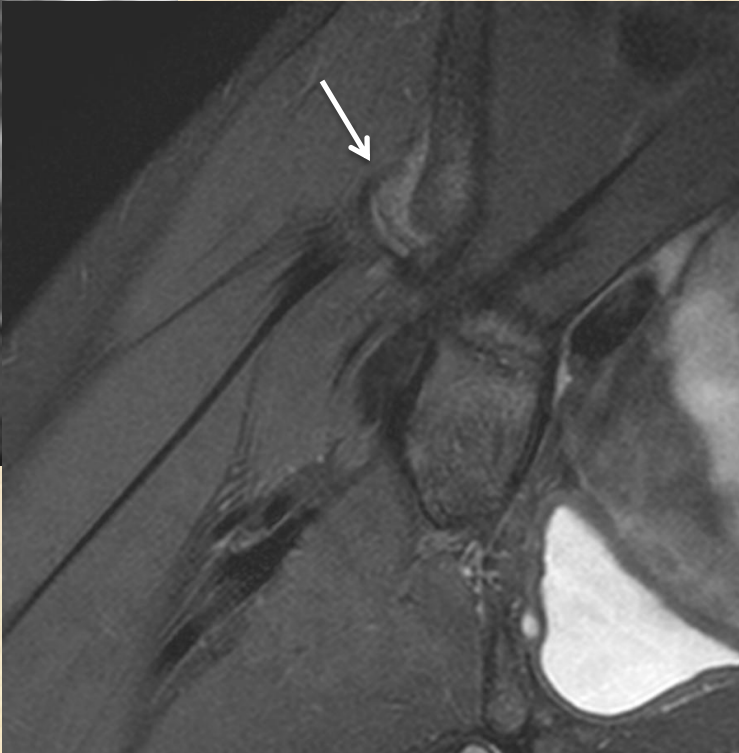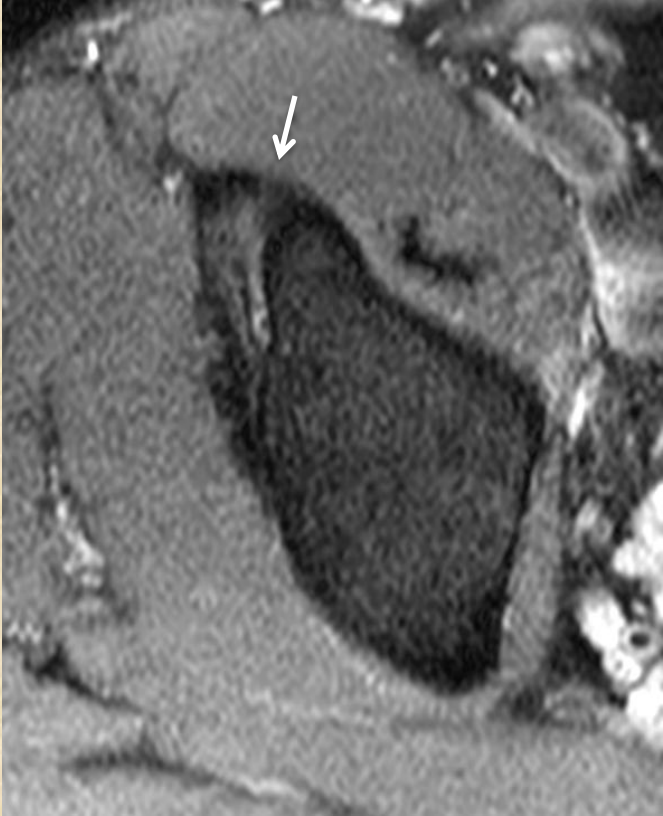


**Isolate tear at 3
o'clock : consider
this diagnosis**

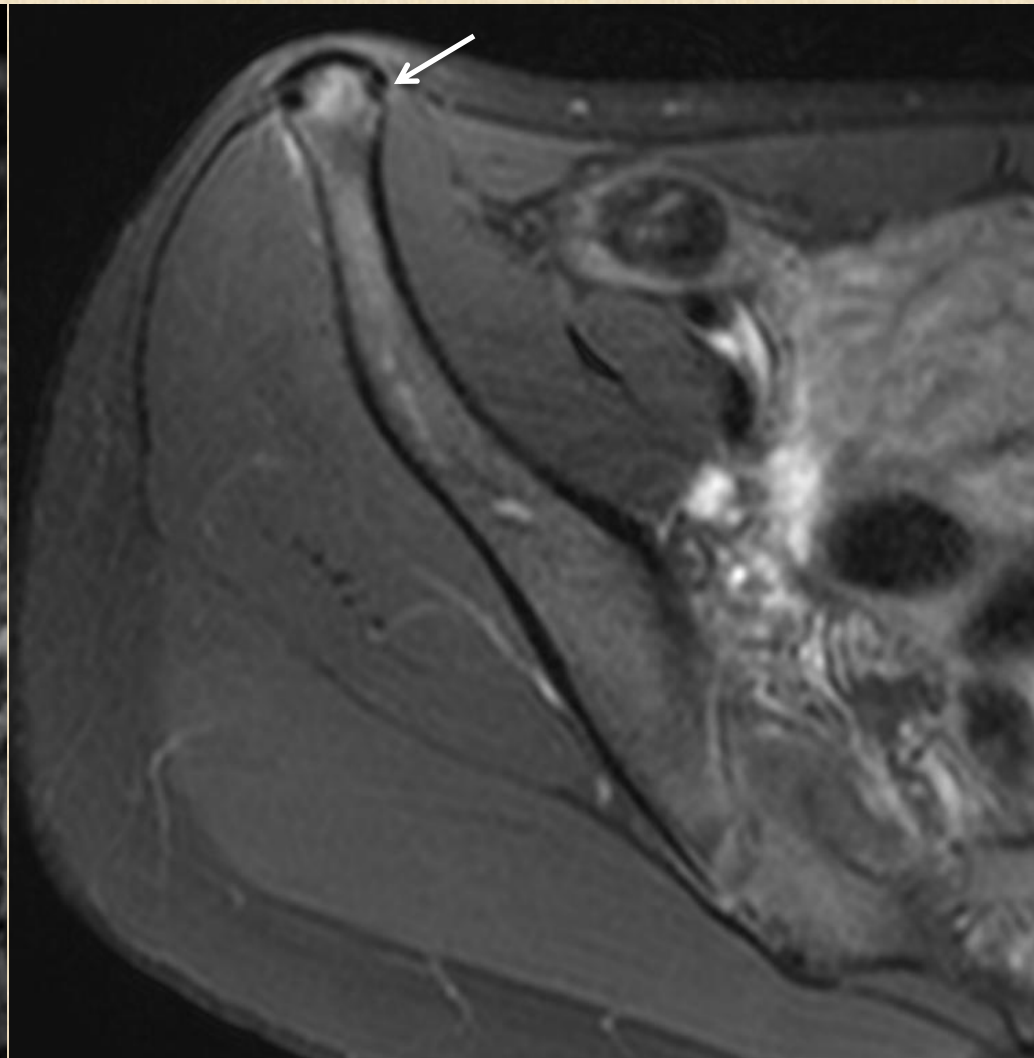
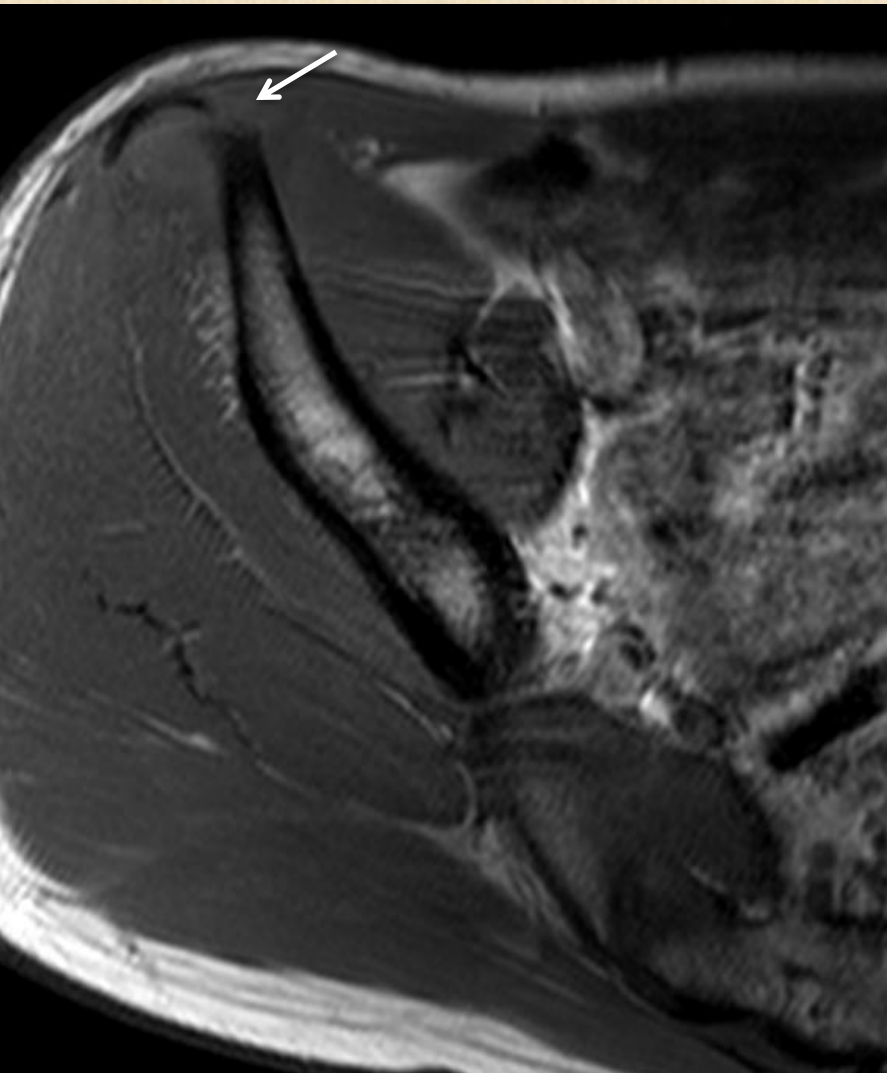
AIIS avulsion – subspine impingement



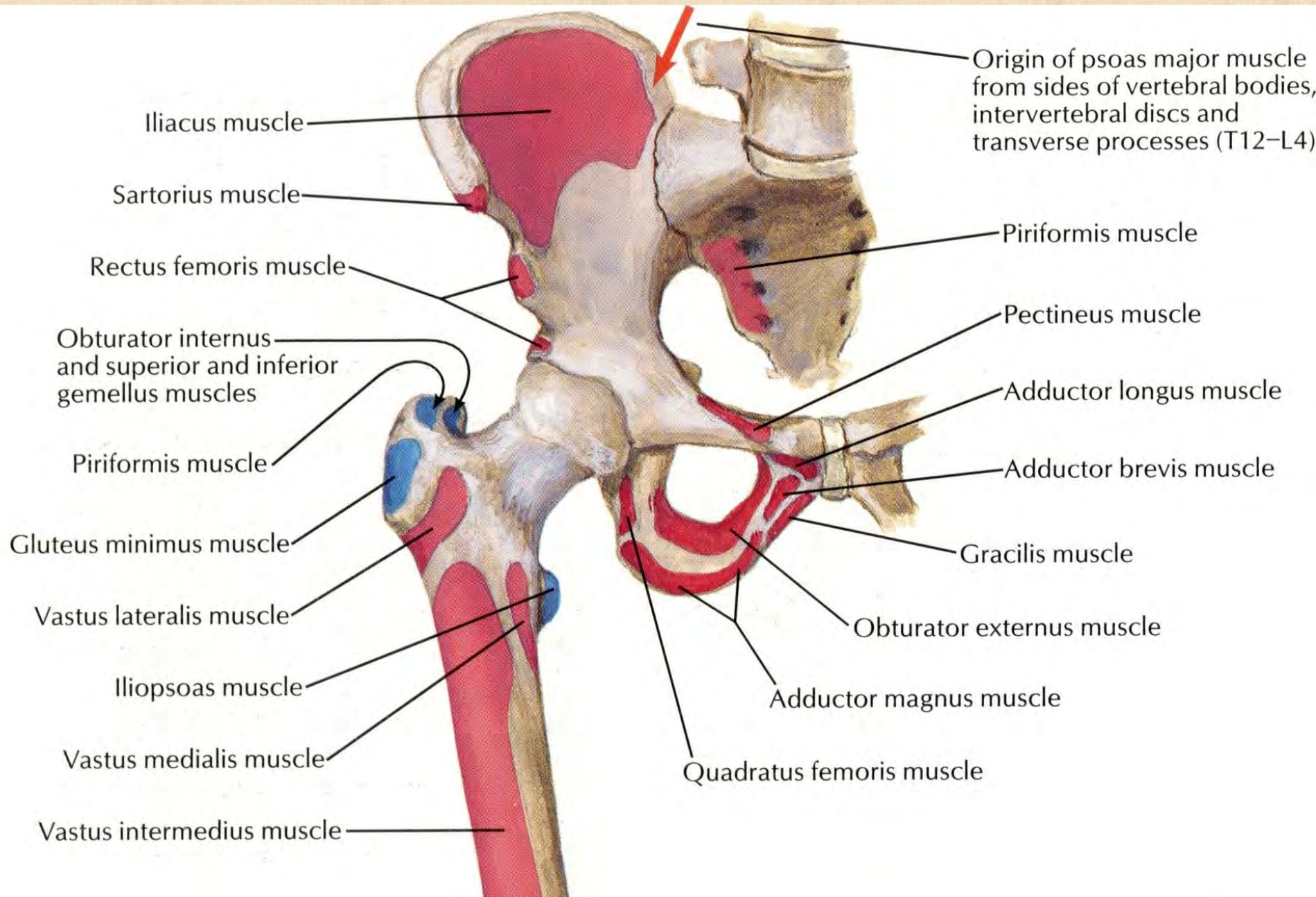
Attachment of rectus femoris

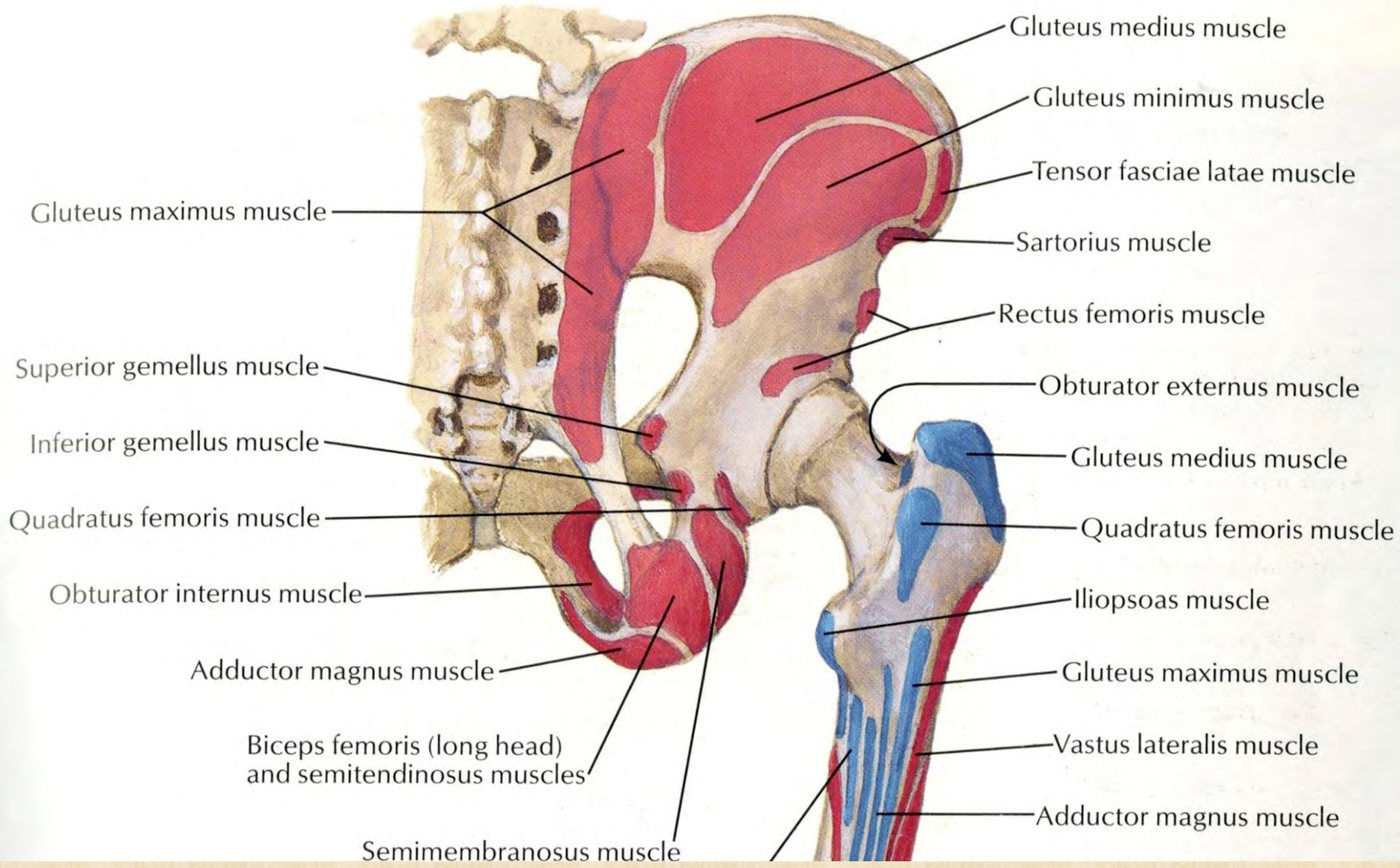


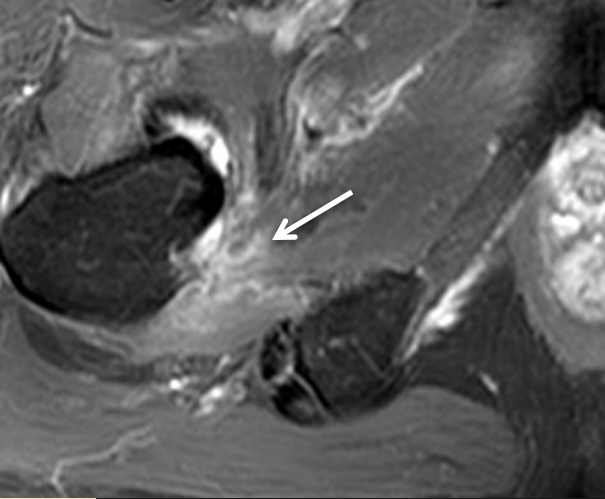
ASIS avulsion



Attachment of sartorius and inguinal ligament

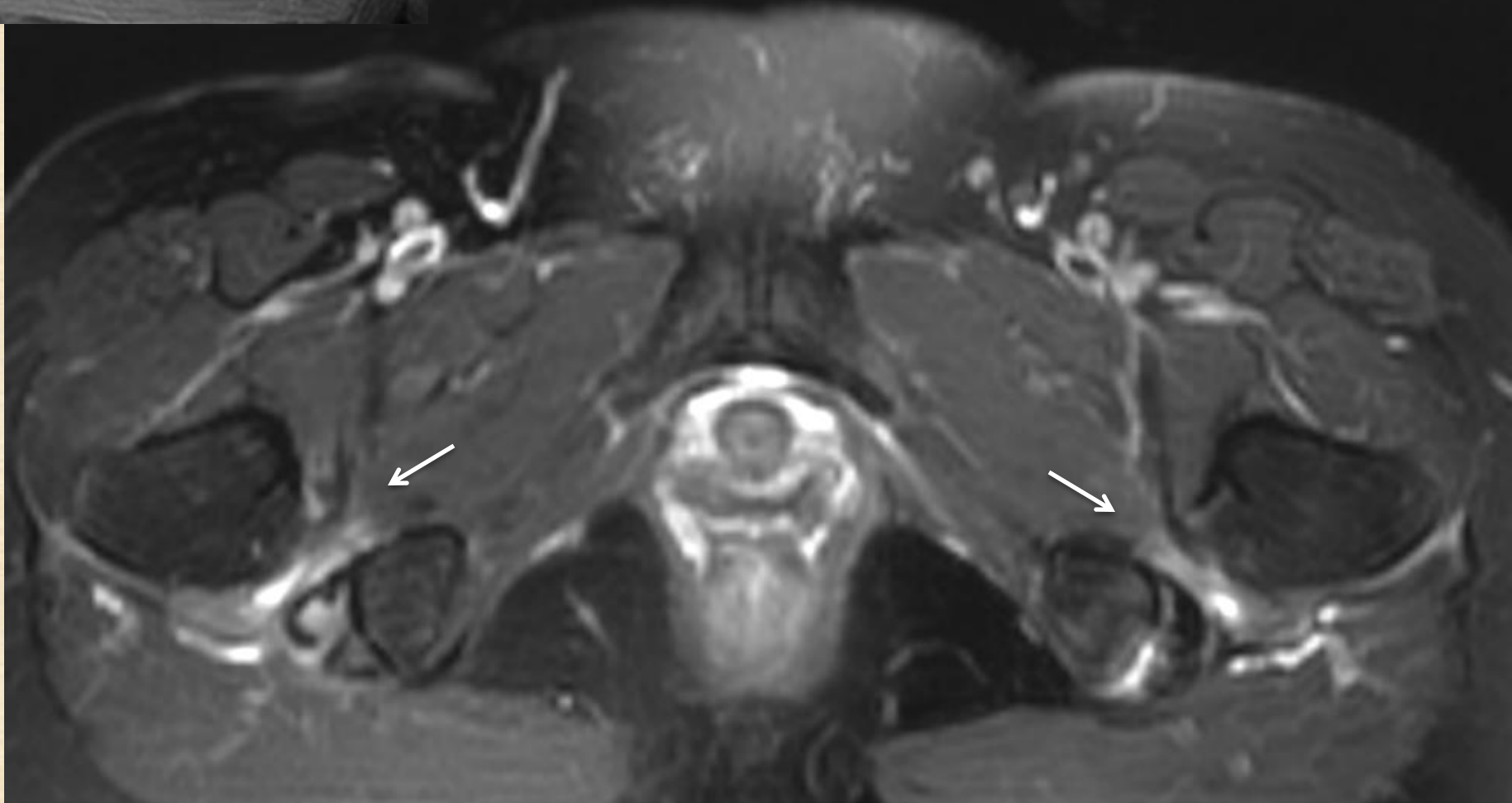




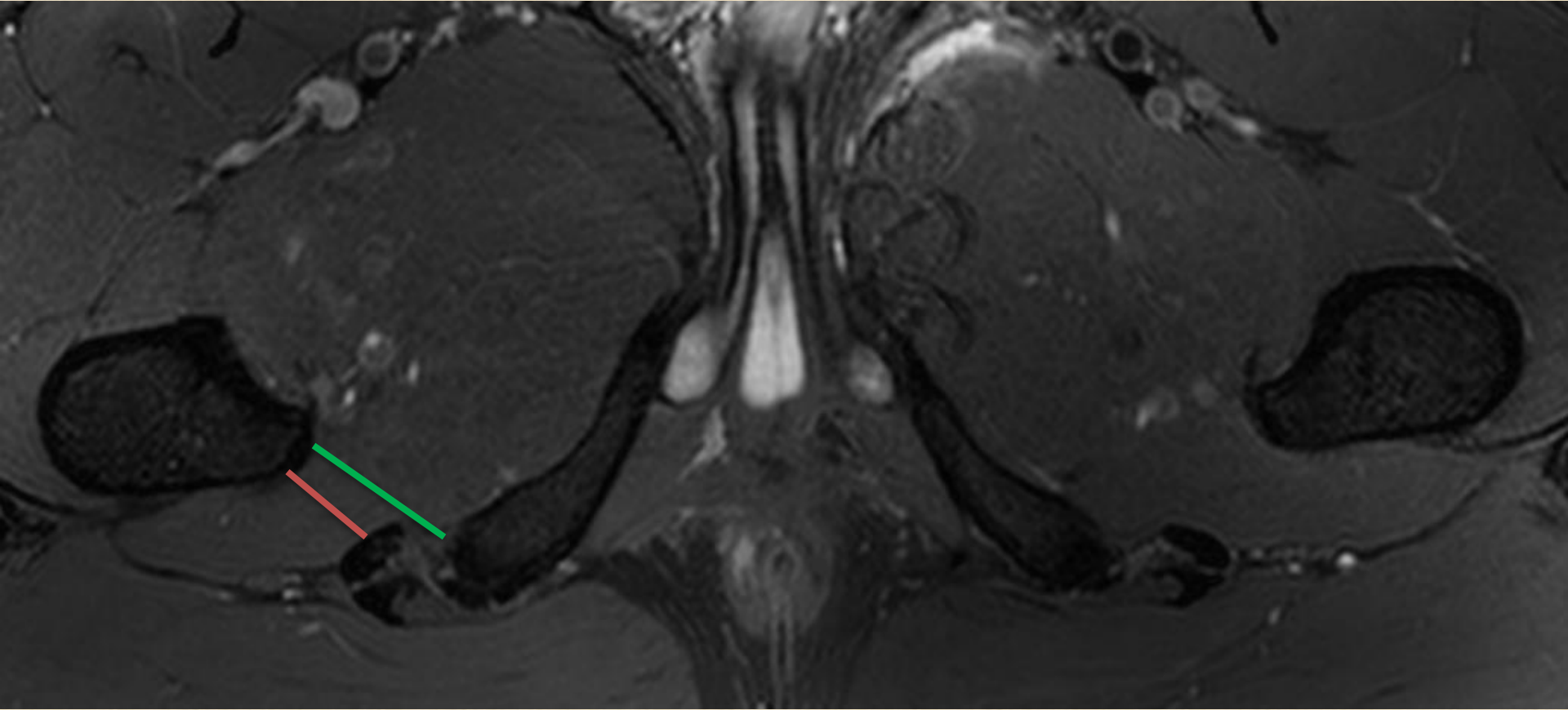


Ischiofemoral impingement

Edema, cystic change, fatty atrophy of quadratus femoris muscle



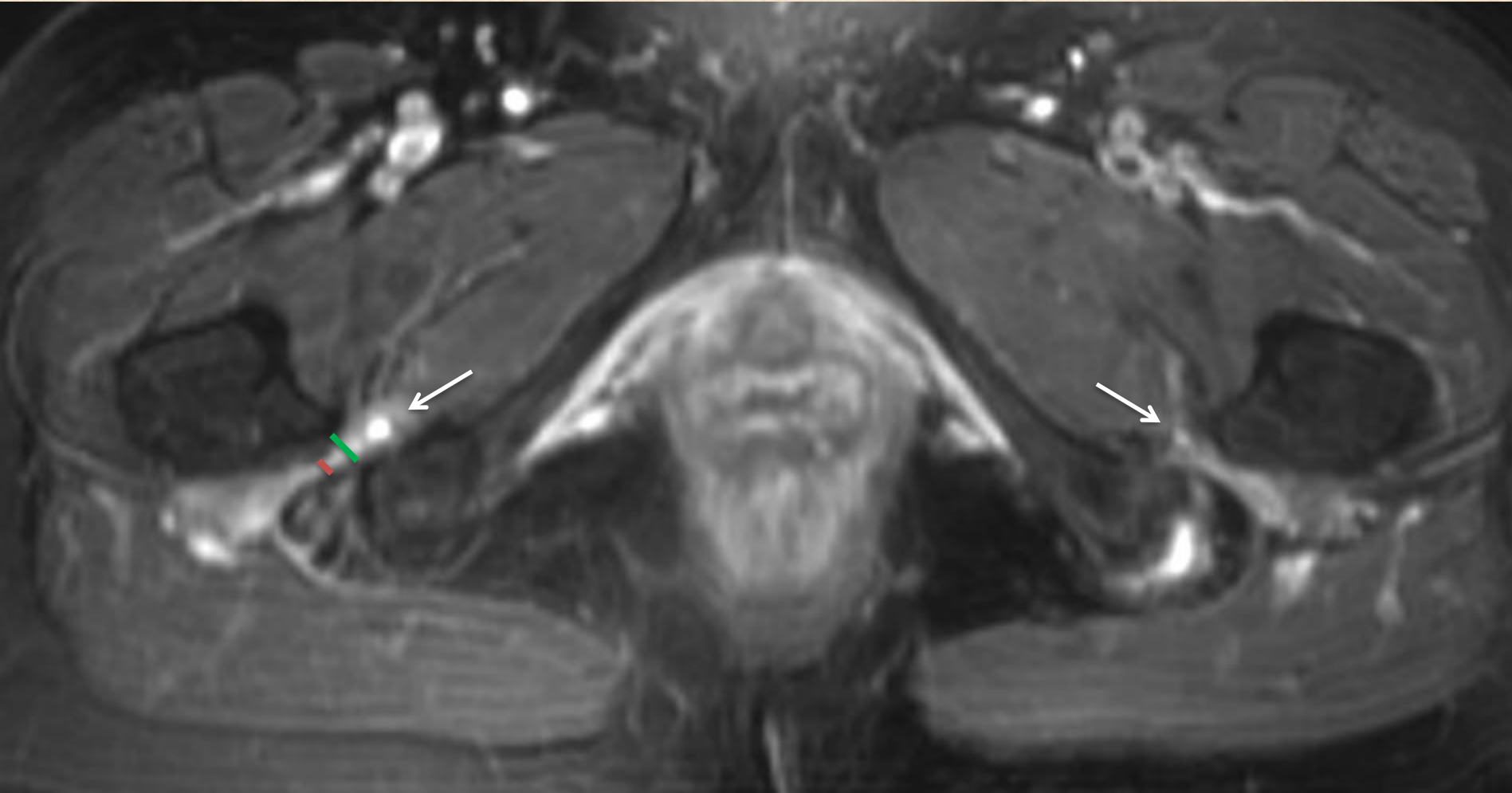
Normal



Ischiofemoral space (between ischium and lesser trochanter) : <15mm

Quadratus femoris space (between ischium and lesser trochanter) : <10mm

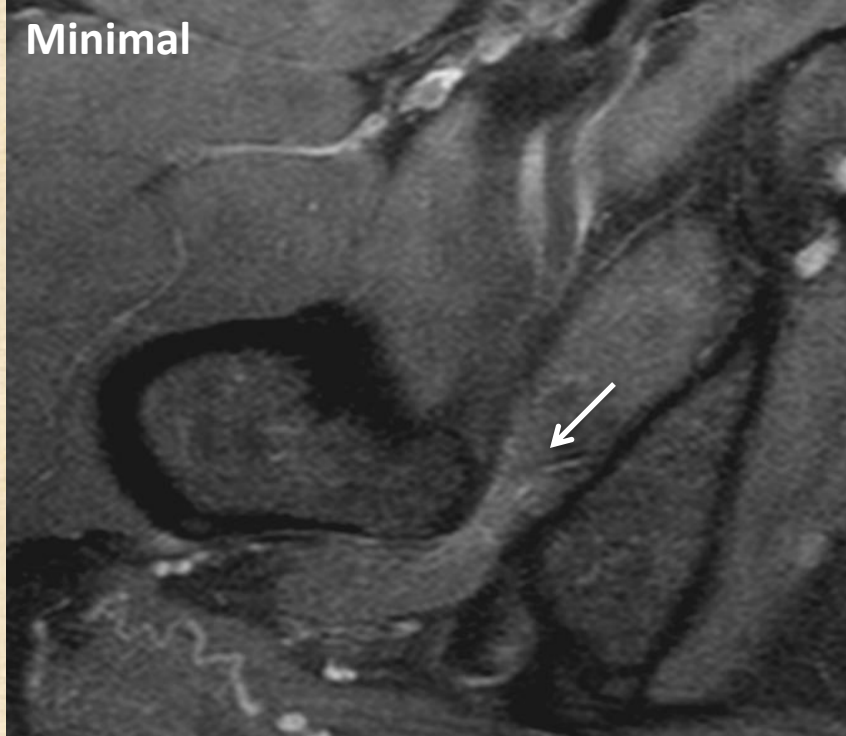
Ischiofemoral impingement



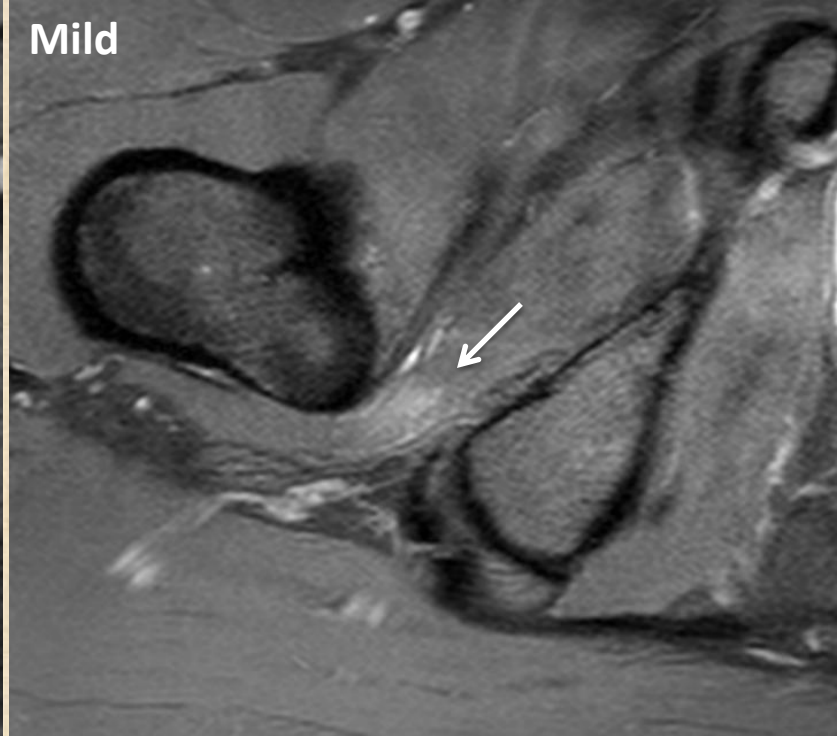
Ischiofemoral space (between ischium and lesser trochanter) : <15mm

Quadratus femoris space (between ischium and lesser trochanter) : <10mm

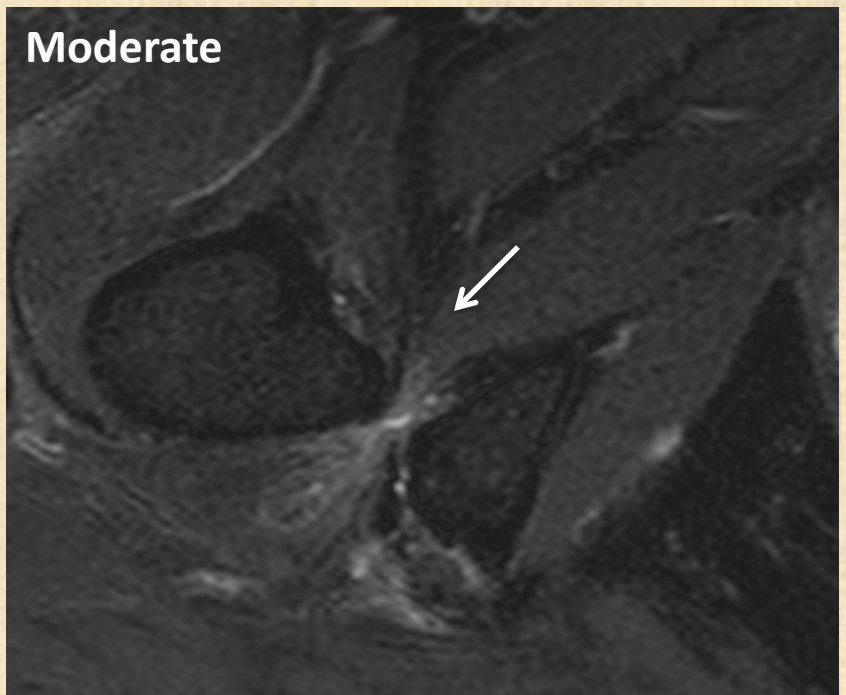
Minimal



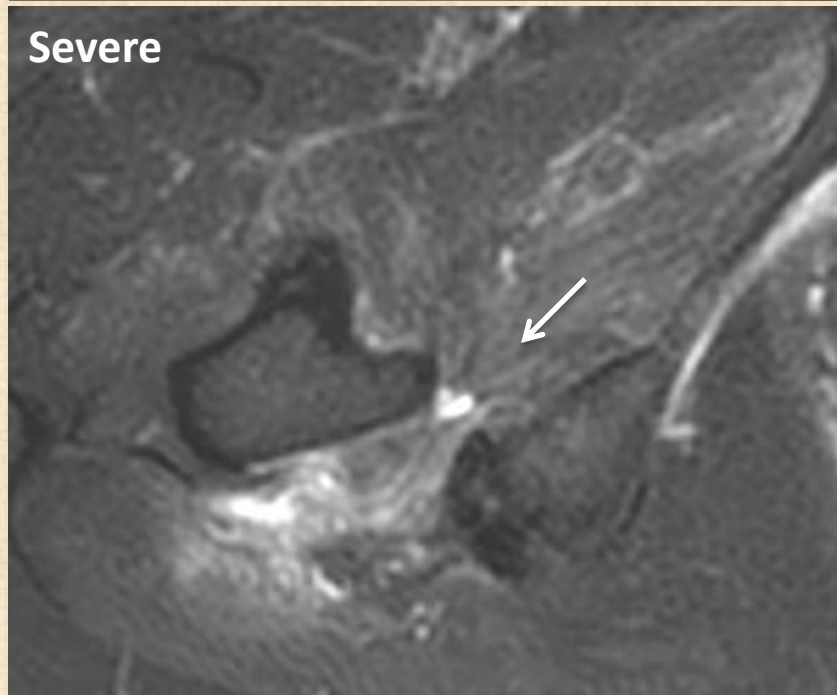
Mild



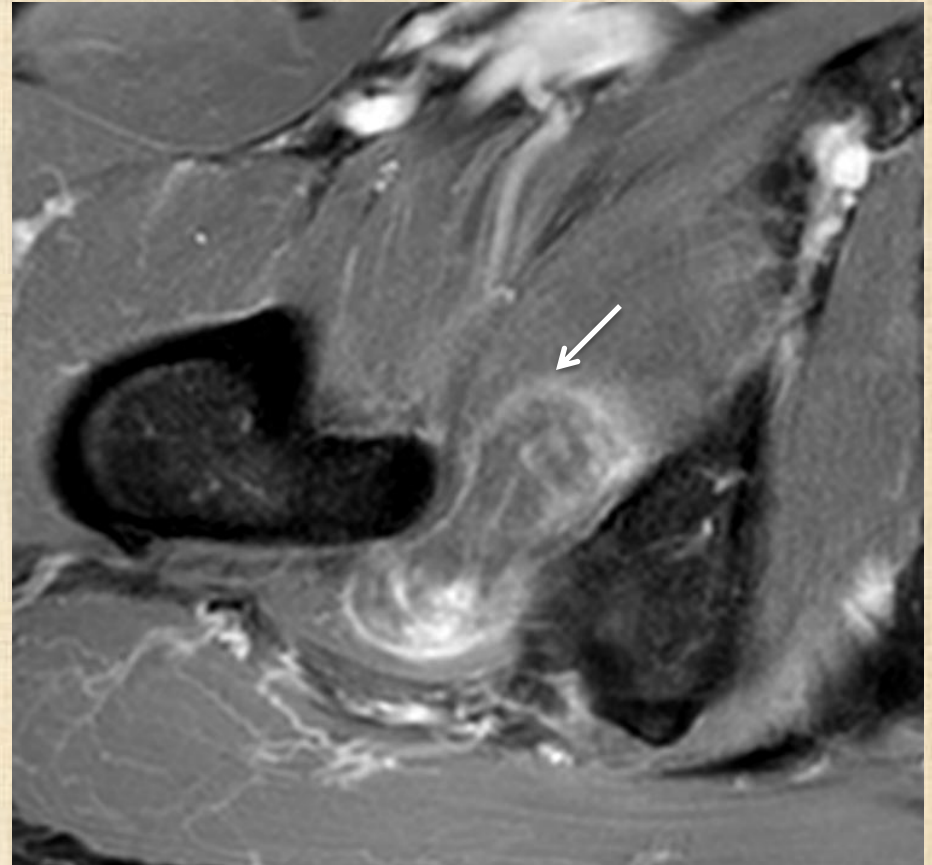
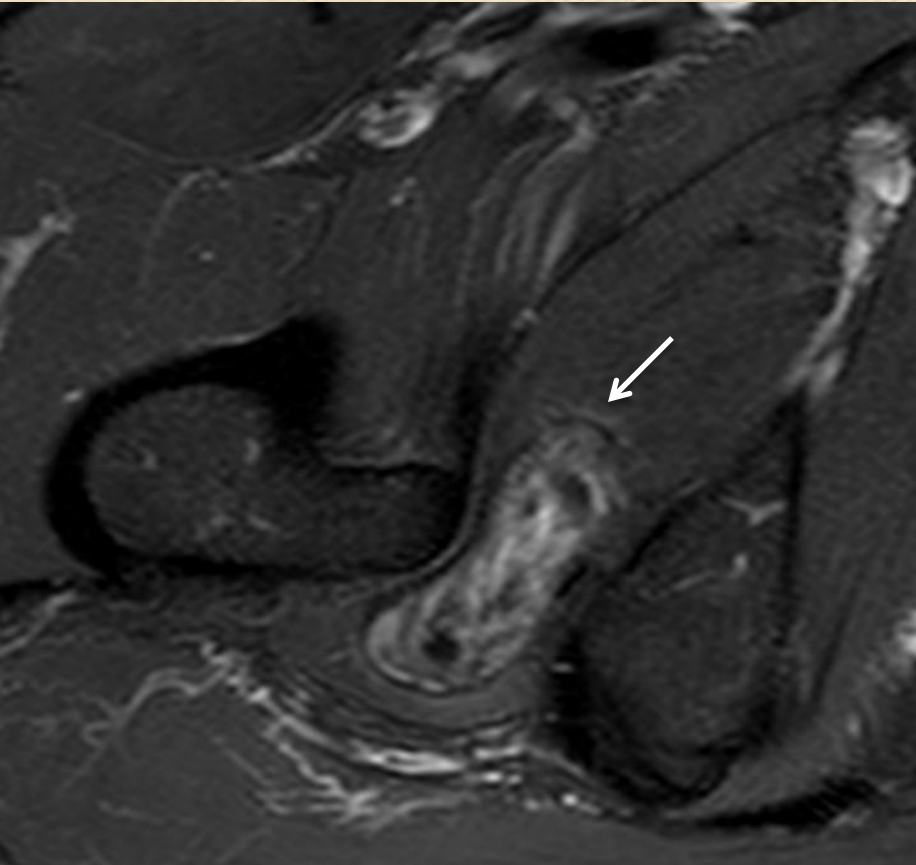
Moderate



Severe



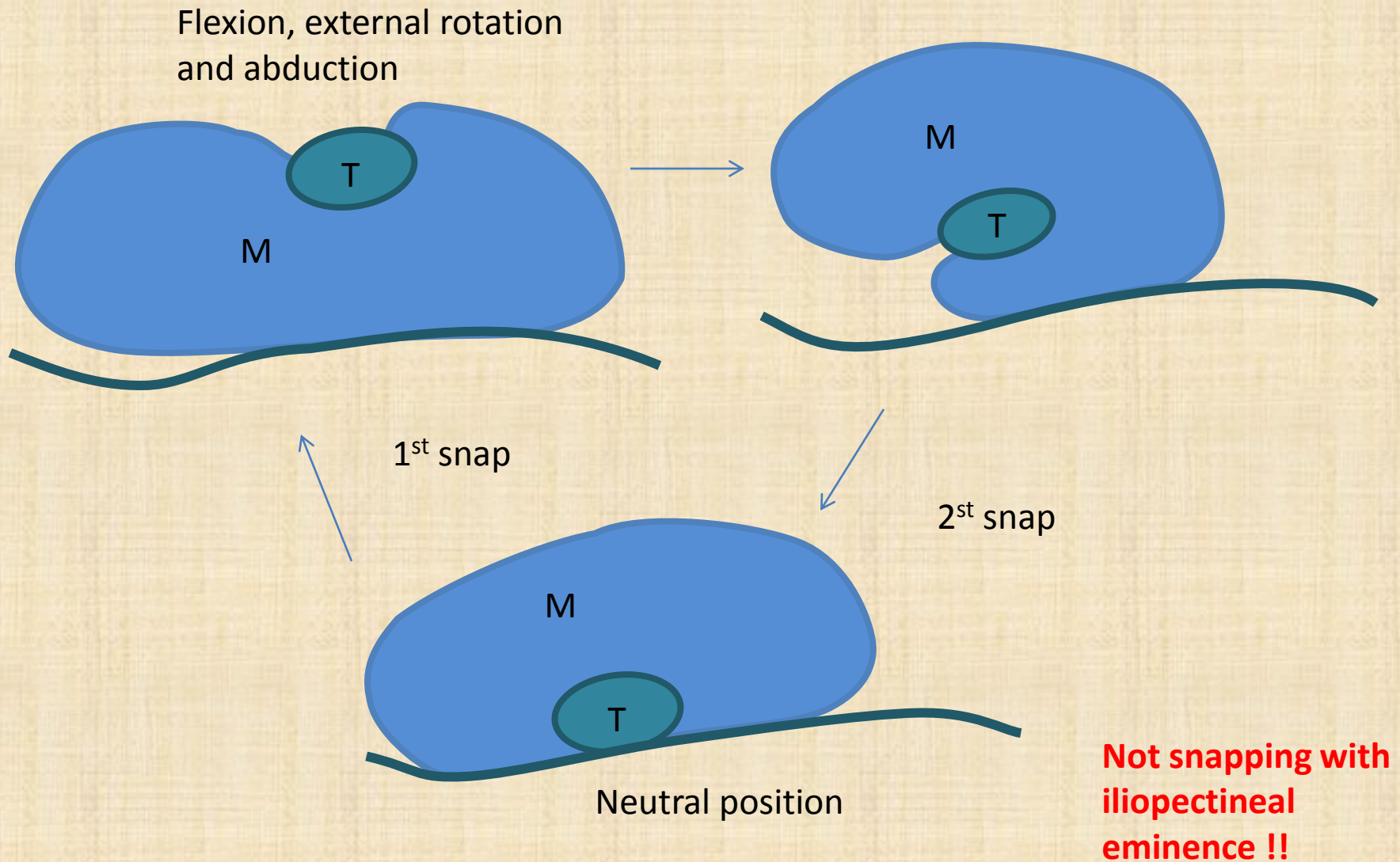
Ischiofemoral bursitis



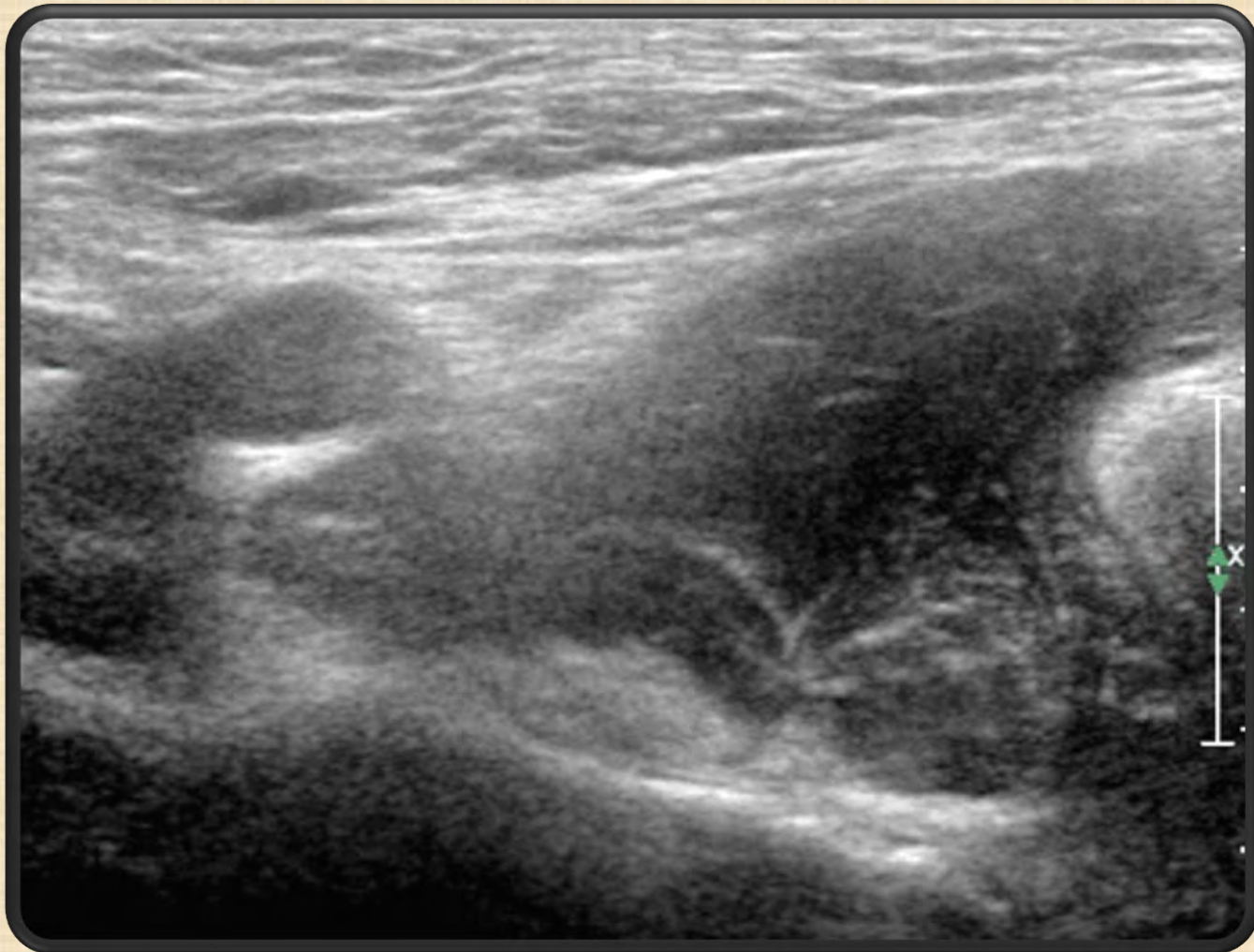B. Snapping Hip

- Intra-articular
 - ✓ Labral
 - ✓ Chondral
 - ✓ Loose bodies
- Extra-articular
 - ✓ Iliopsoas tendon (anteriorly) – rare
 - ✓ Iliotibial band/gluteus maximus (laterally) – more common
 - ✓ Long head of biceps (posteriorly) – very rare (snapping bottom)

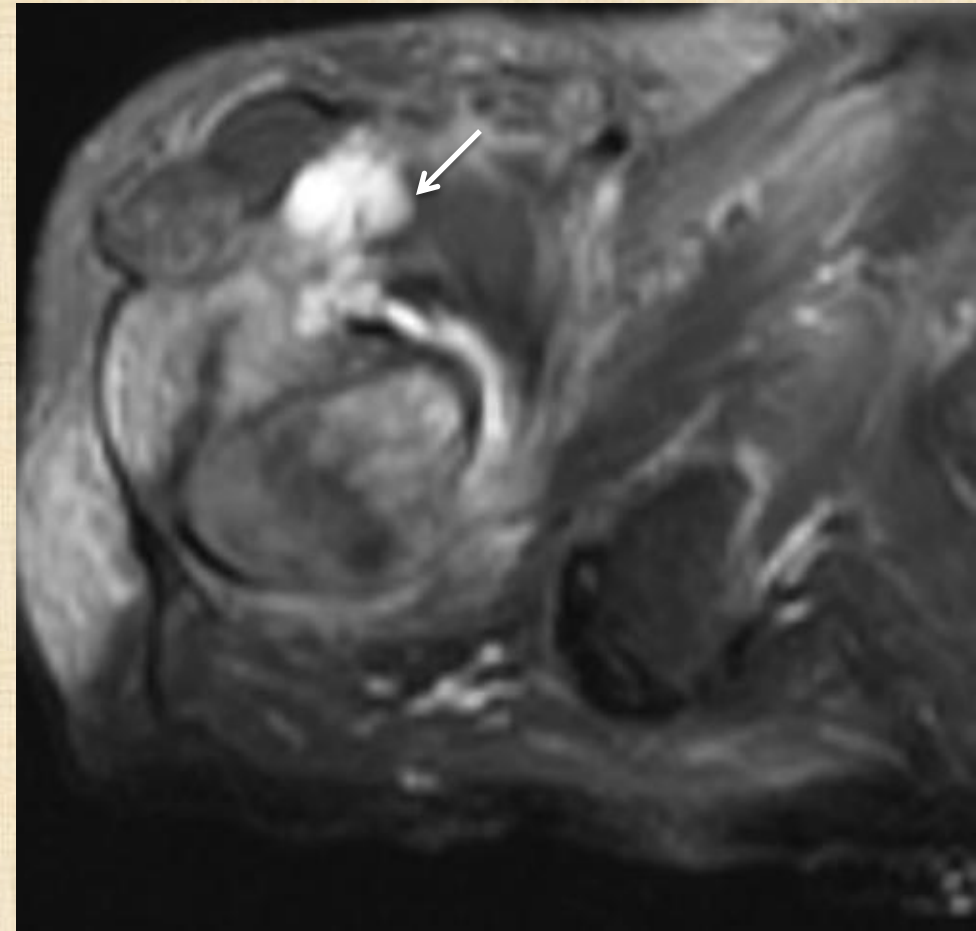
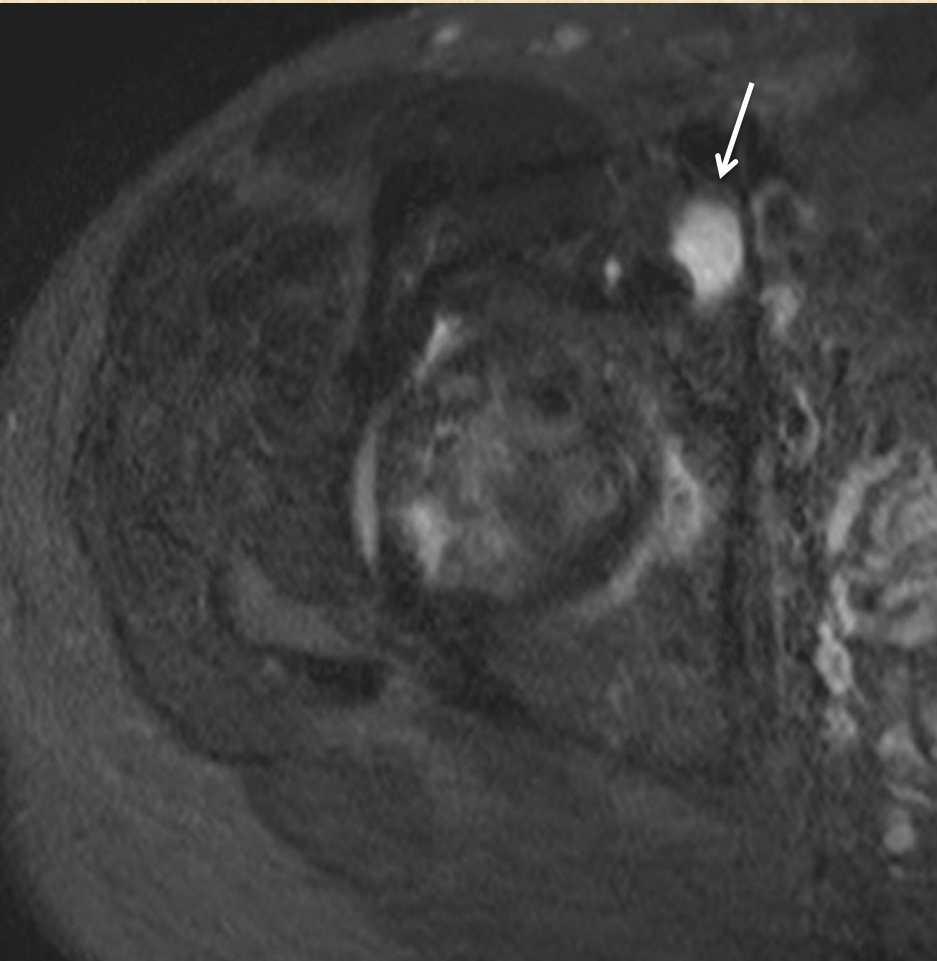
Iliopsoas tendon (internal) snapping



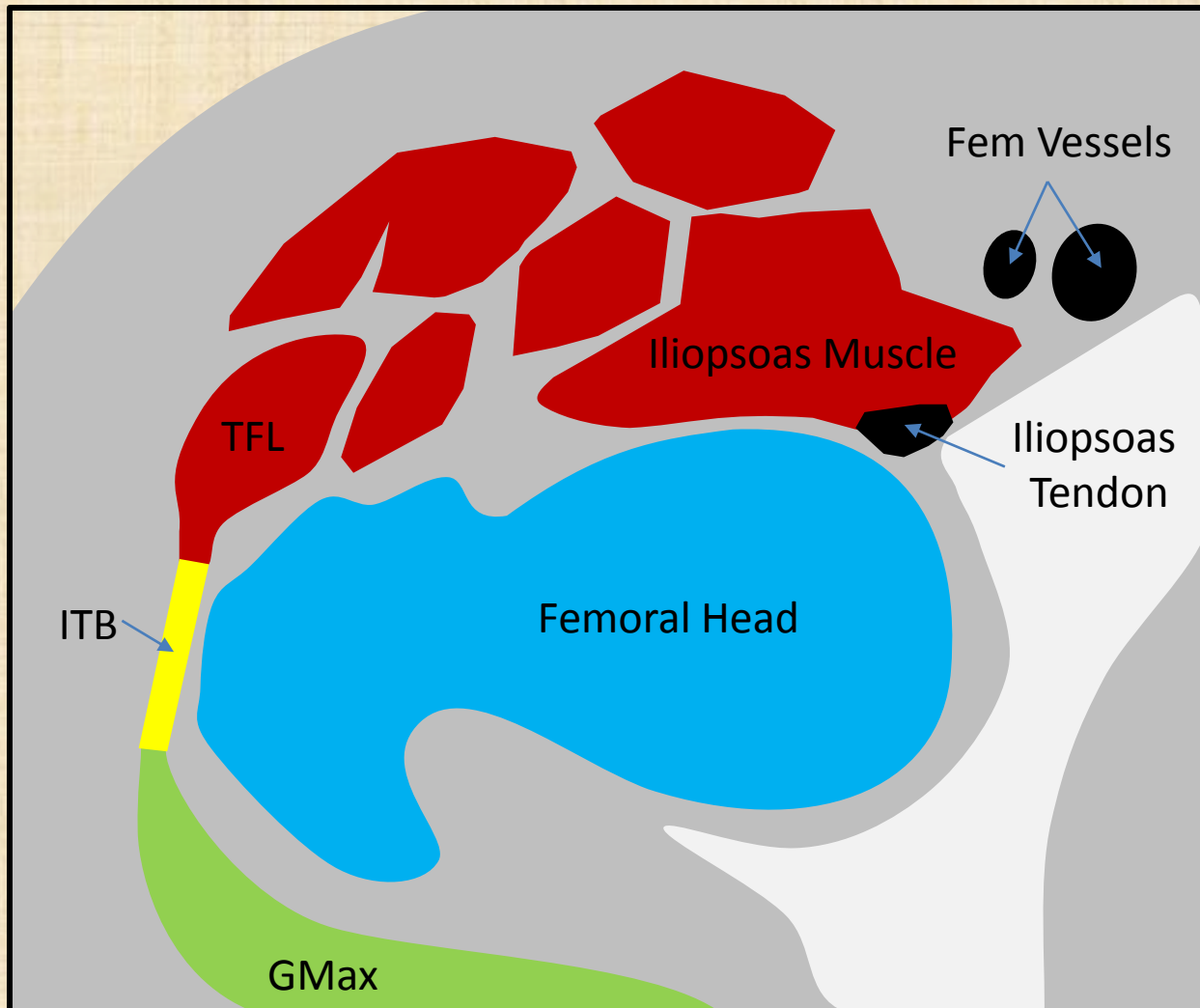
Dynamic U/S



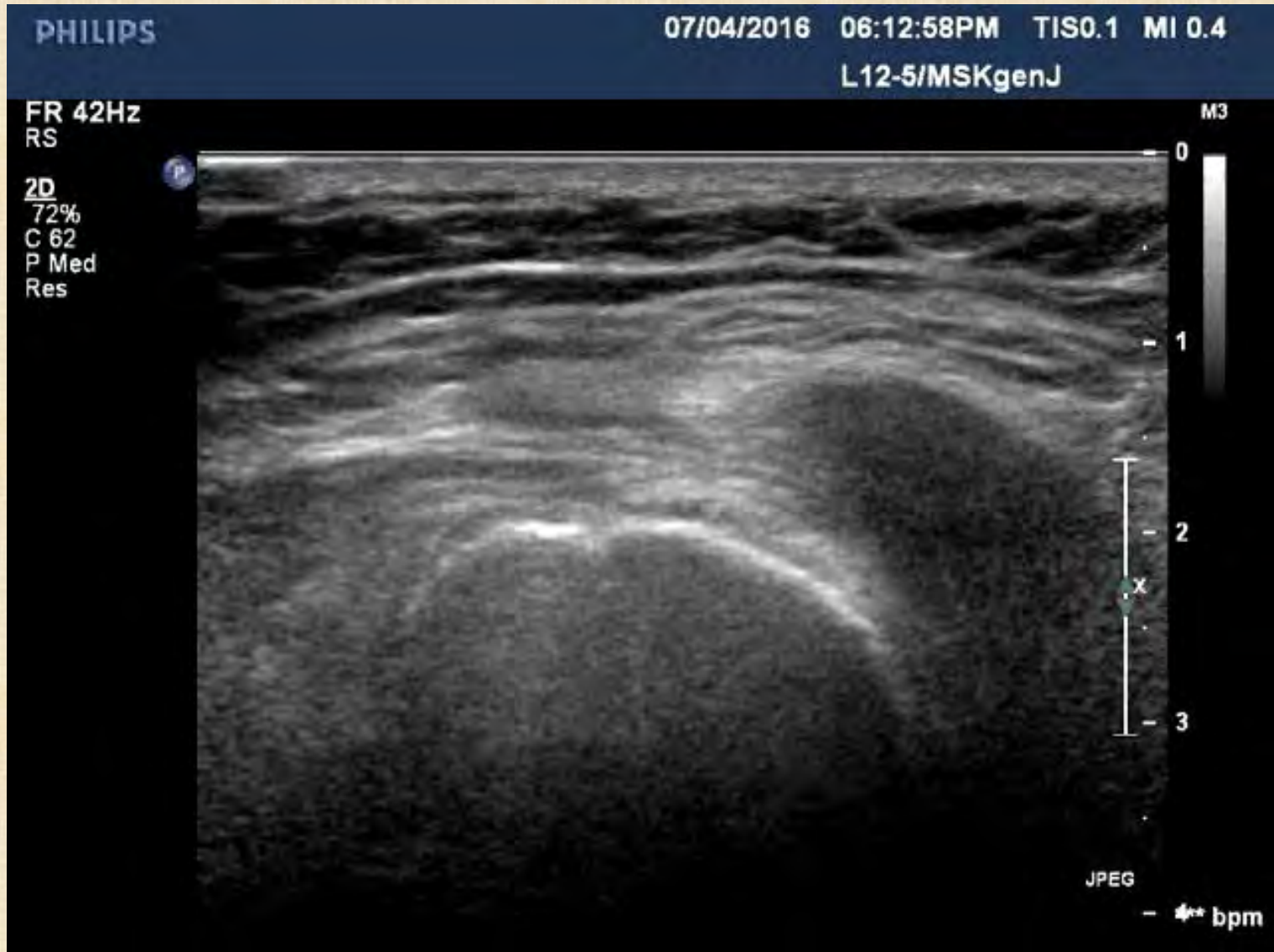Iliopsoas tendinosis and bursitis



Iliotibial band/gluteus maximus (external) snapping



Dynamic U/S

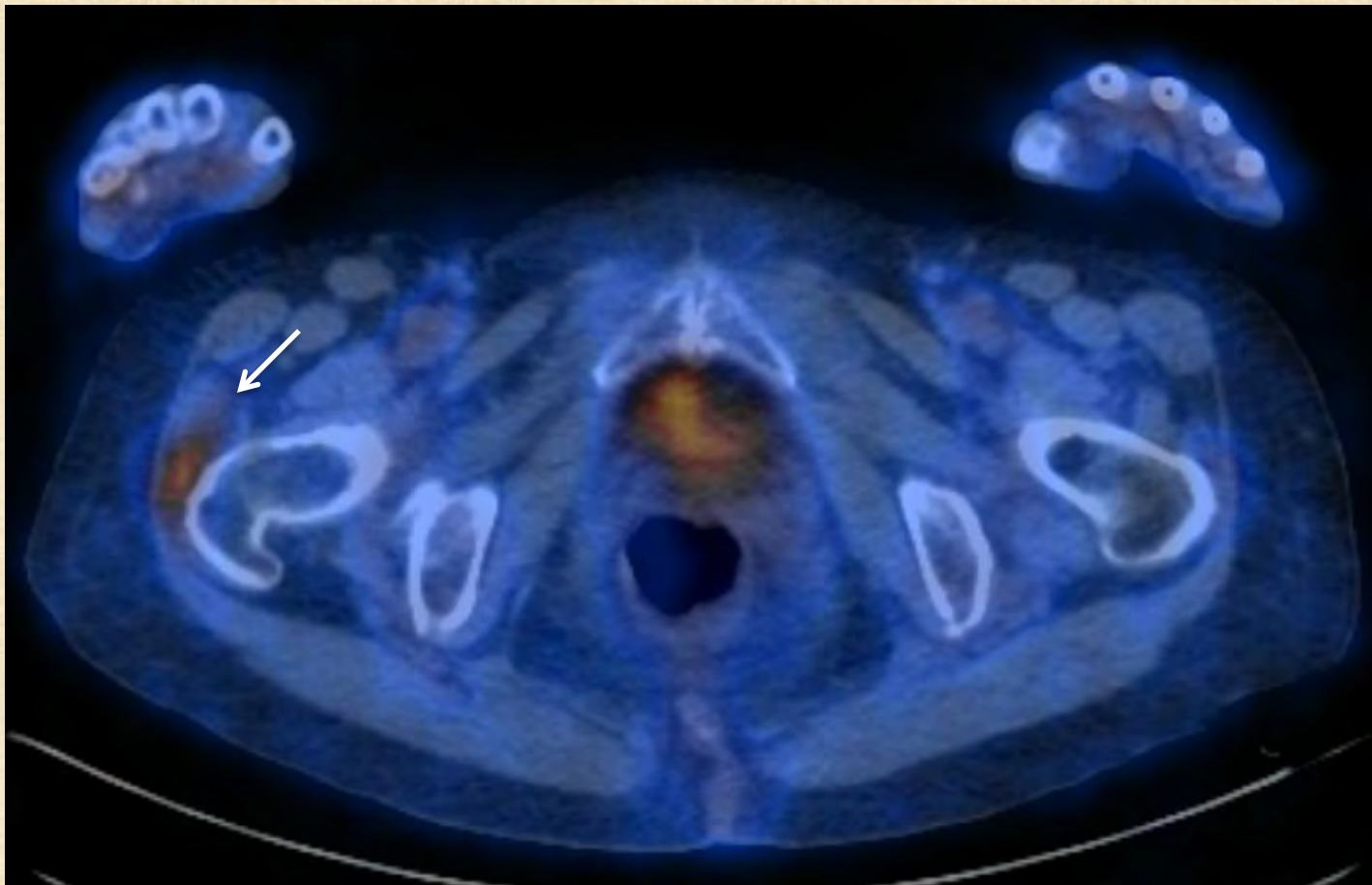


Snapping iliotibial band

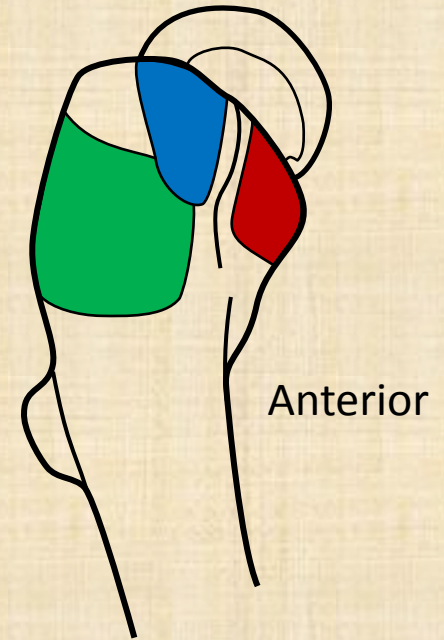
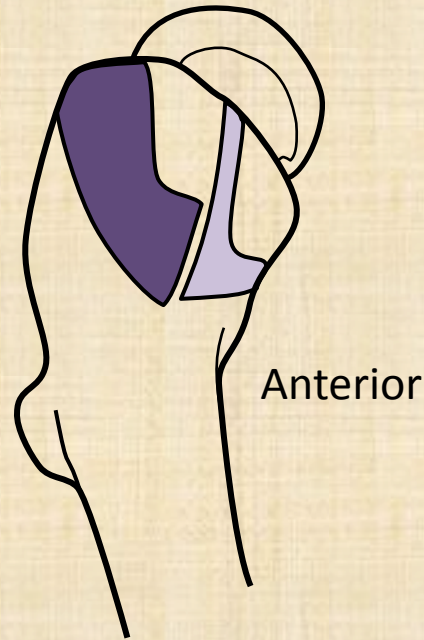
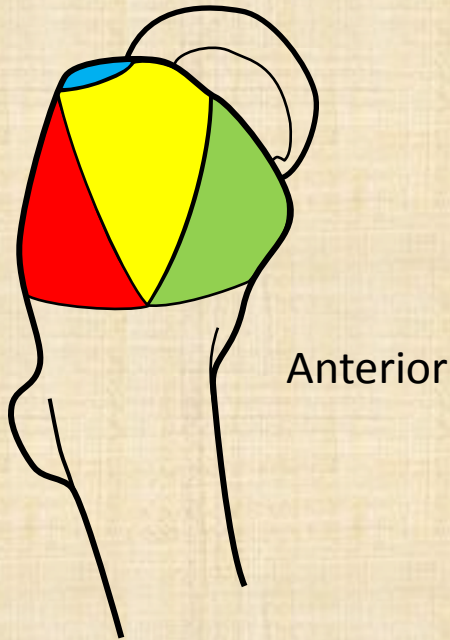
- Iliotibial band and anterior head of gluteus maximus snap over greater trochanter during return to full extension
- Rarely during full flexion

C. Greater trochanteric pain syndrome

- Rotator cuff of hip



Lateral view



Facets

Anterior

Lateral

Posterior

Posterosuperior

Tendon

Gluteus minimus

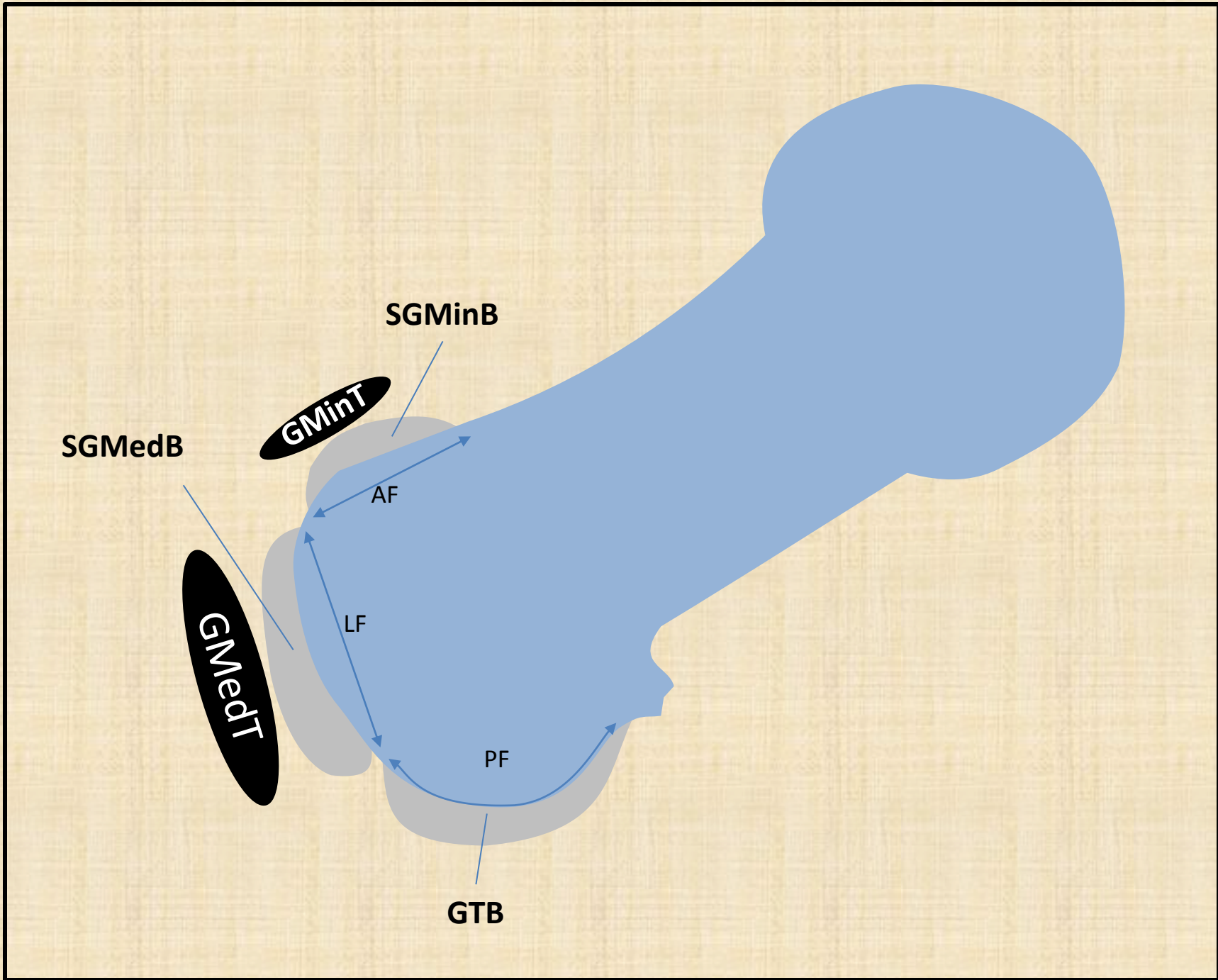
Gluteus medius

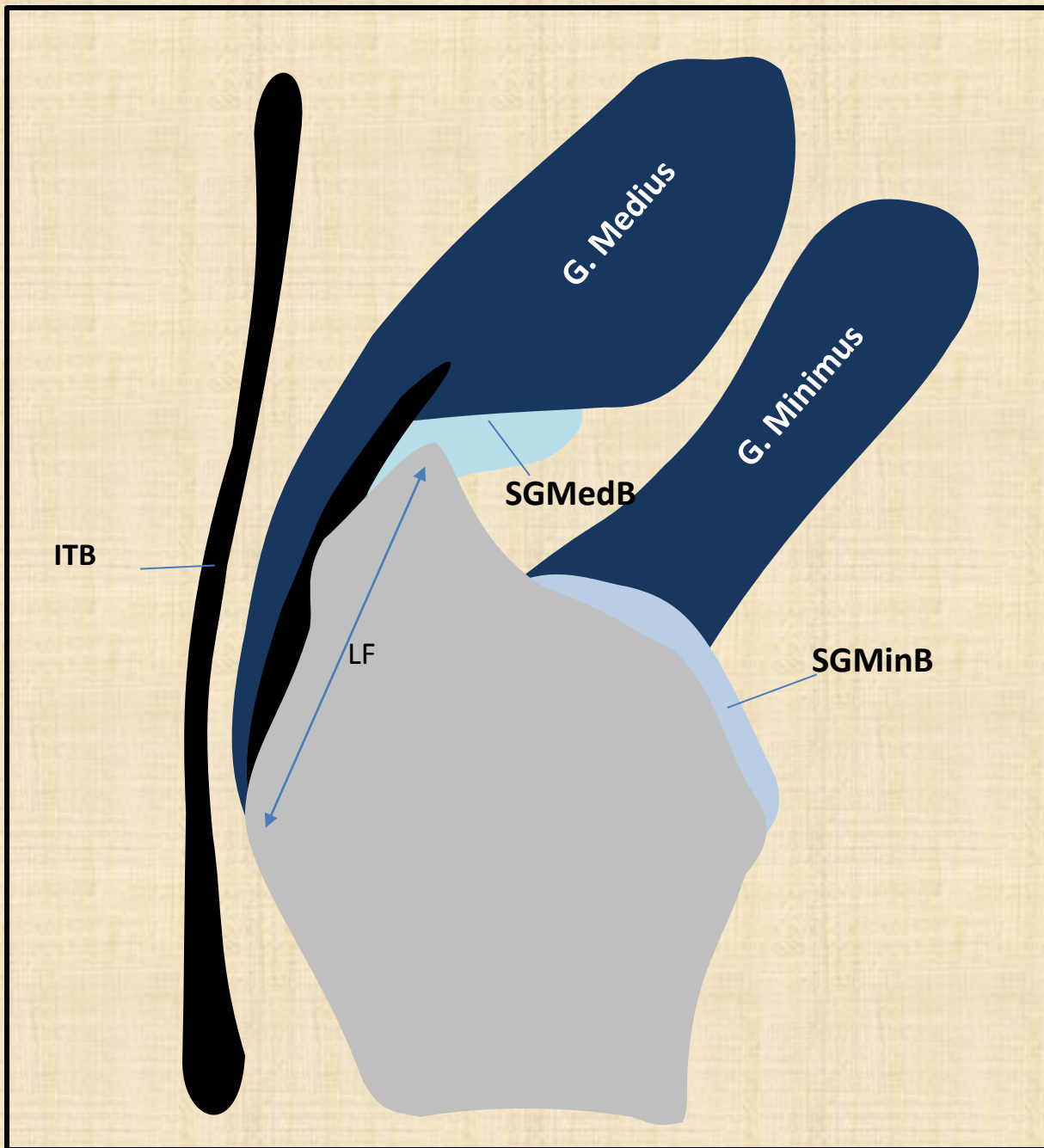
Bursa

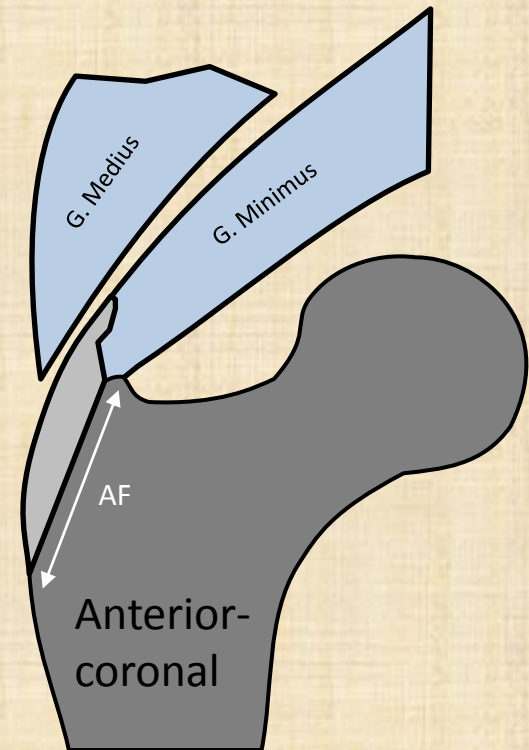
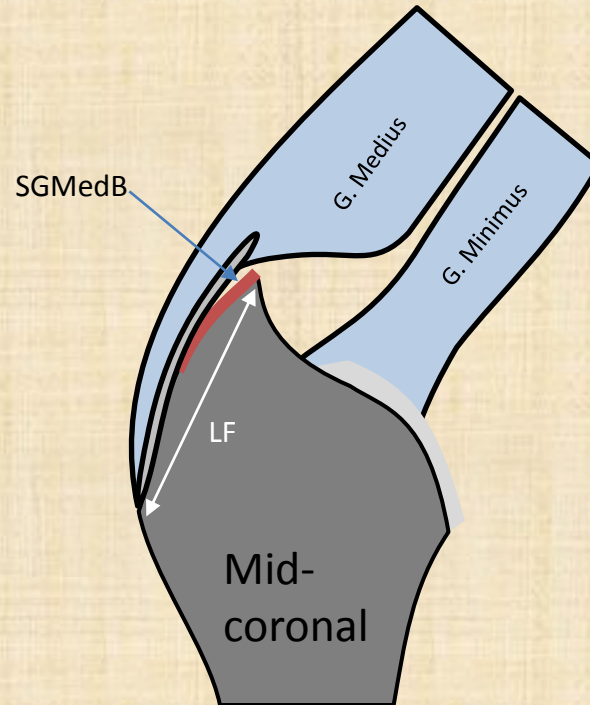
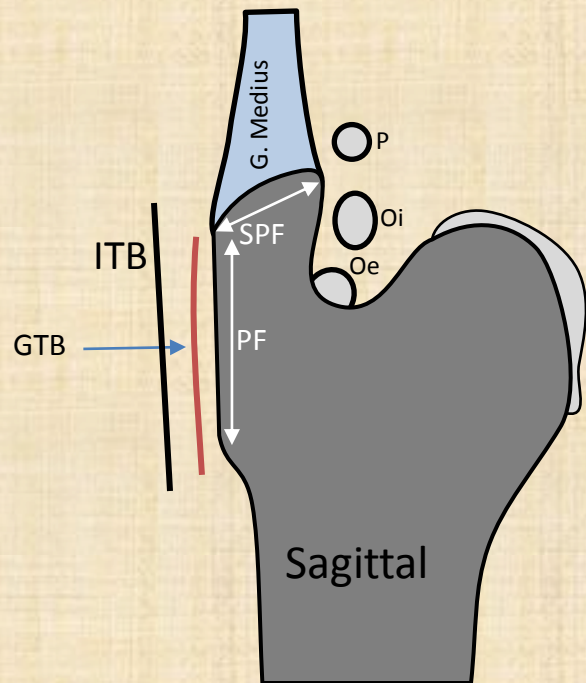
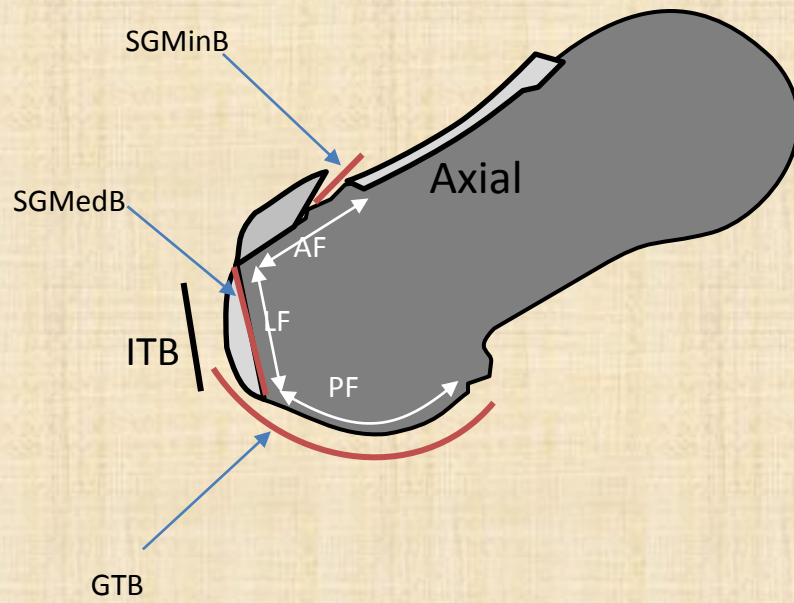
Greater trochanteric bursa

Subgluteus maximus bursa

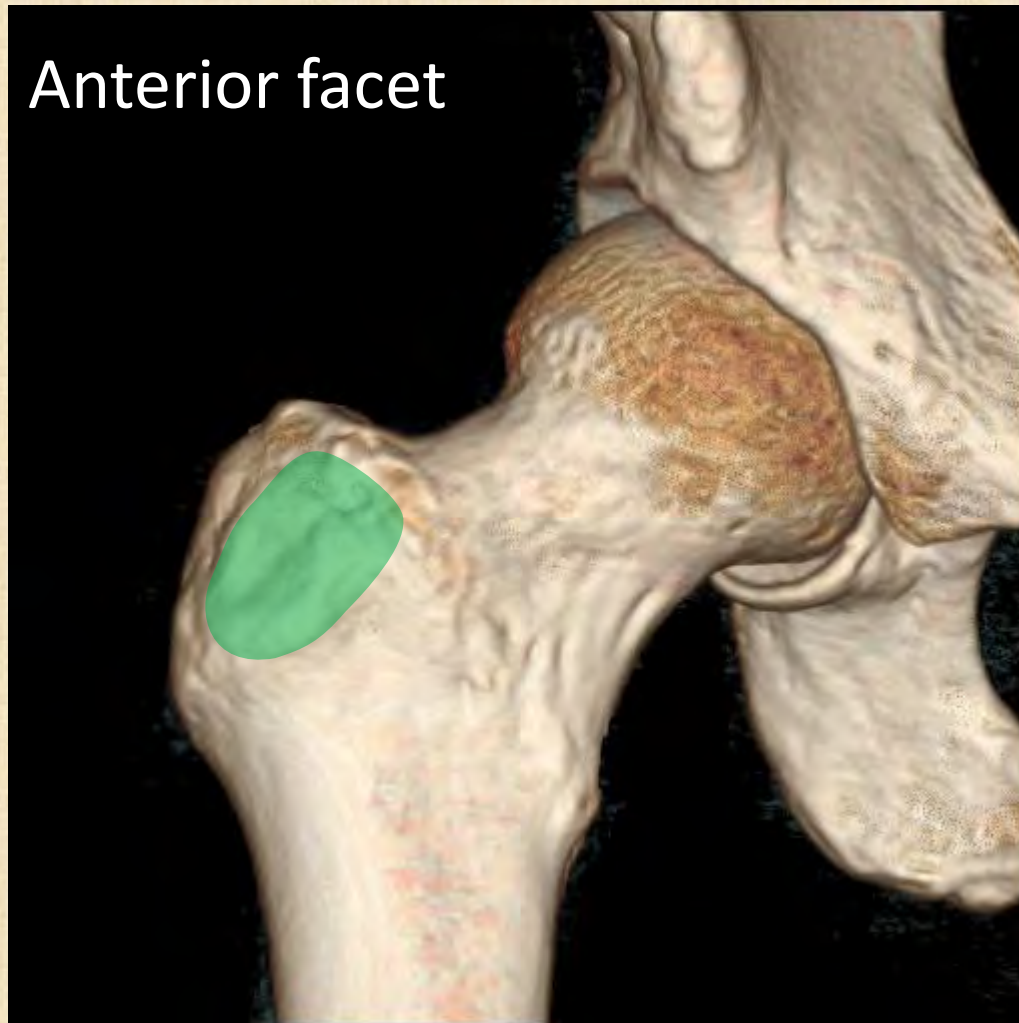
Subgluteus minimus bursa



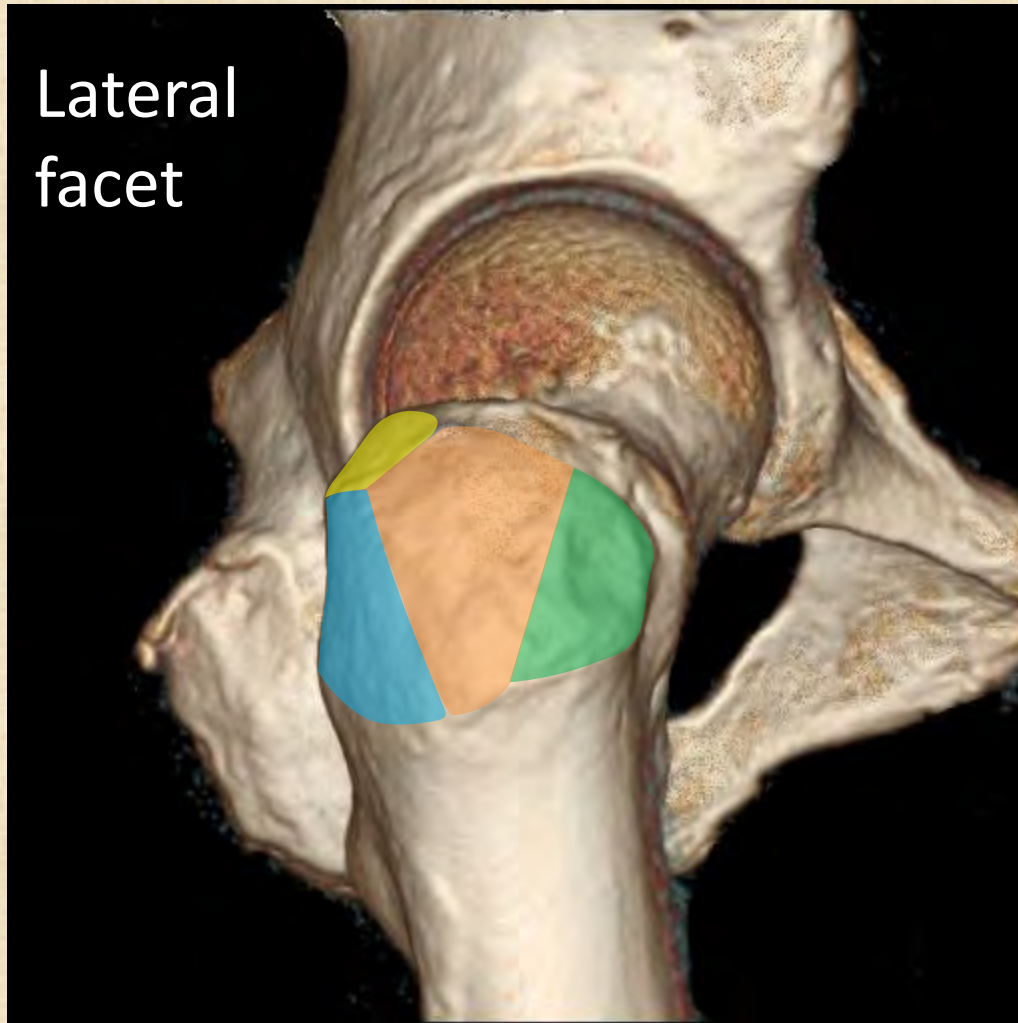




Facets



Facets

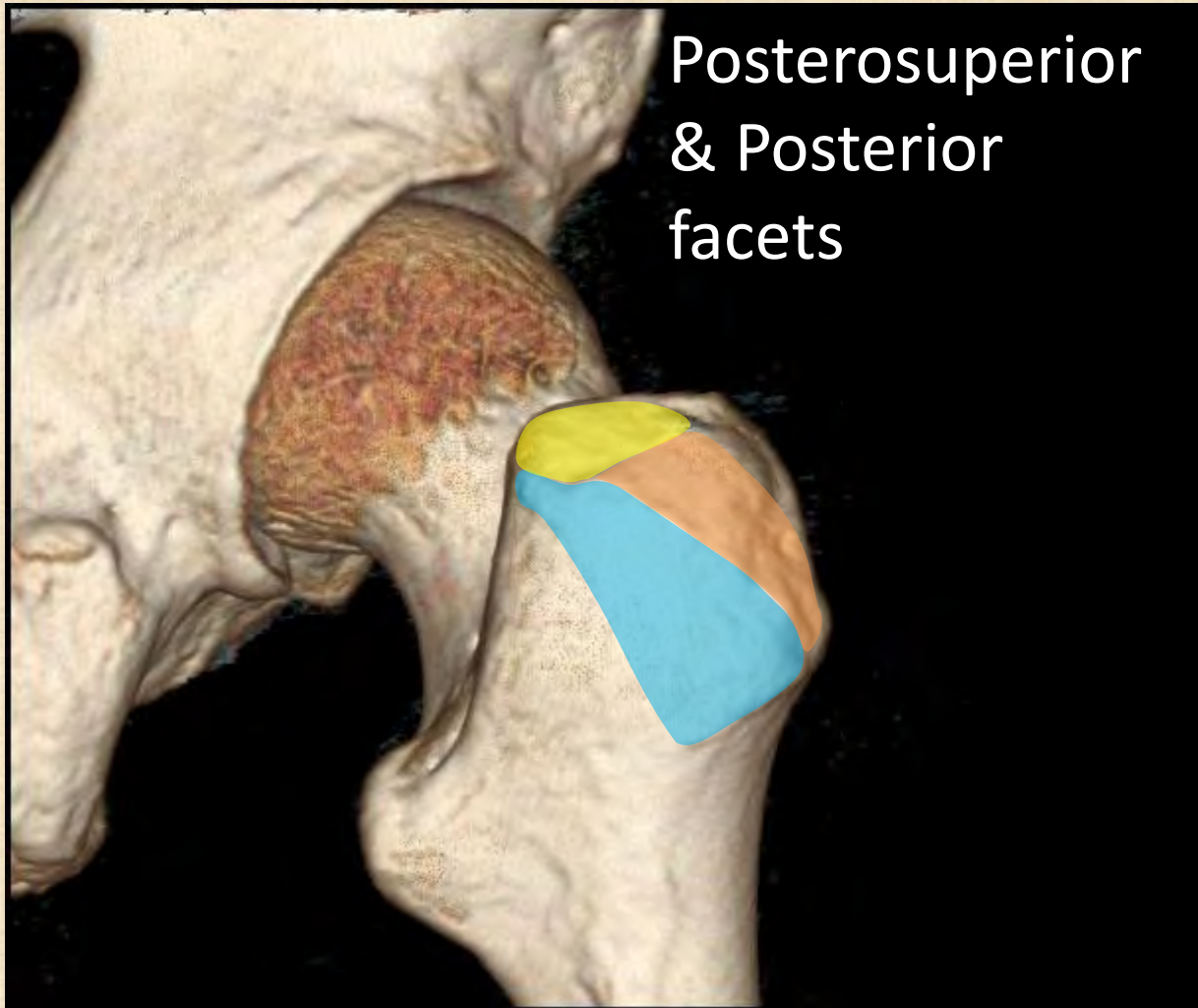


Lateral
facet

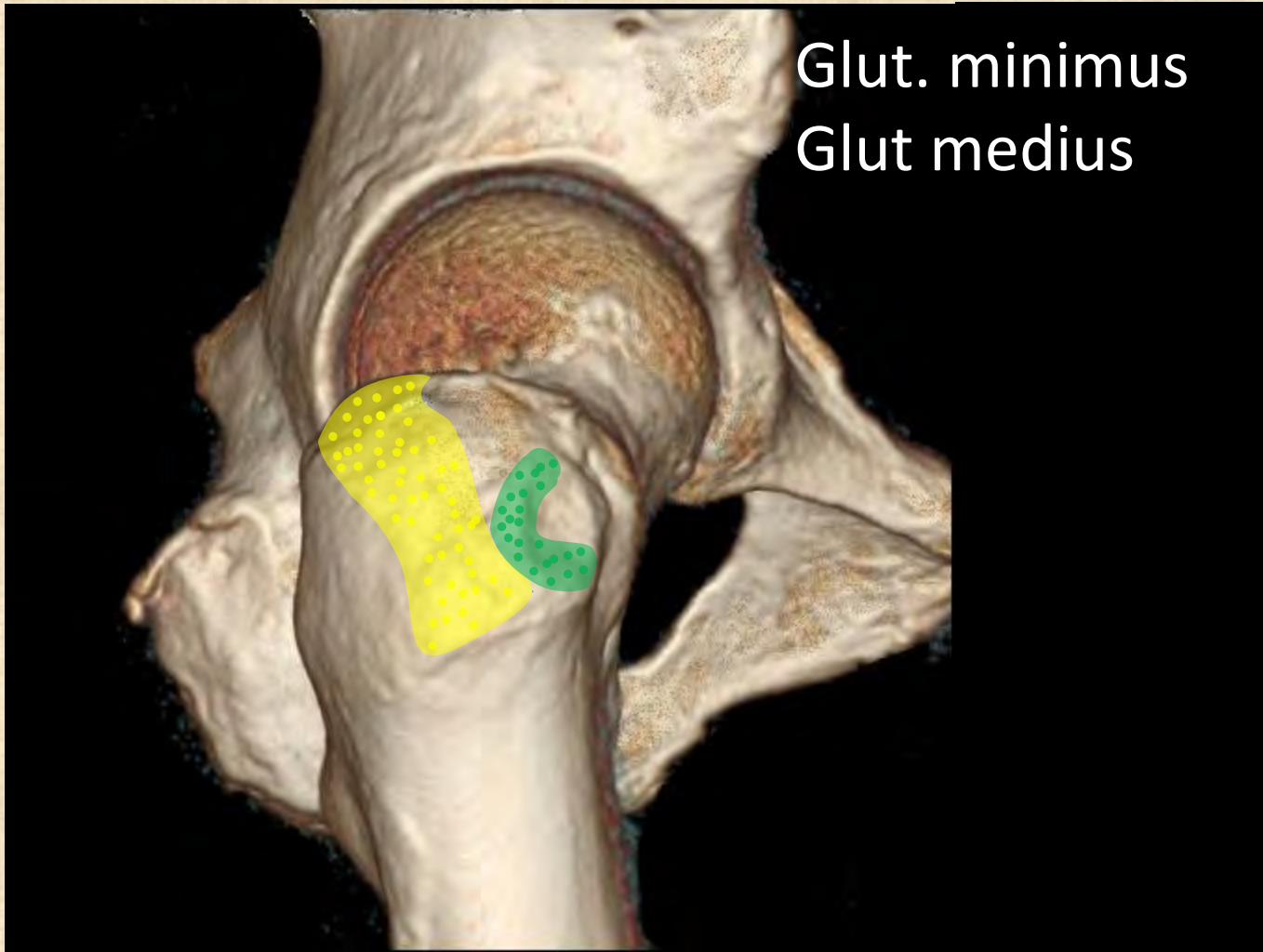
Posterior

Anterior

Facets (posterior)

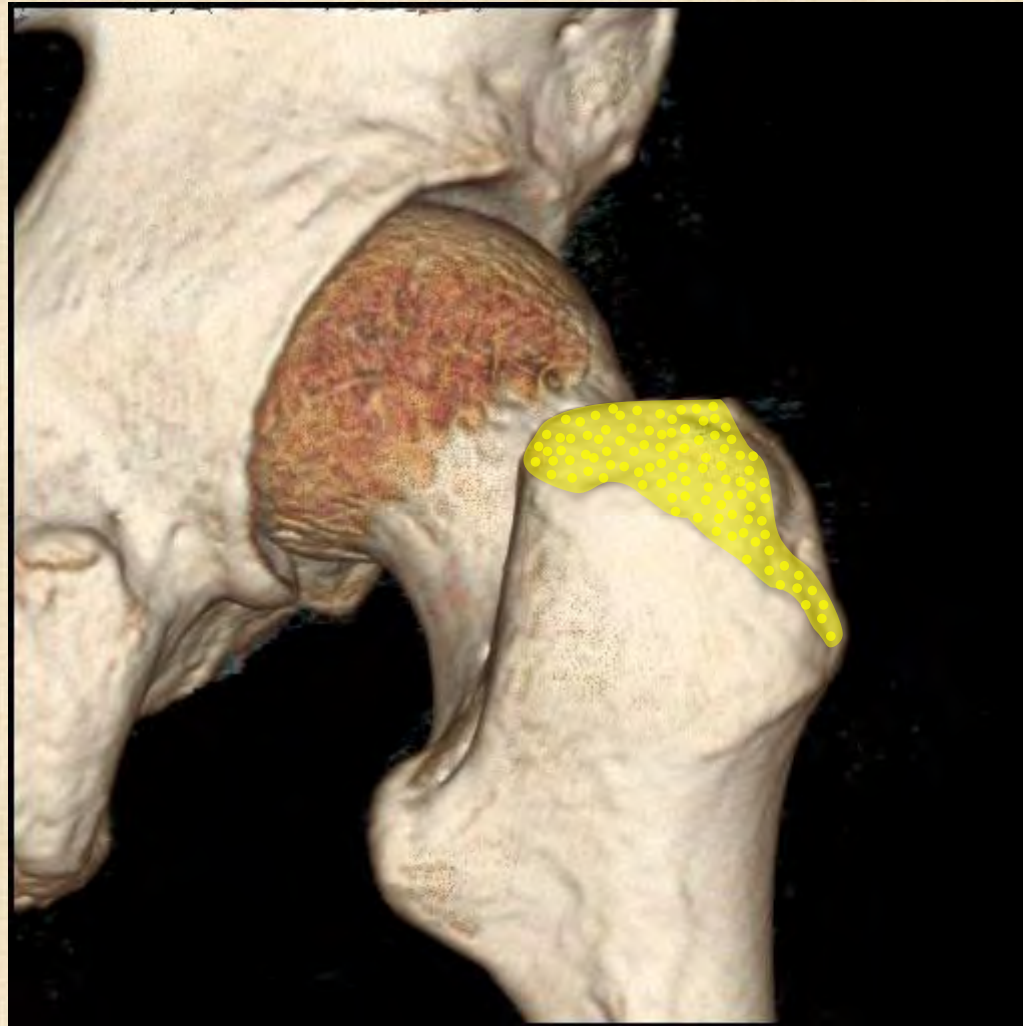

Tendon insertion (lateral)



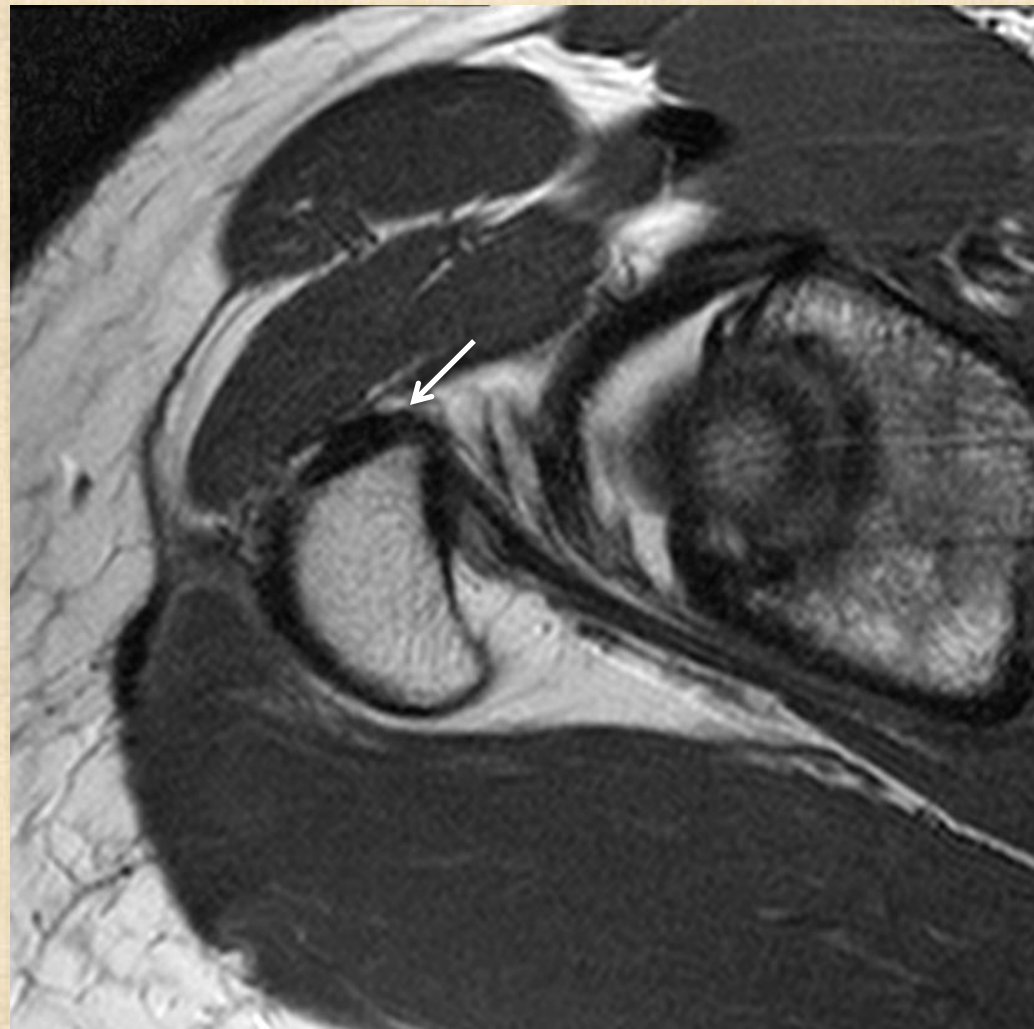
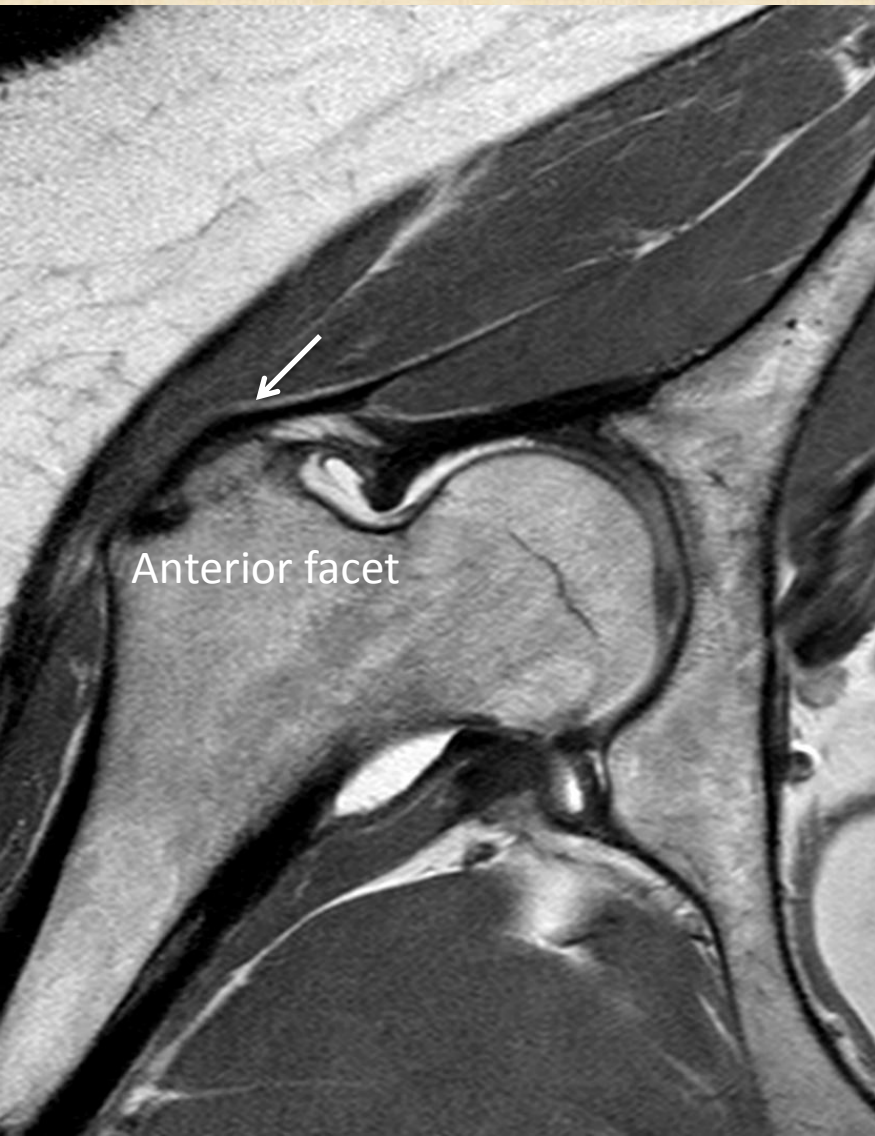Tendon insertion (posterior)

Medial

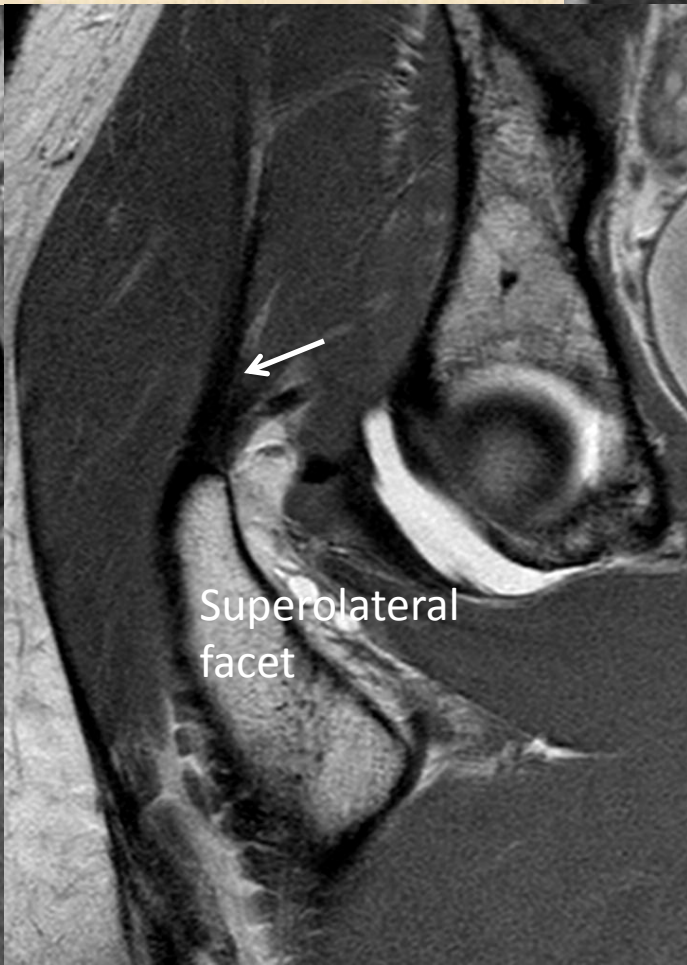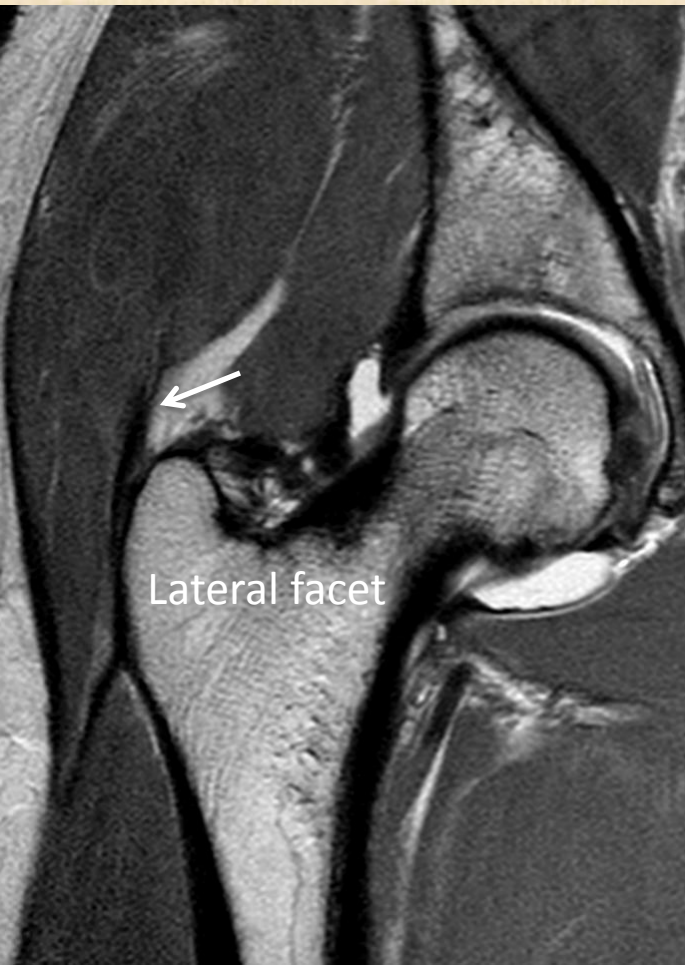
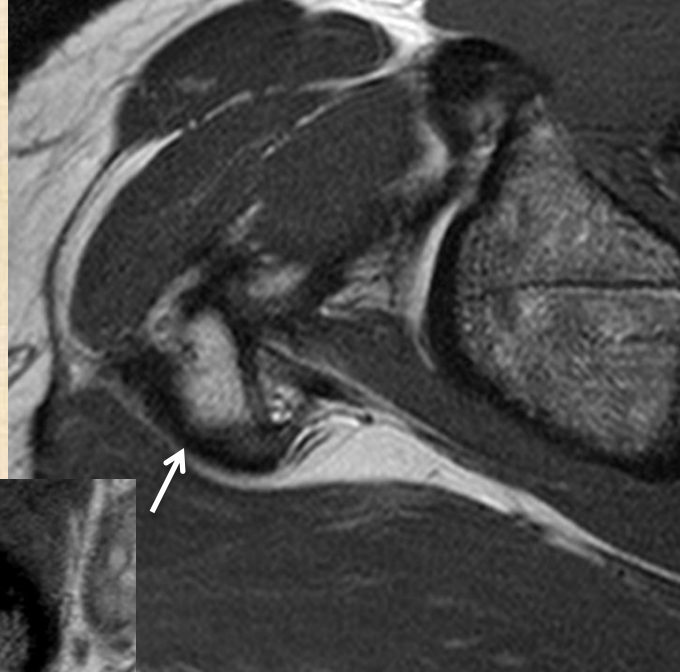


Lateral

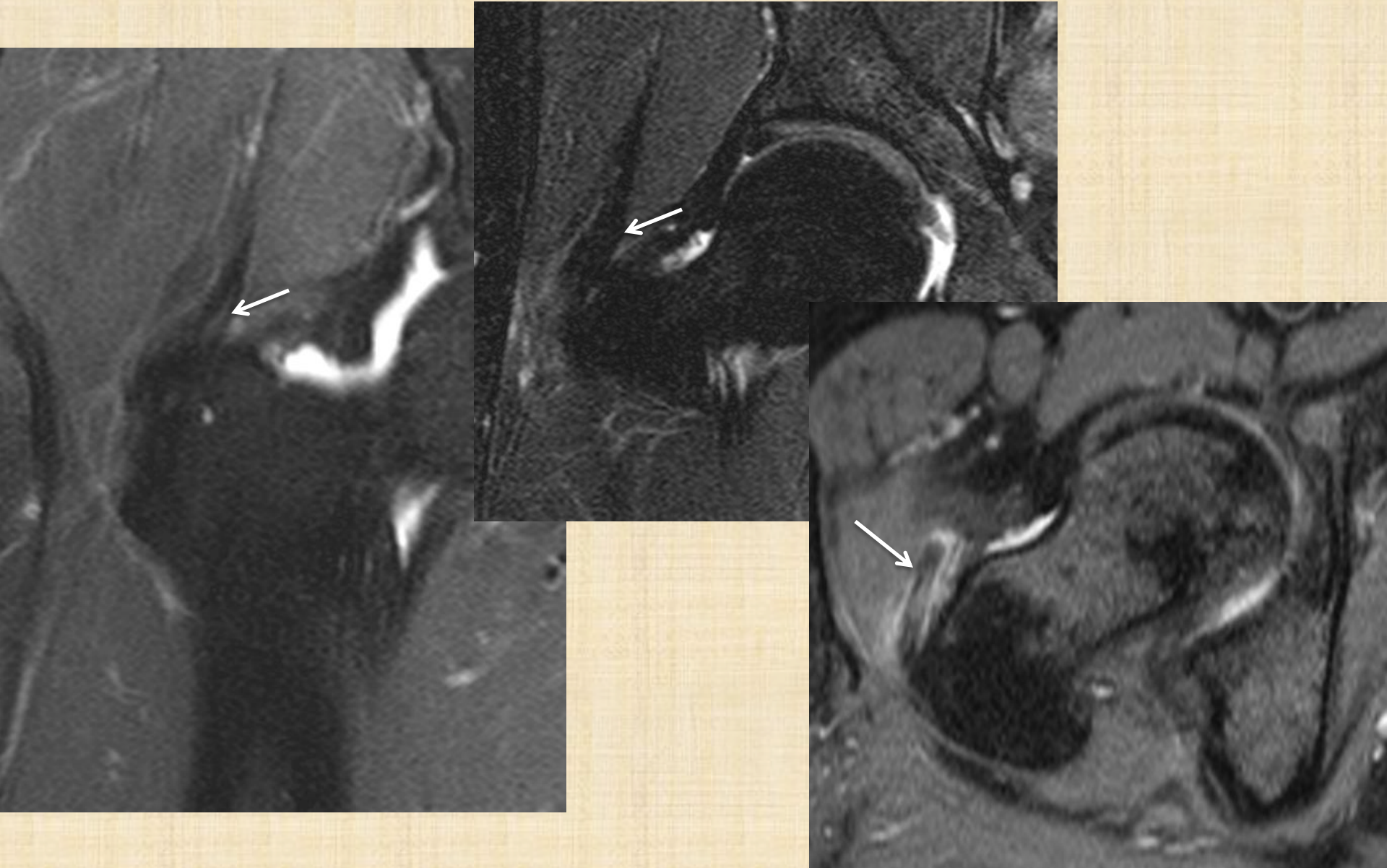
Normal gluteus minimis



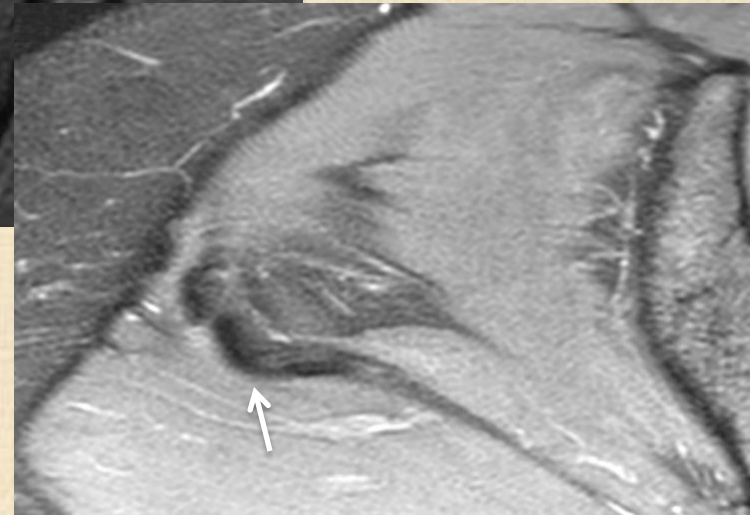
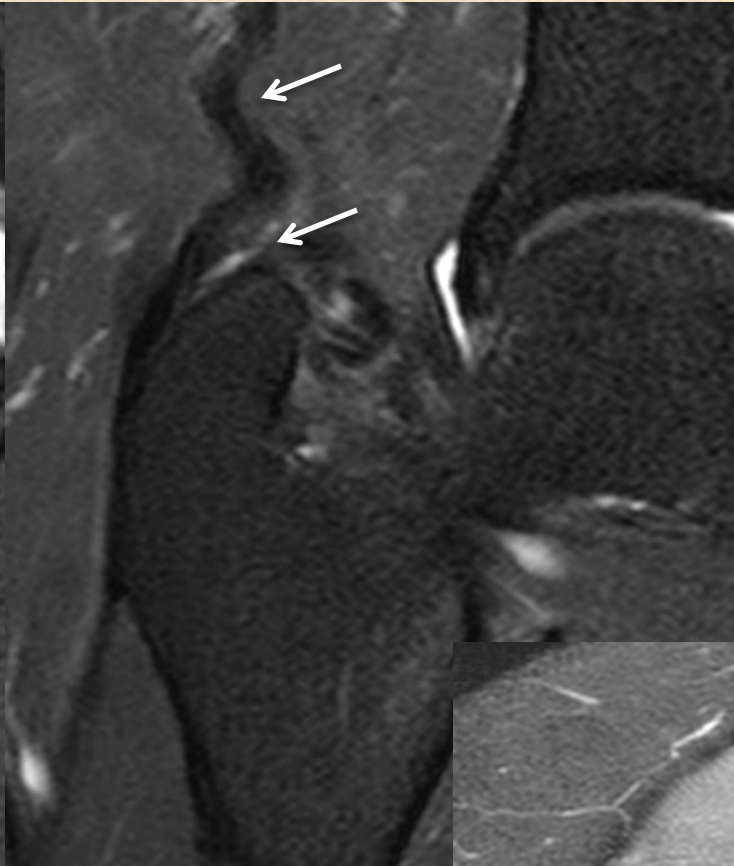
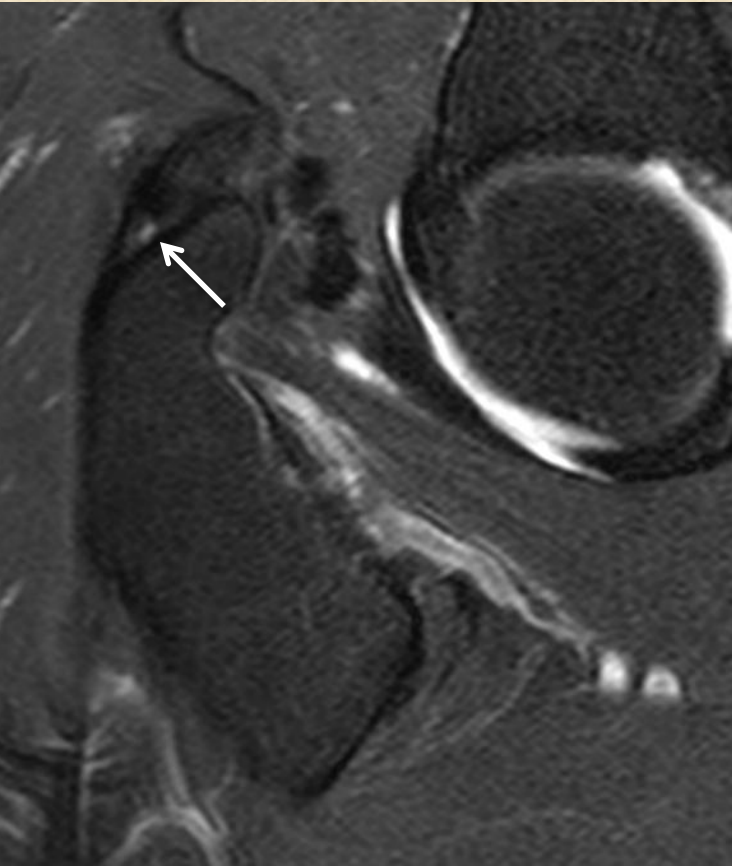
Normal gluteus medimus



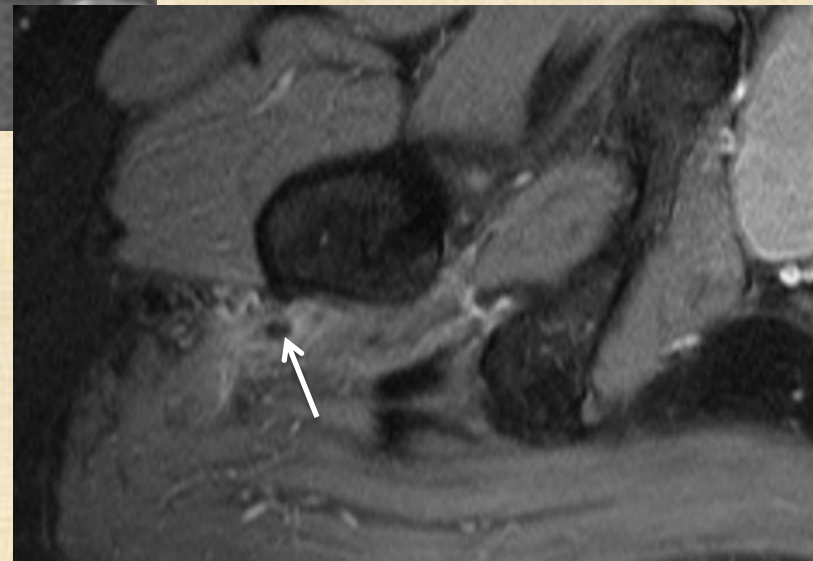
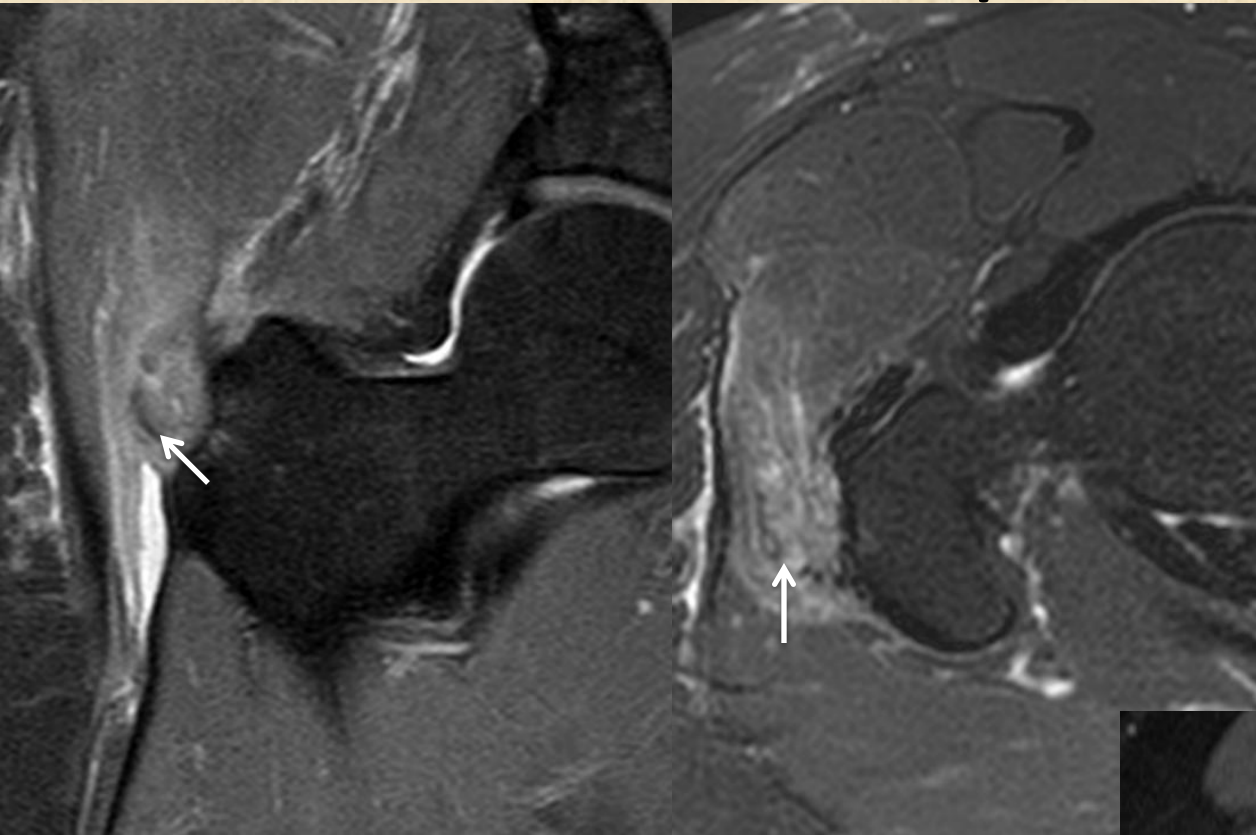
Tendinosis and tear gluteus minimis



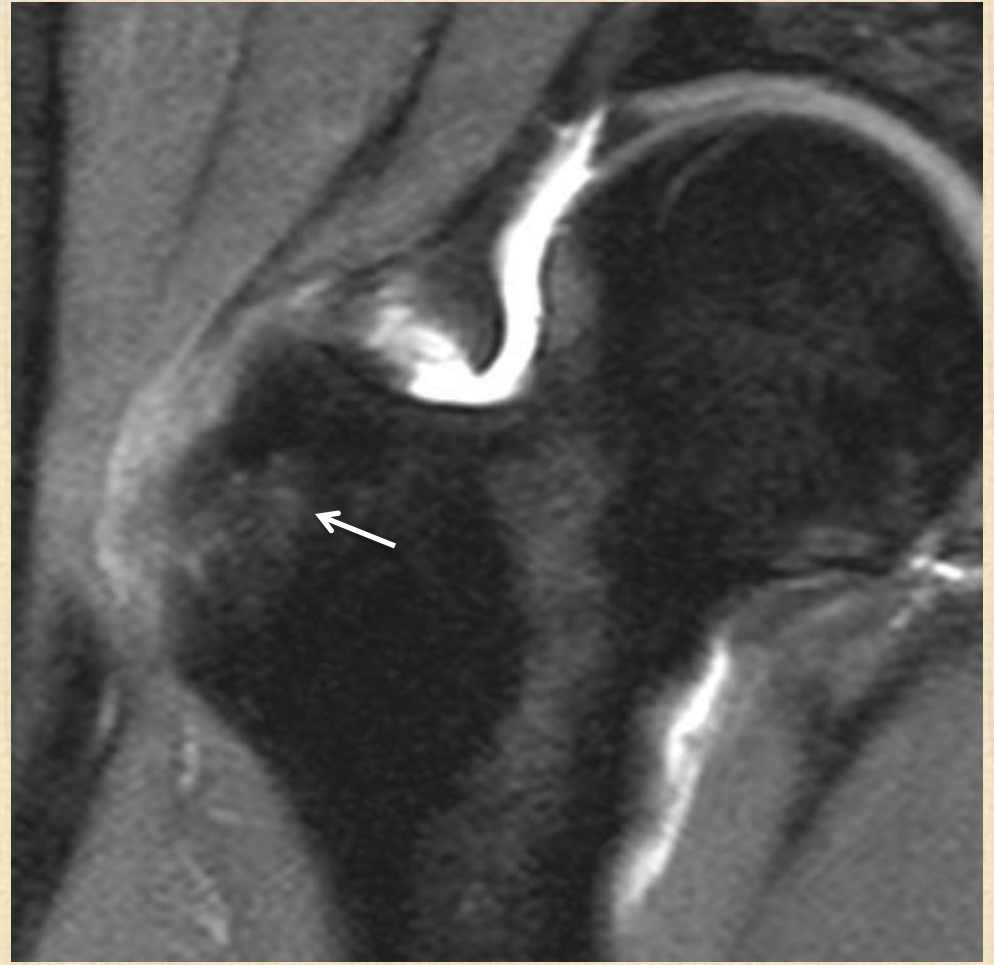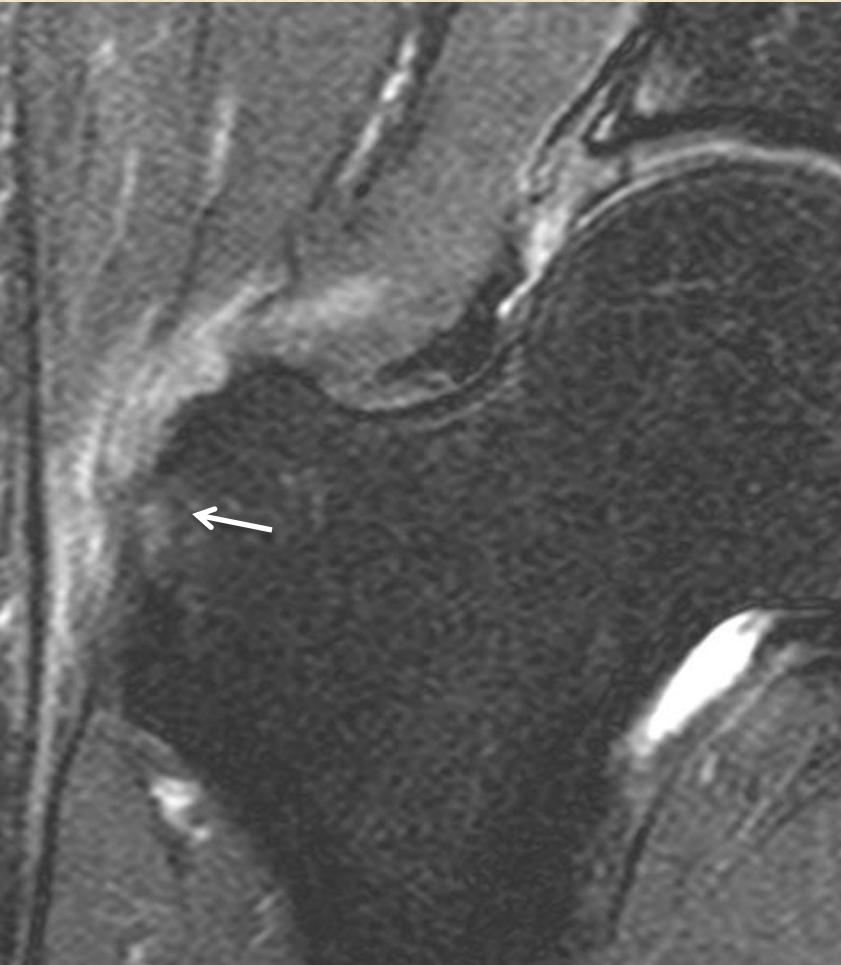
Tendinosis and tear gluteus medimus



Calcific tendinosis/tendinitis

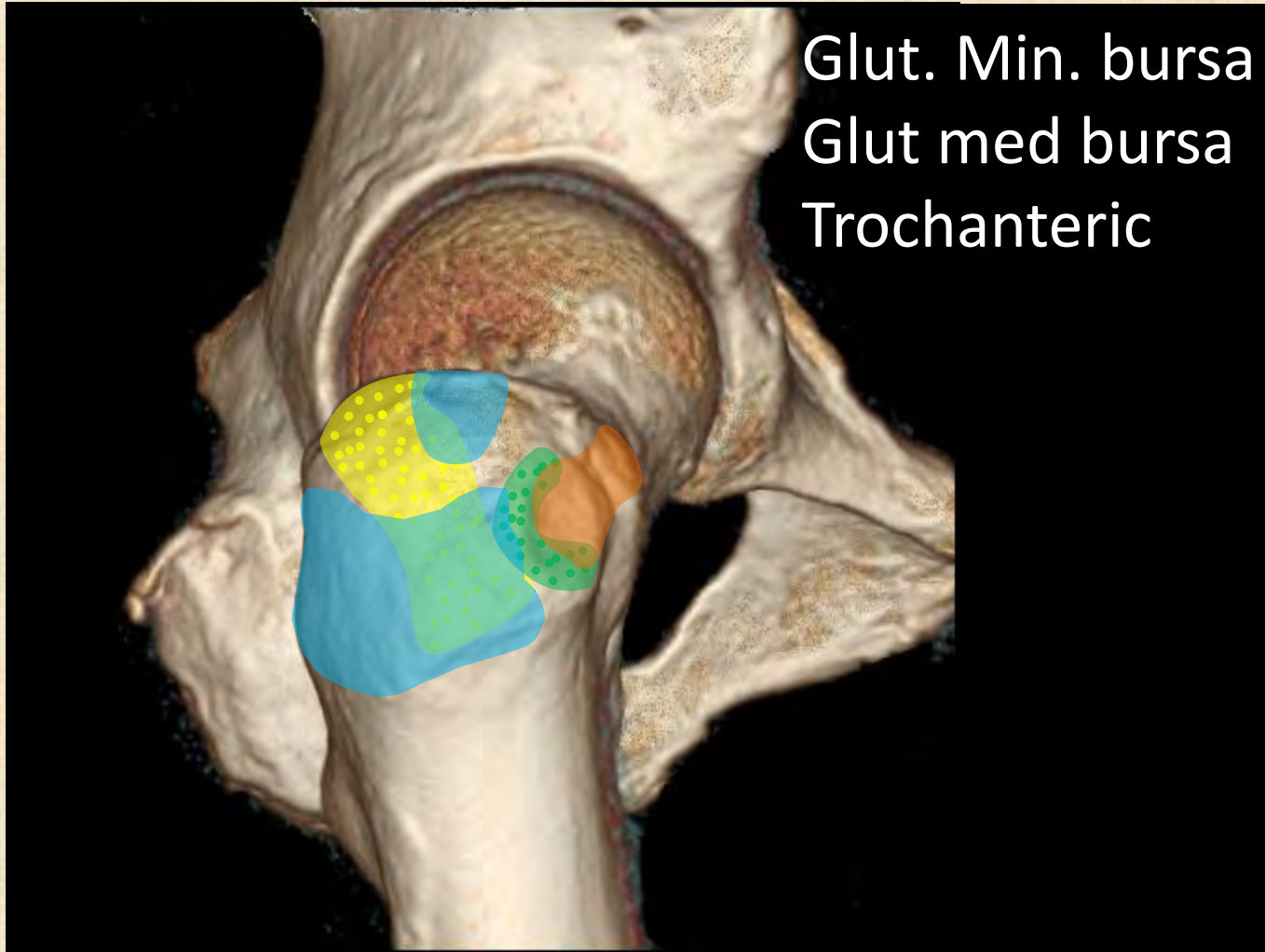


Bony irregularity and edema



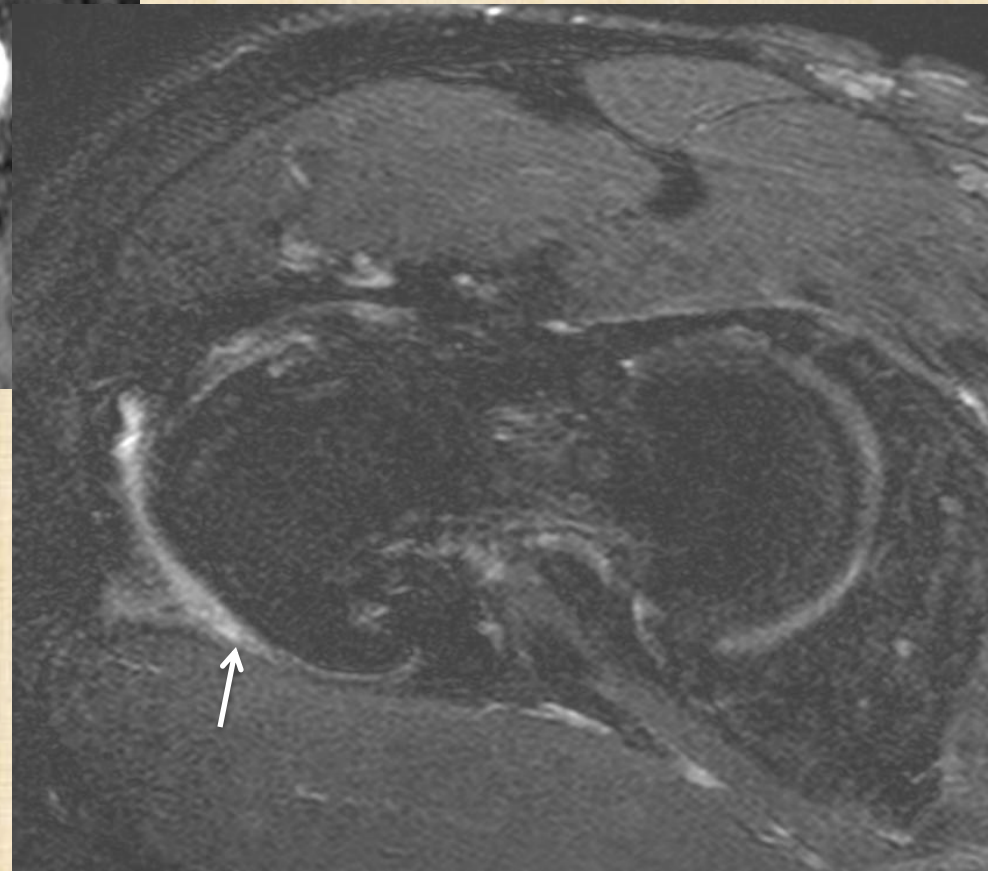
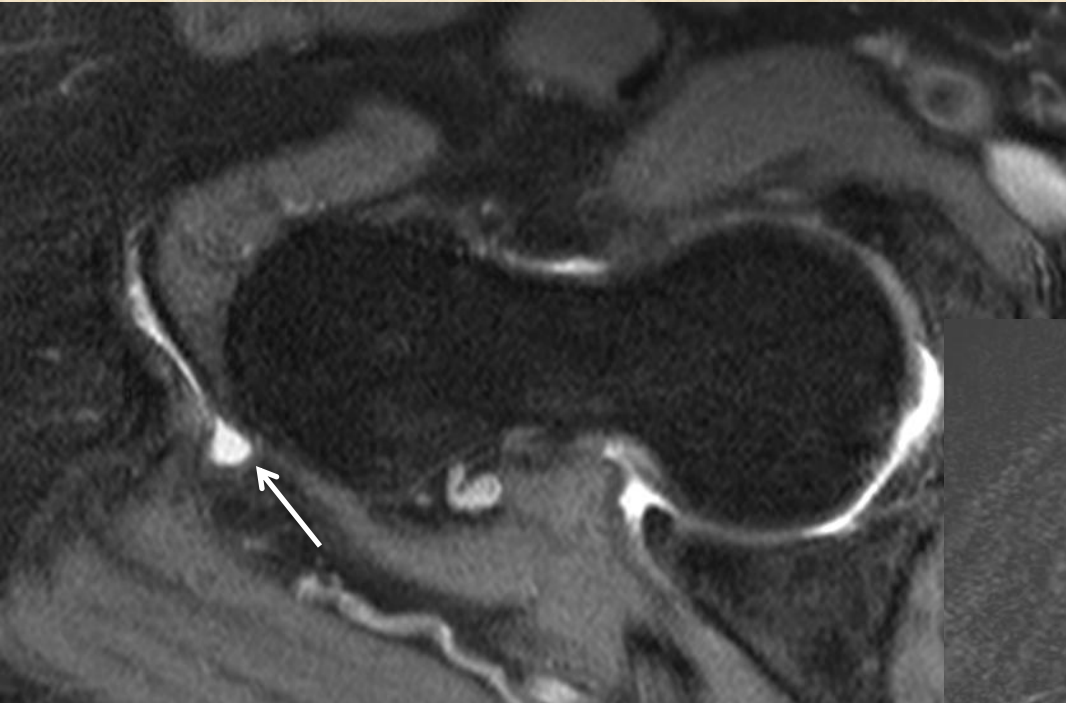
Bursa (lateral)

Posterior

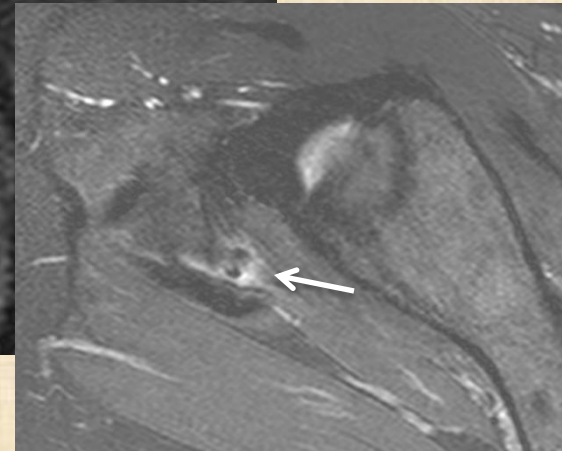
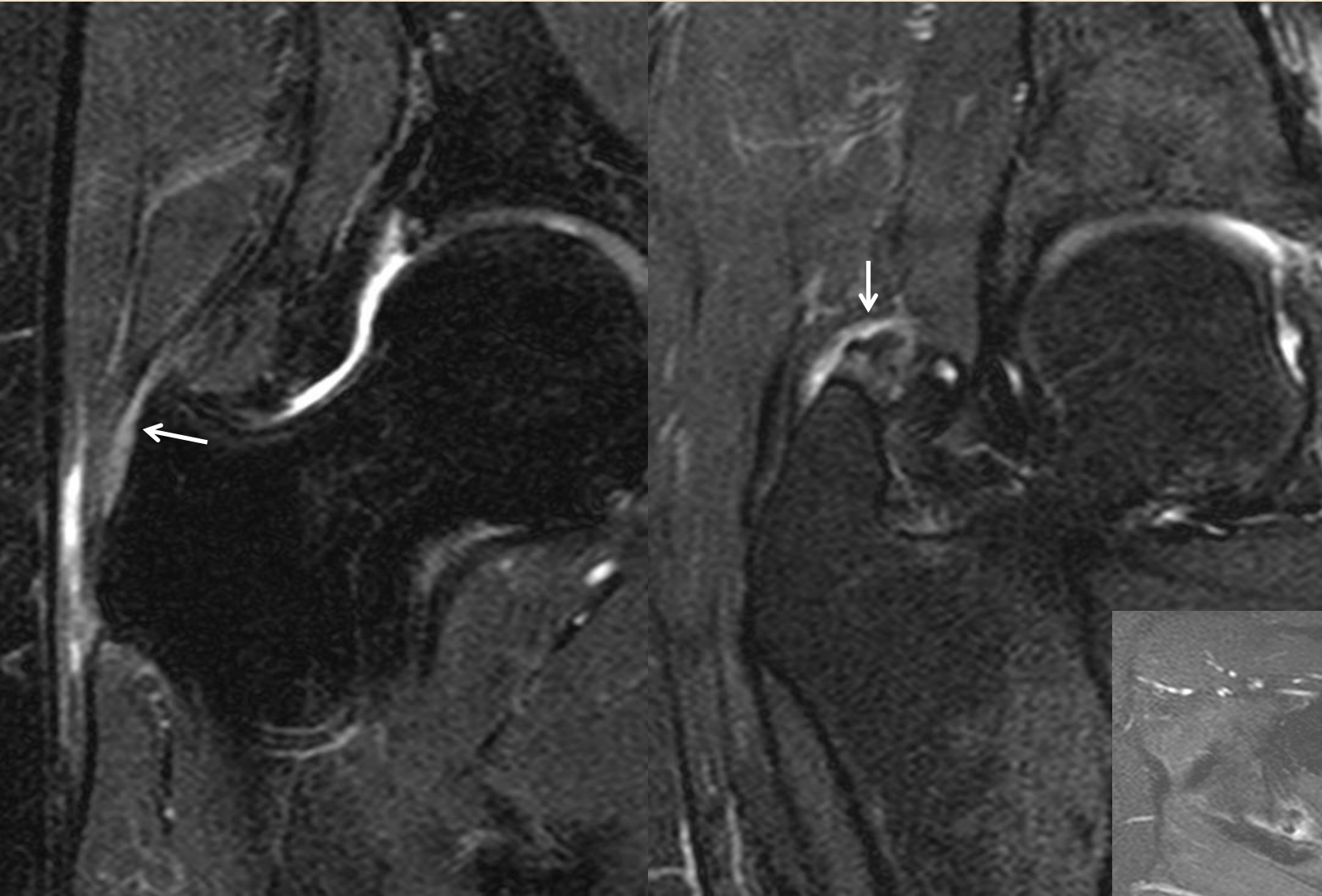


Anterior

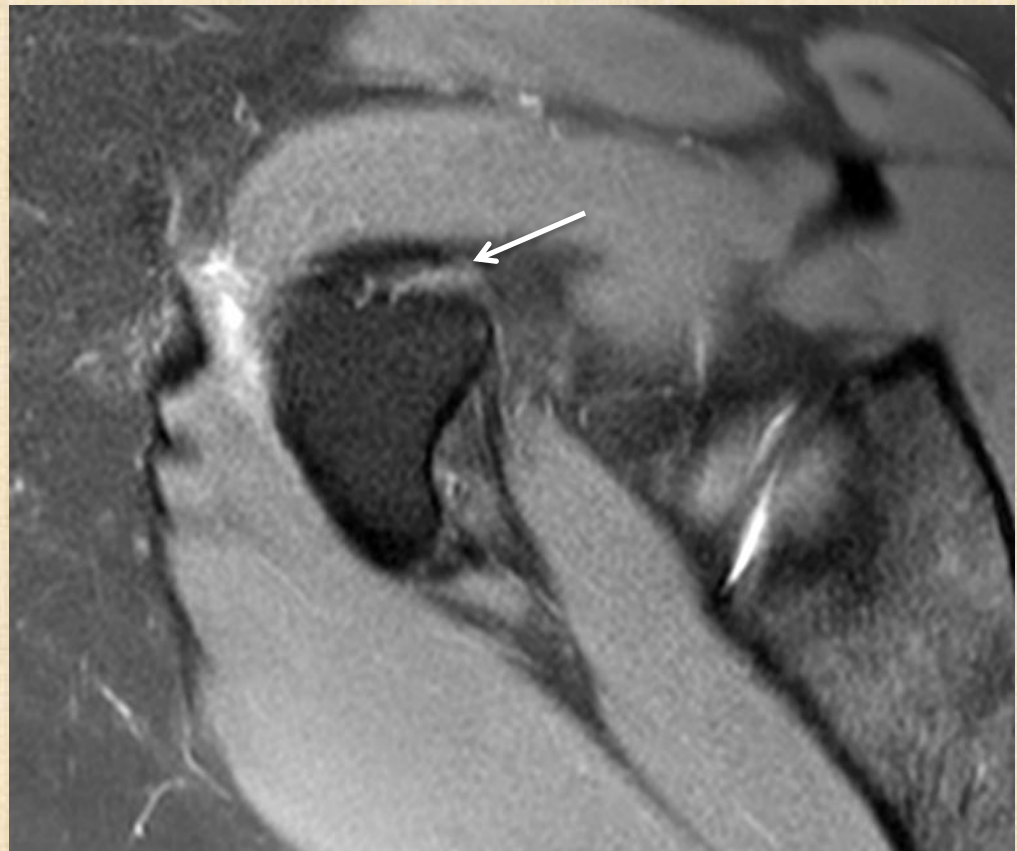
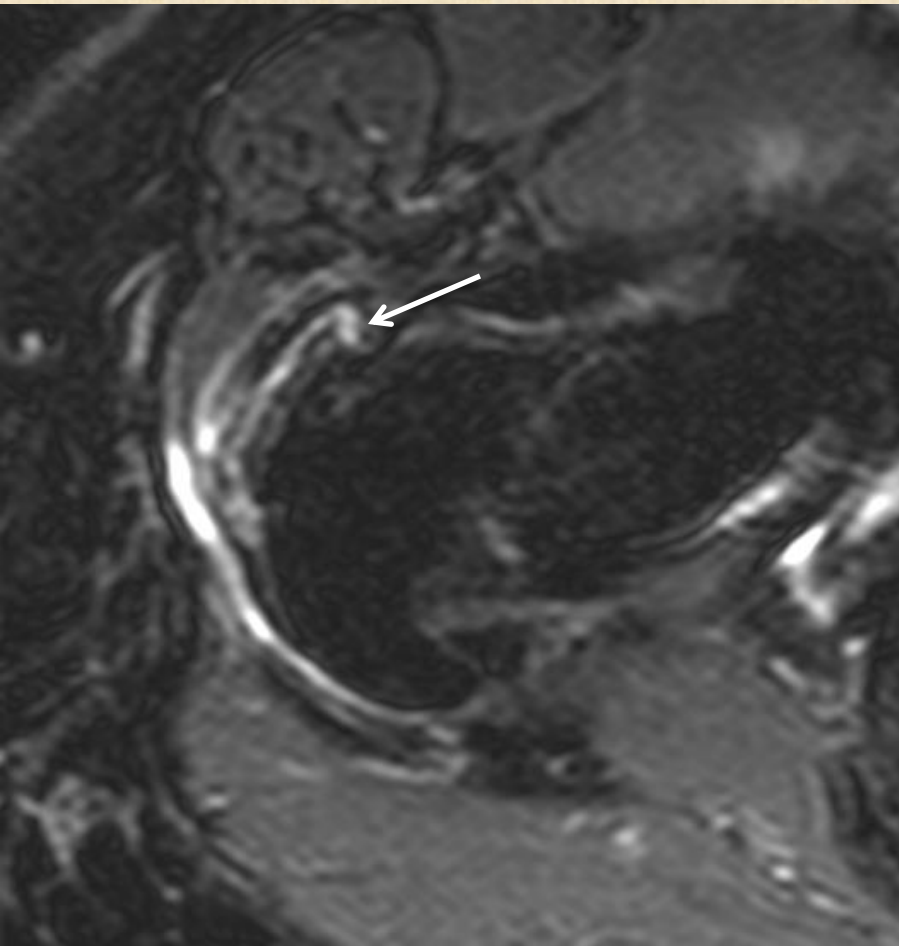
(Greater) trochanteric bursitis



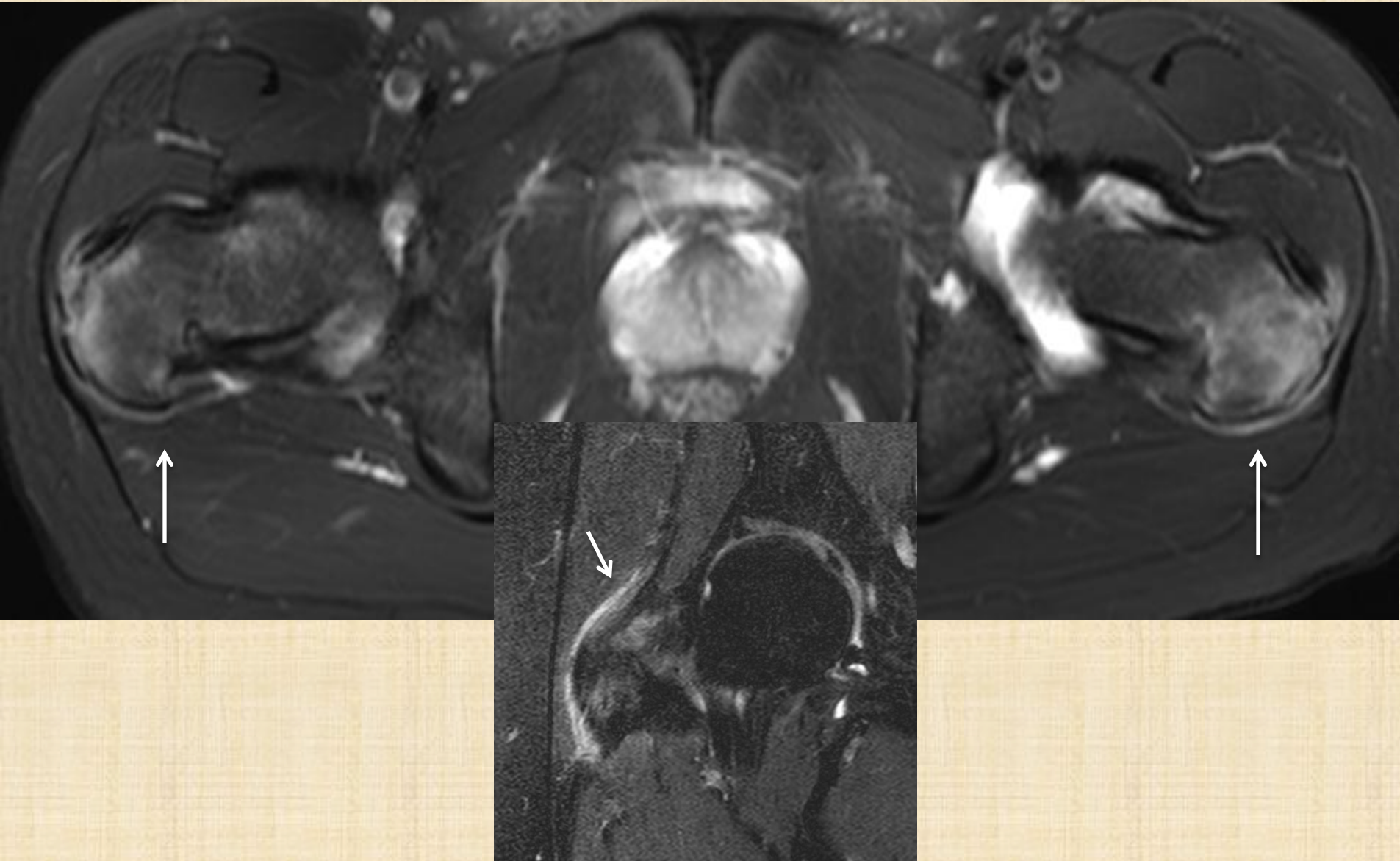
Subgluteus medimus bursitis



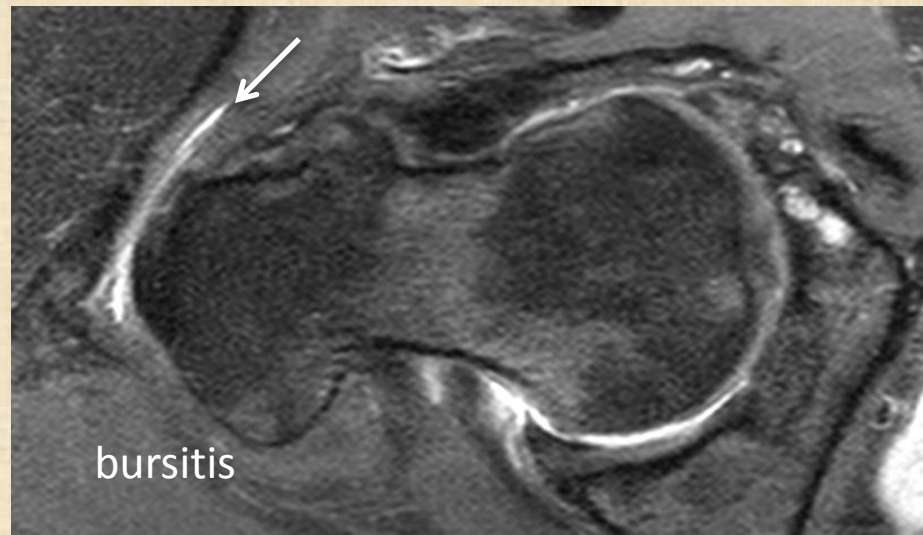
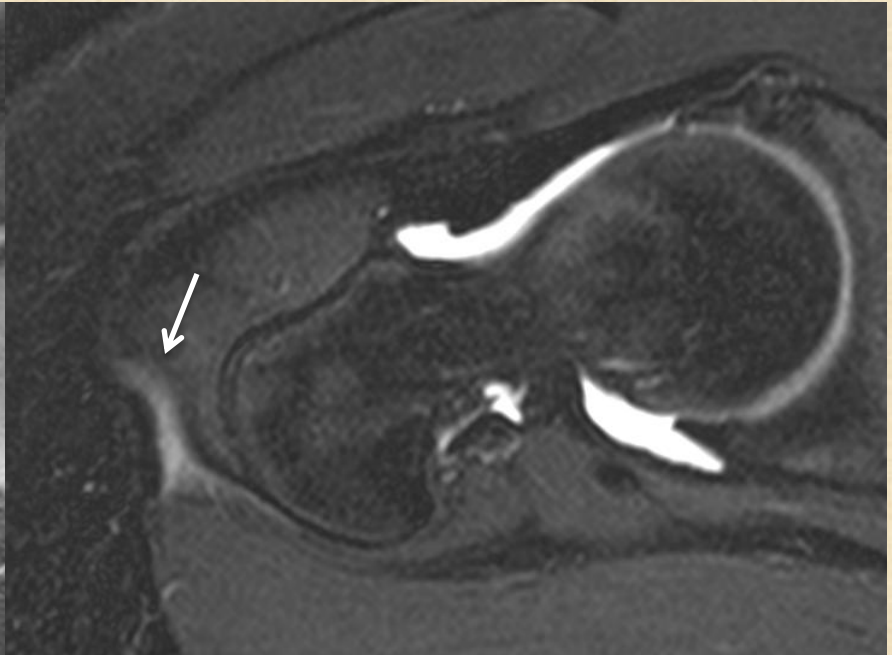
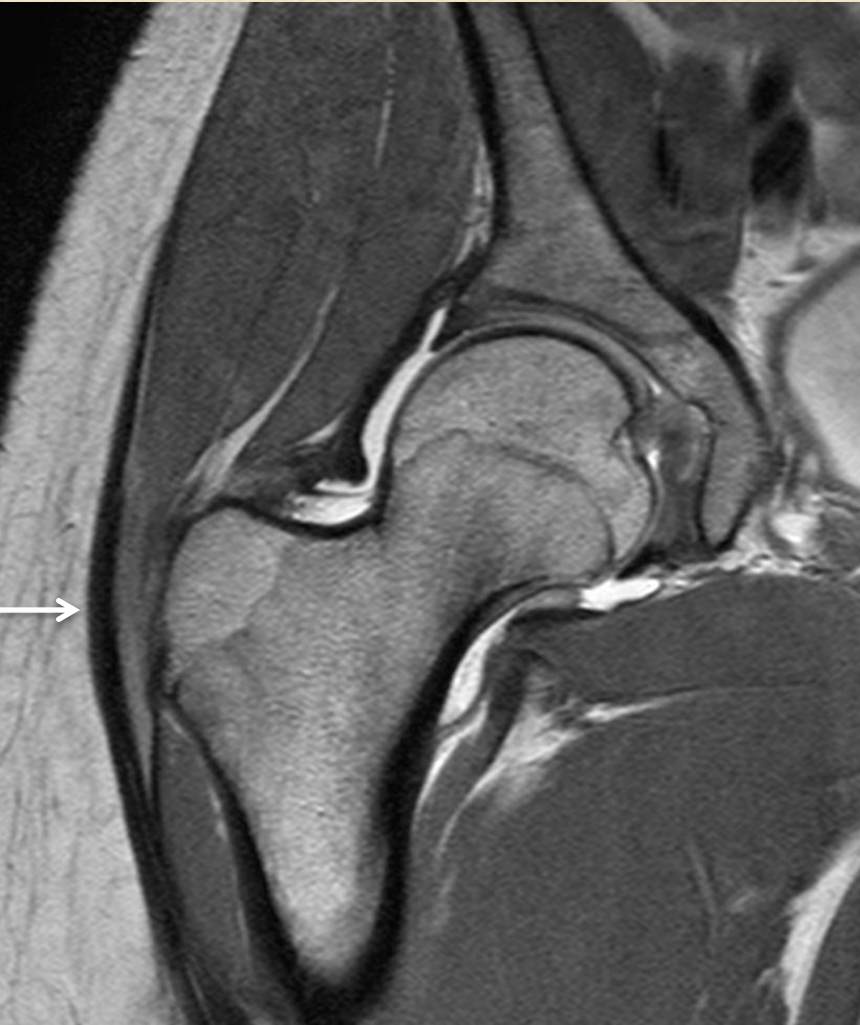Subgluteus minimus bursitis



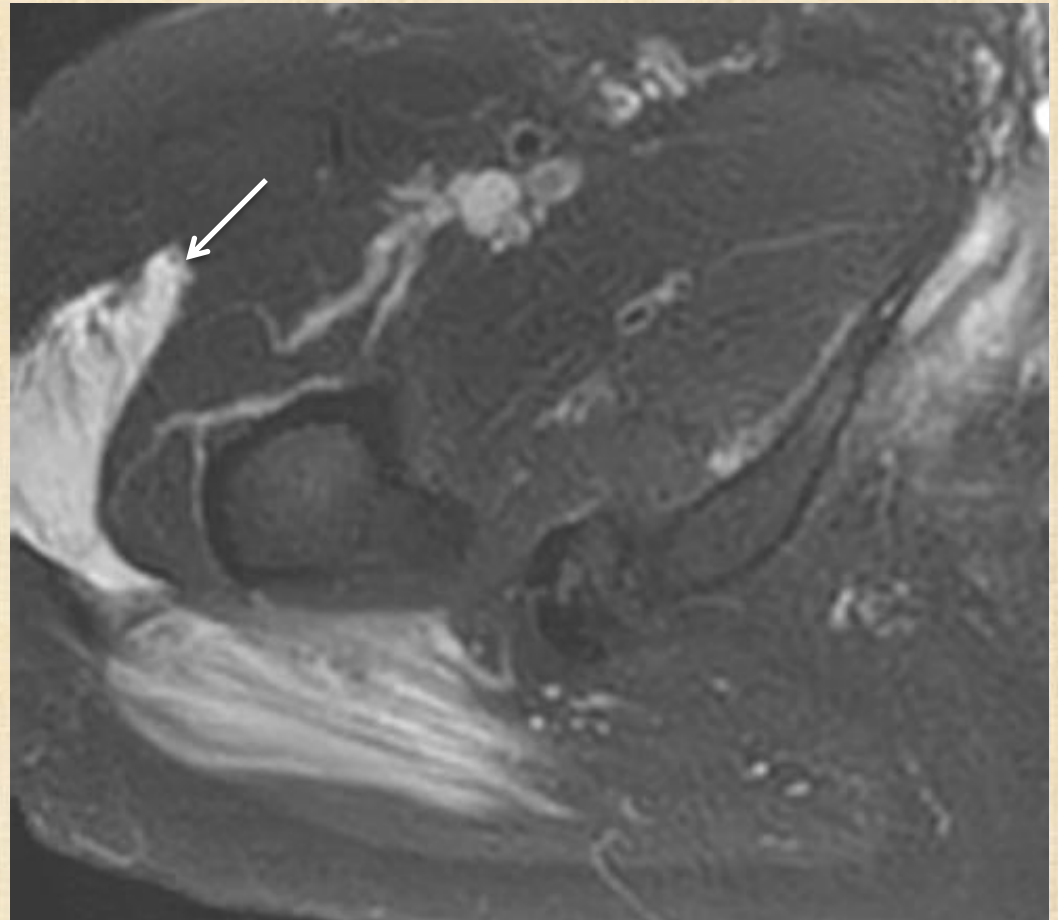
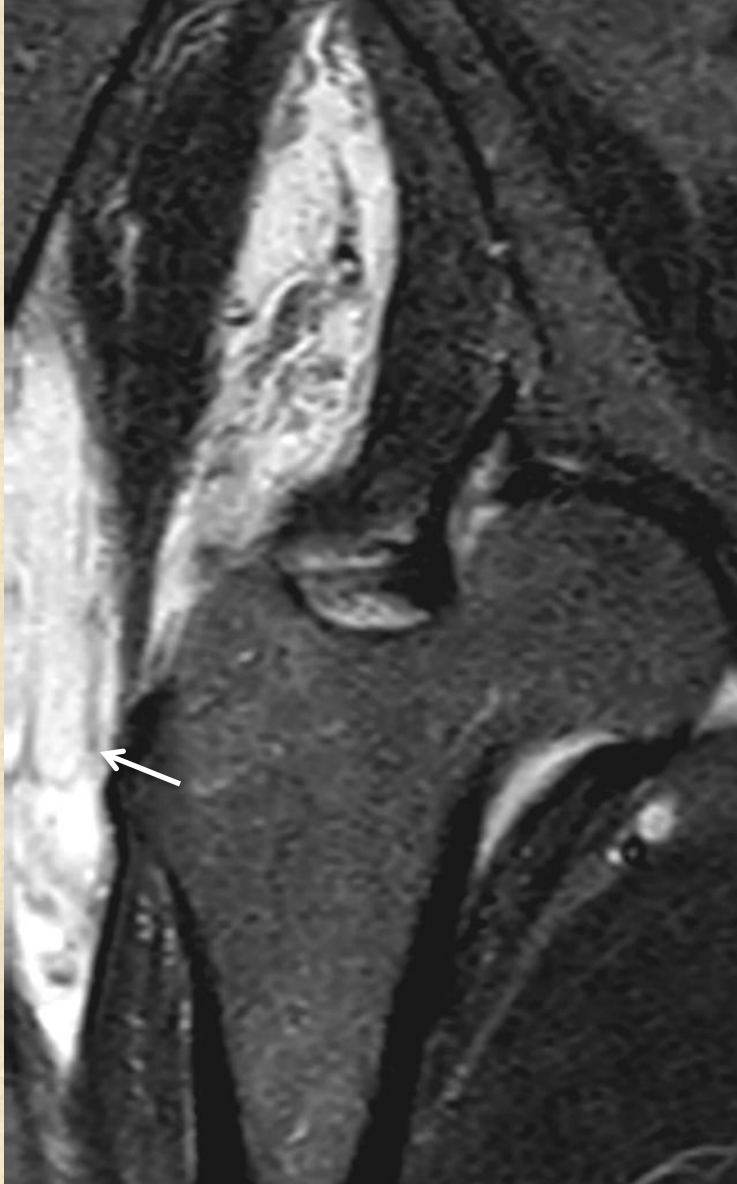Enthesopathy



Iliotibial band friction syndrome



Morel-Lavallee lesion



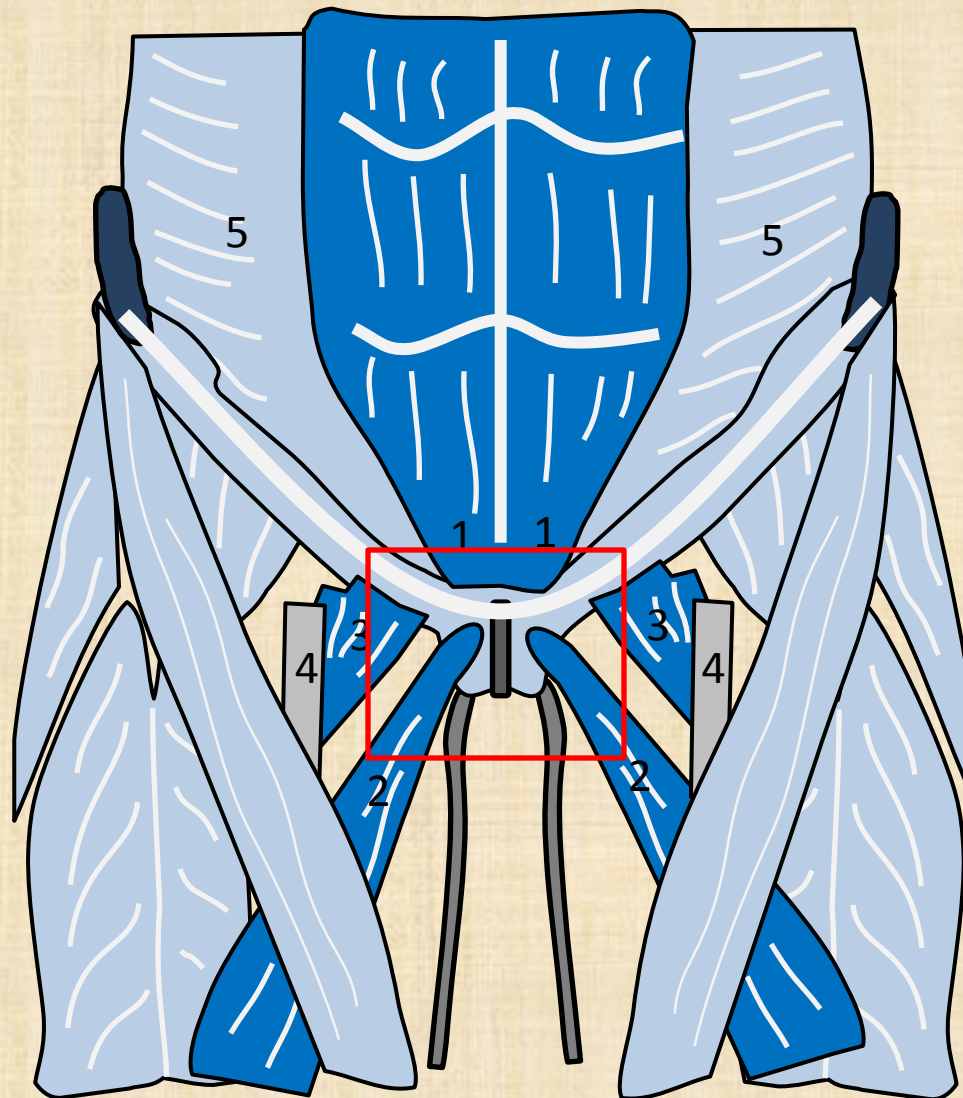
Other tendon problem

- Athletic pubalgia
- Hamstring
- Others: piriformis, obtruator interus, obtruator exterus, quadratus femoris, superior and inferior gemellus

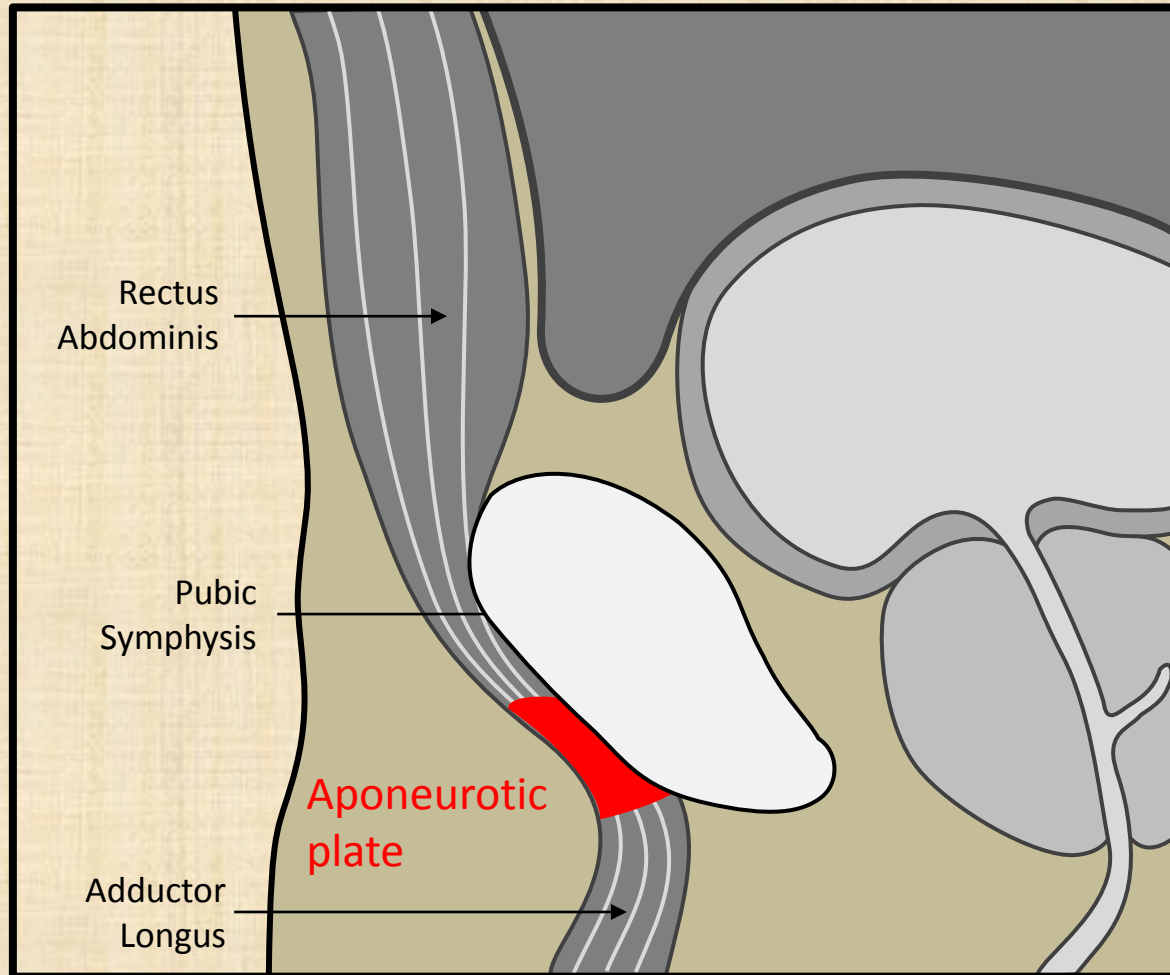
Athletic Pubalgia (sports hernia)

- Rectus abdominis/adductor aponeurosis injury (unilateral)
- Rectus abdominis/adductor aponeurotic plate disruption (bilateral)
- Adductor tendon syndromes
- Rectus abdominis sprain
- Osteitis pubis

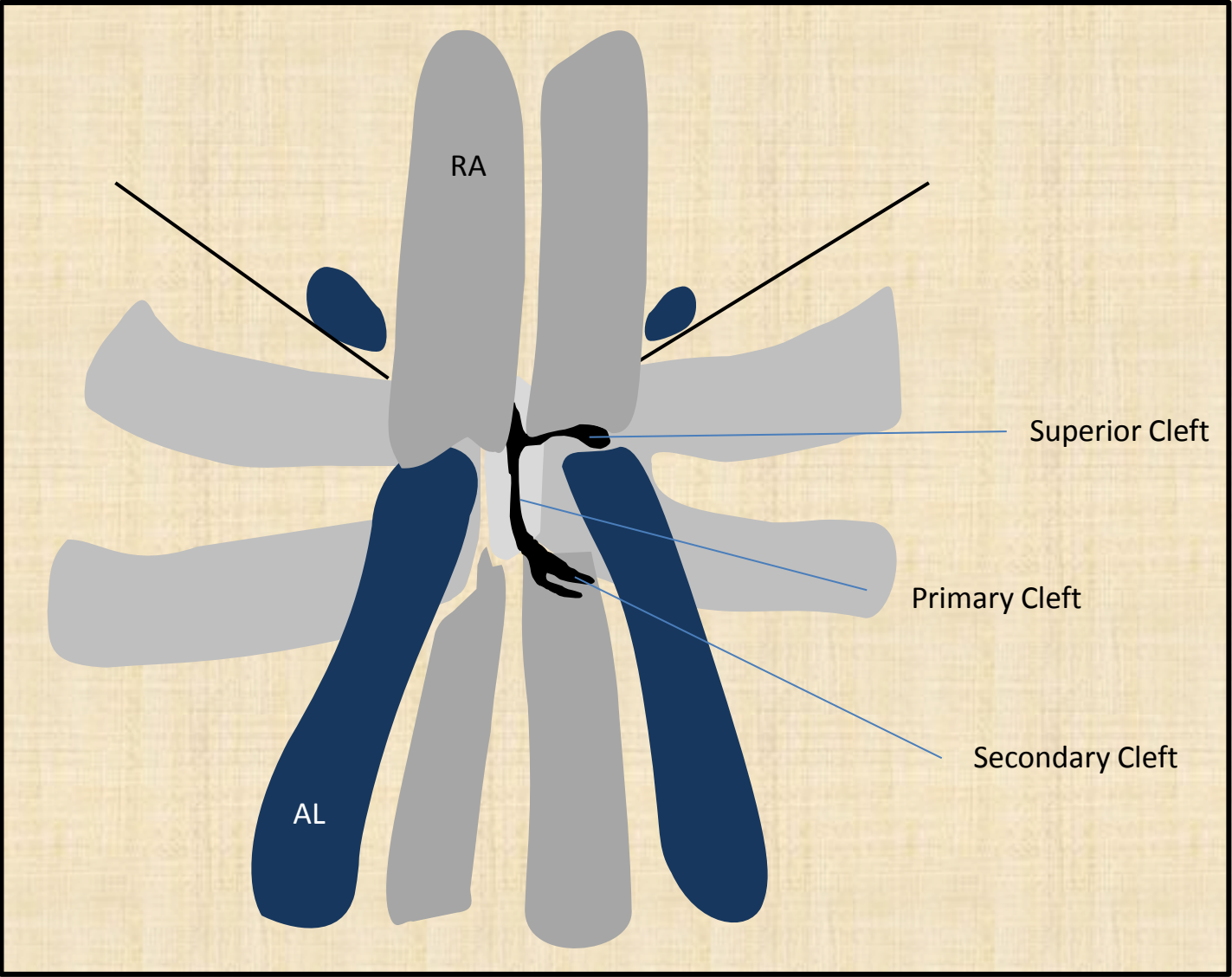
Sports hernia



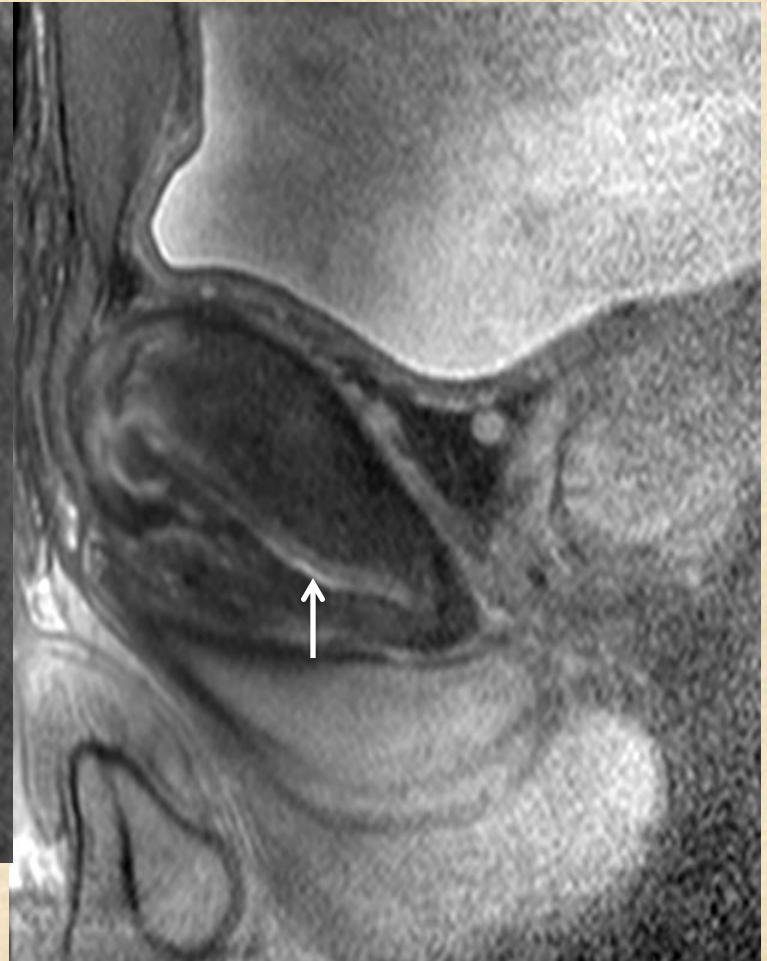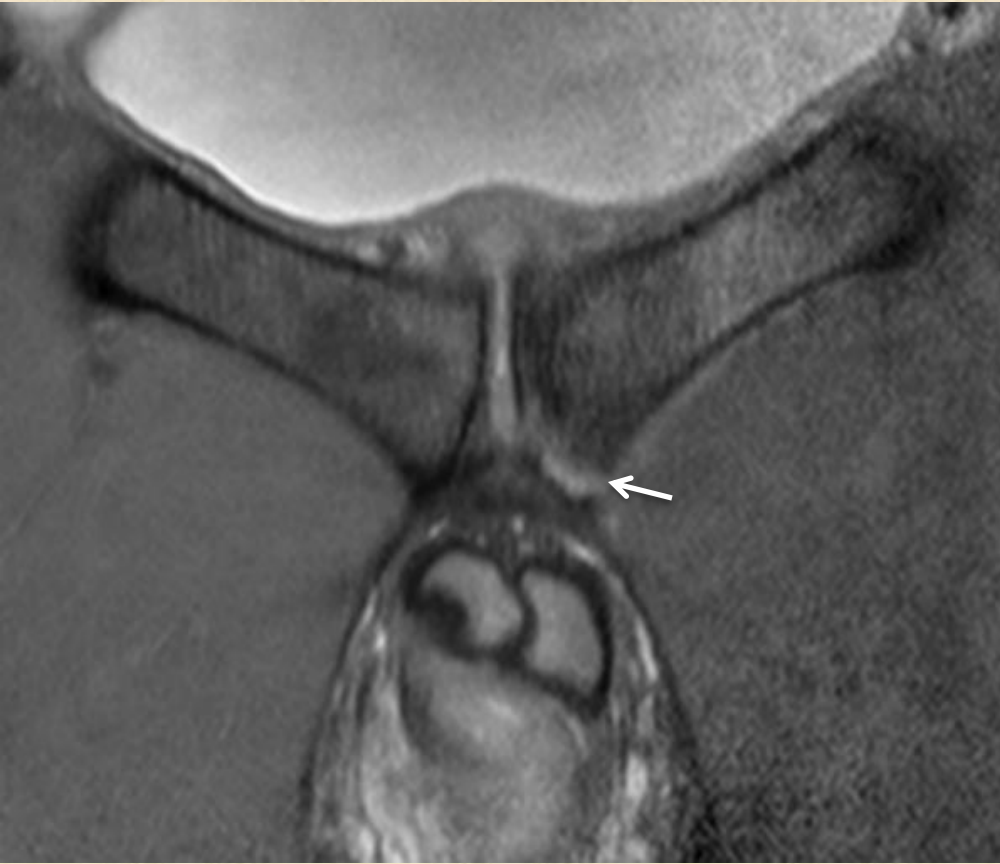Aponeurotic plate



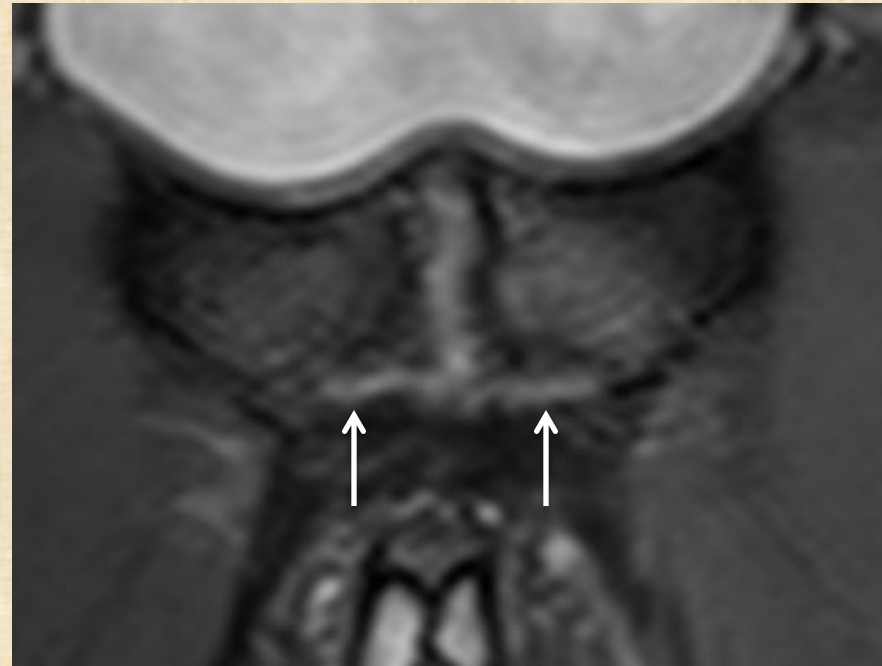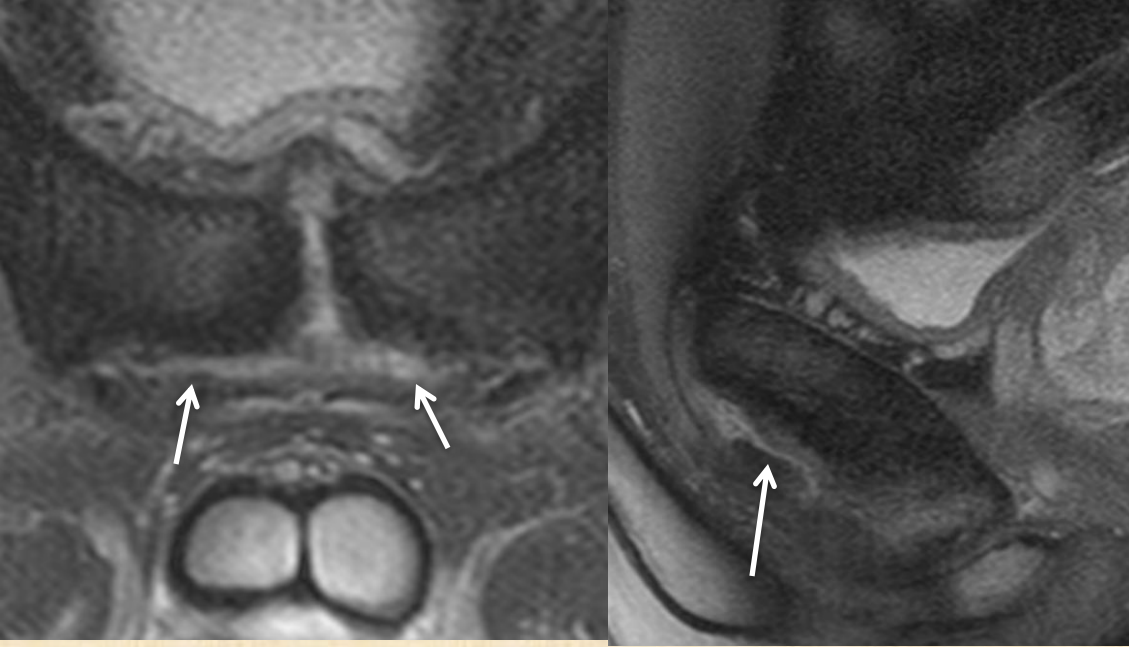
Tear



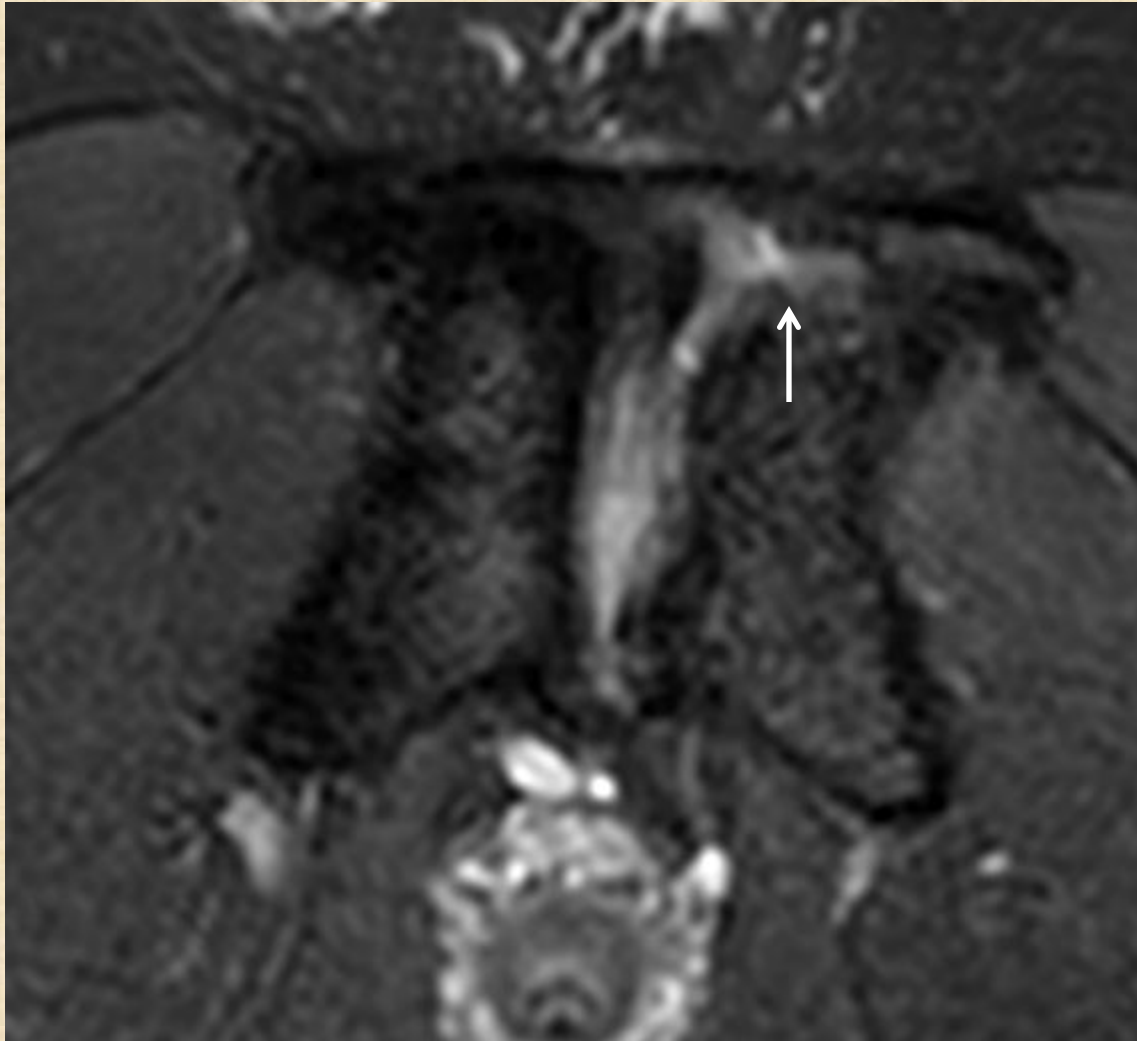
Unilateral plate disruption



Bilateral plate disruption

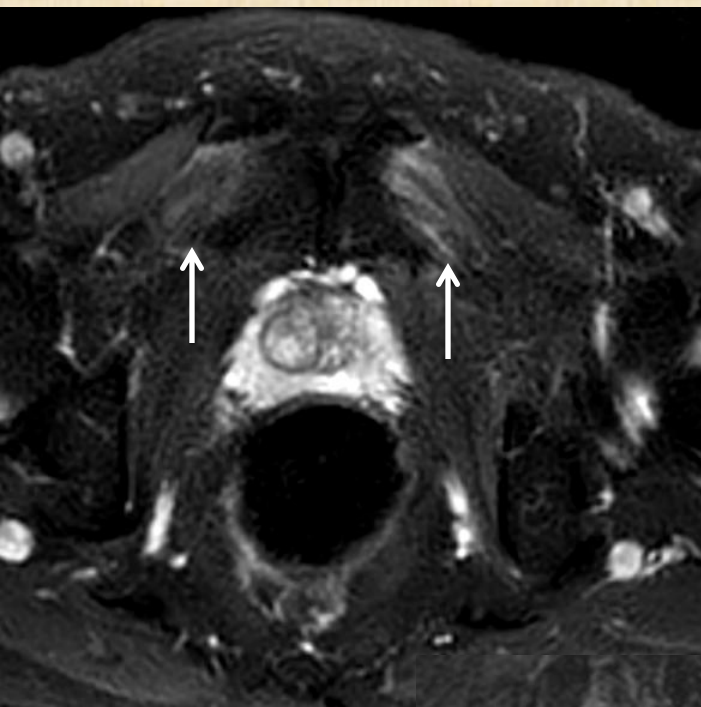


Superior cleft

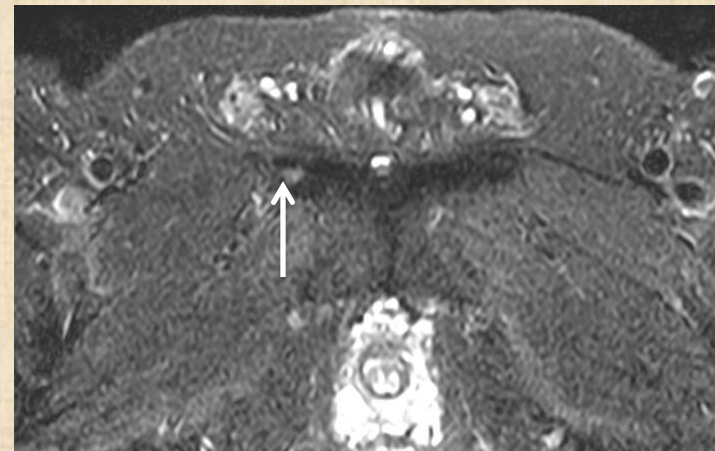

Axial

Adductor tendon syndrome

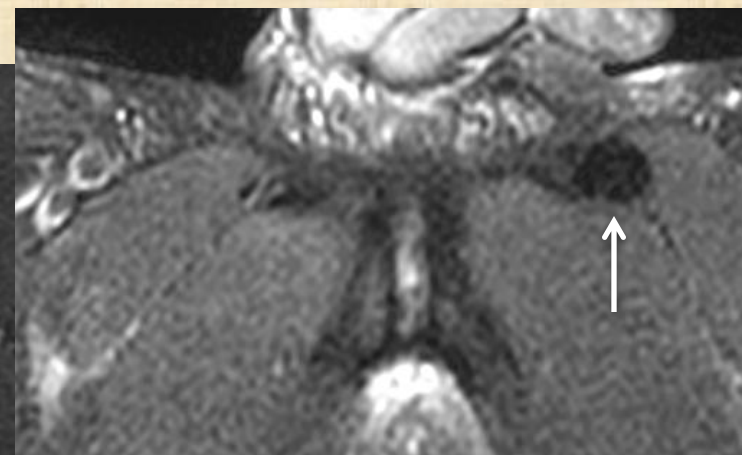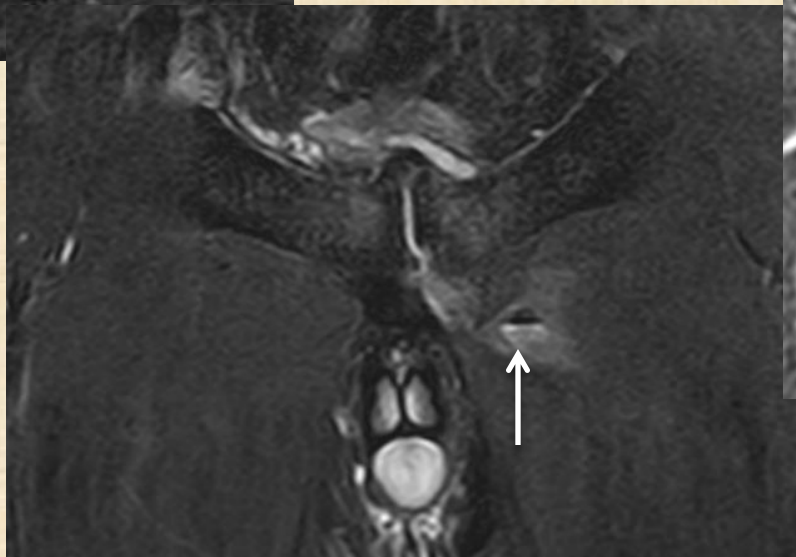


Sprain

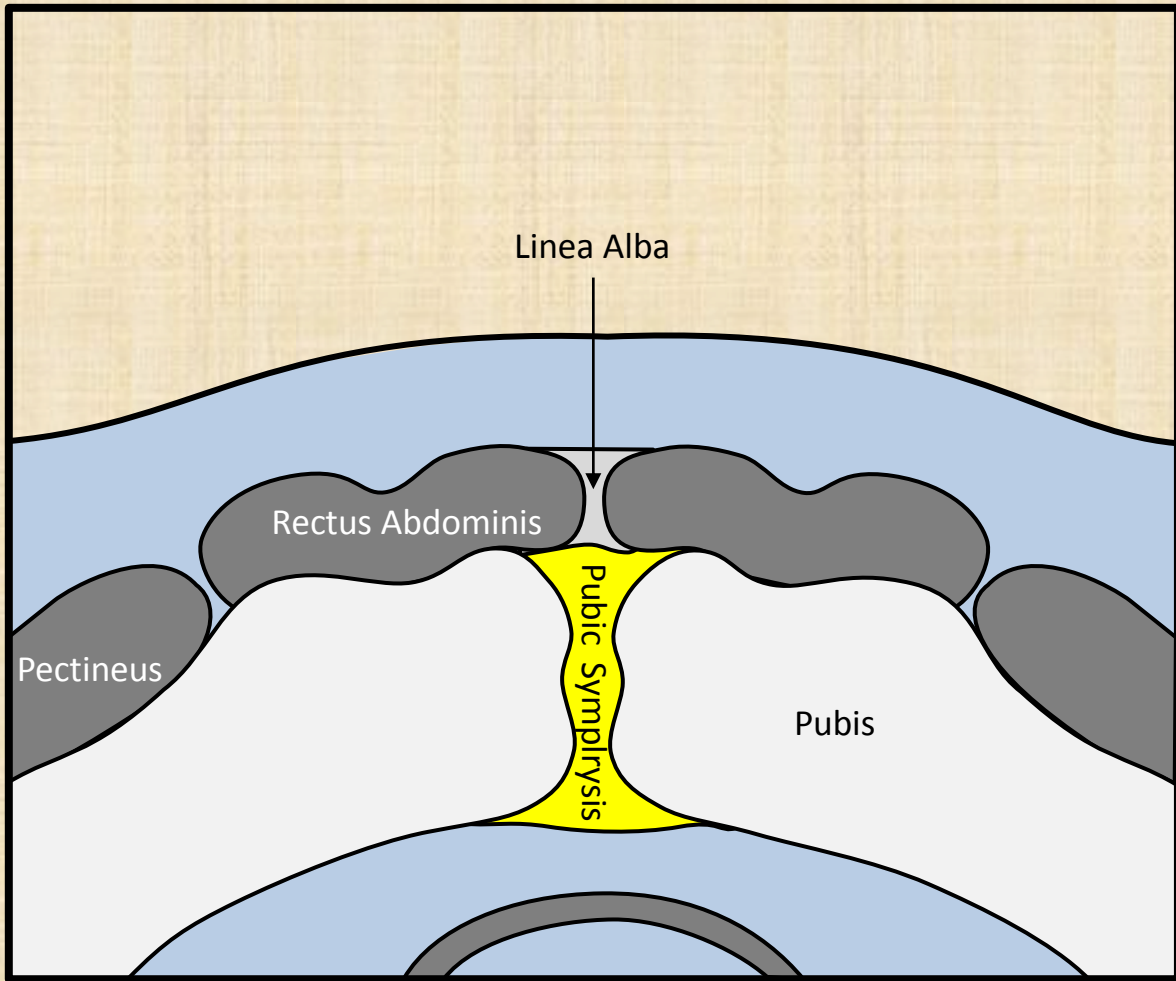


Tear

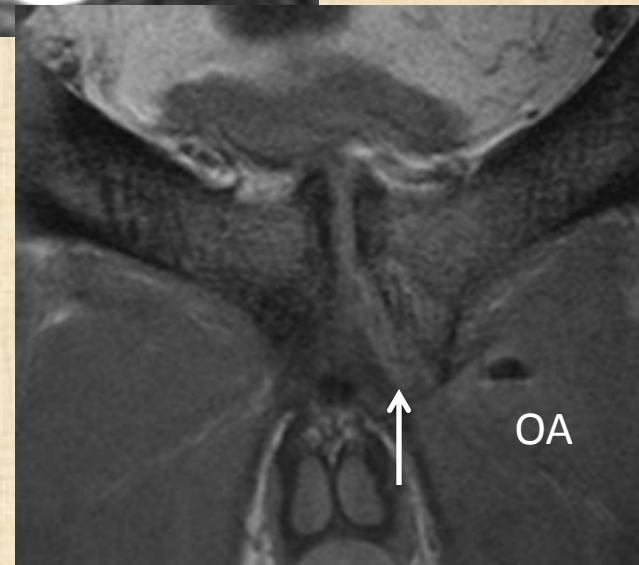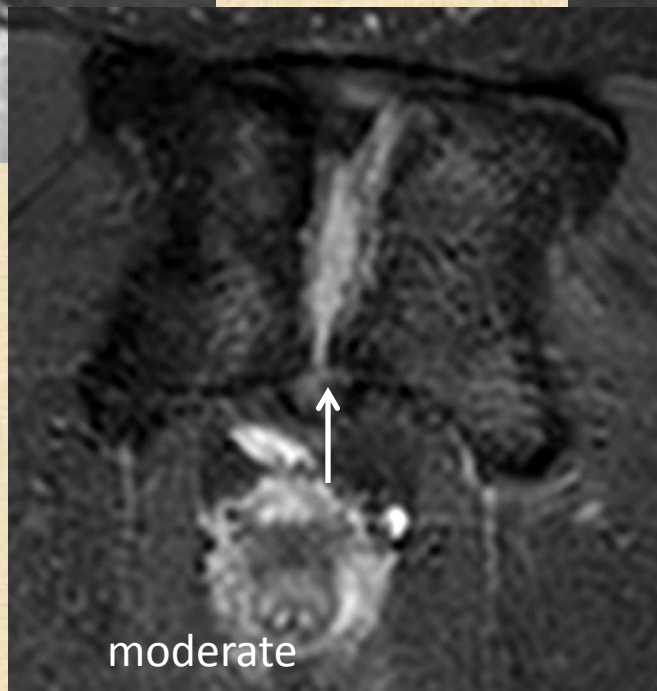
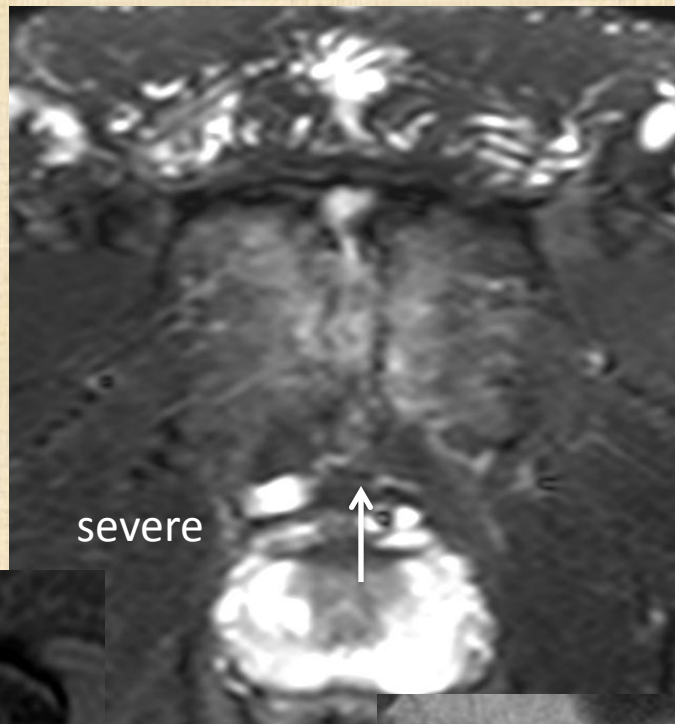
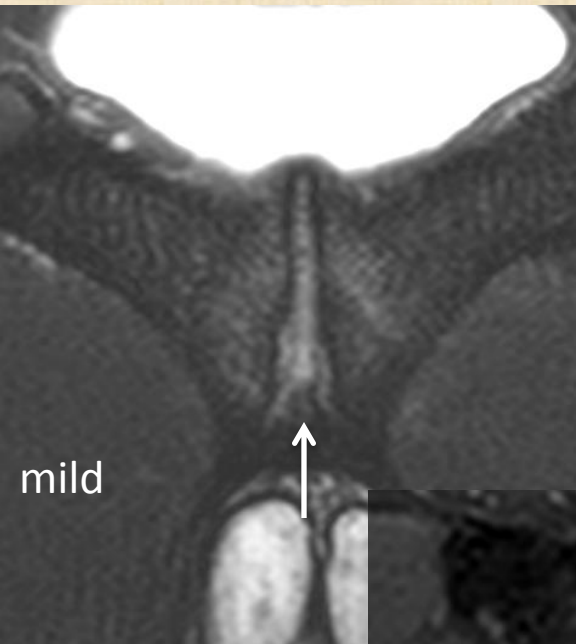
Tear with
hematoma



Tendinosis



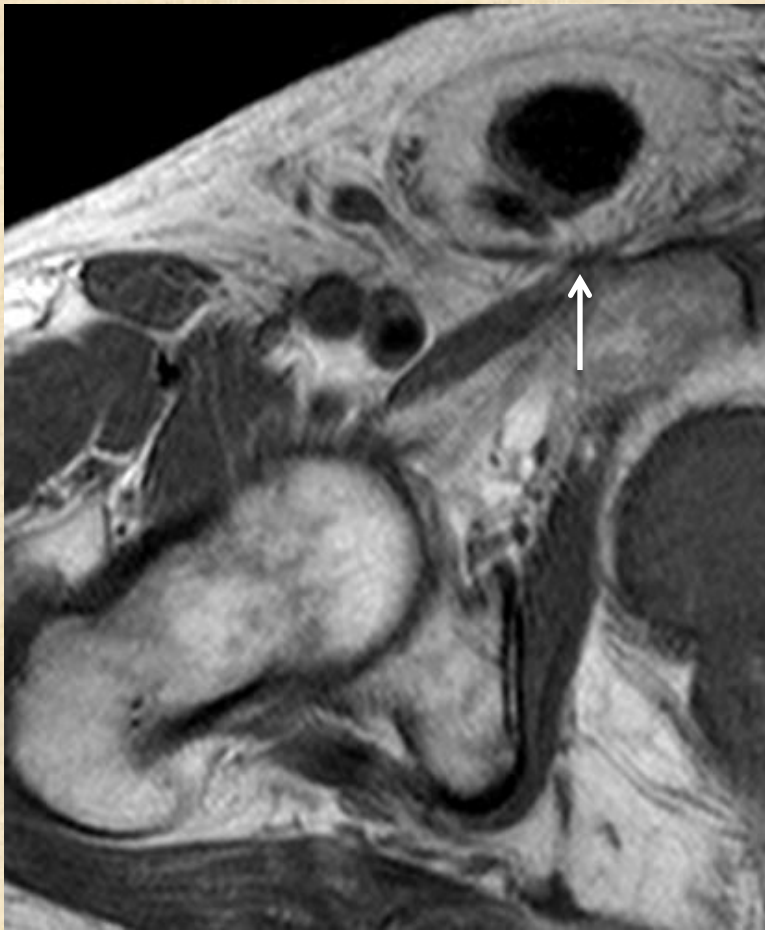
Osteoitis pubis



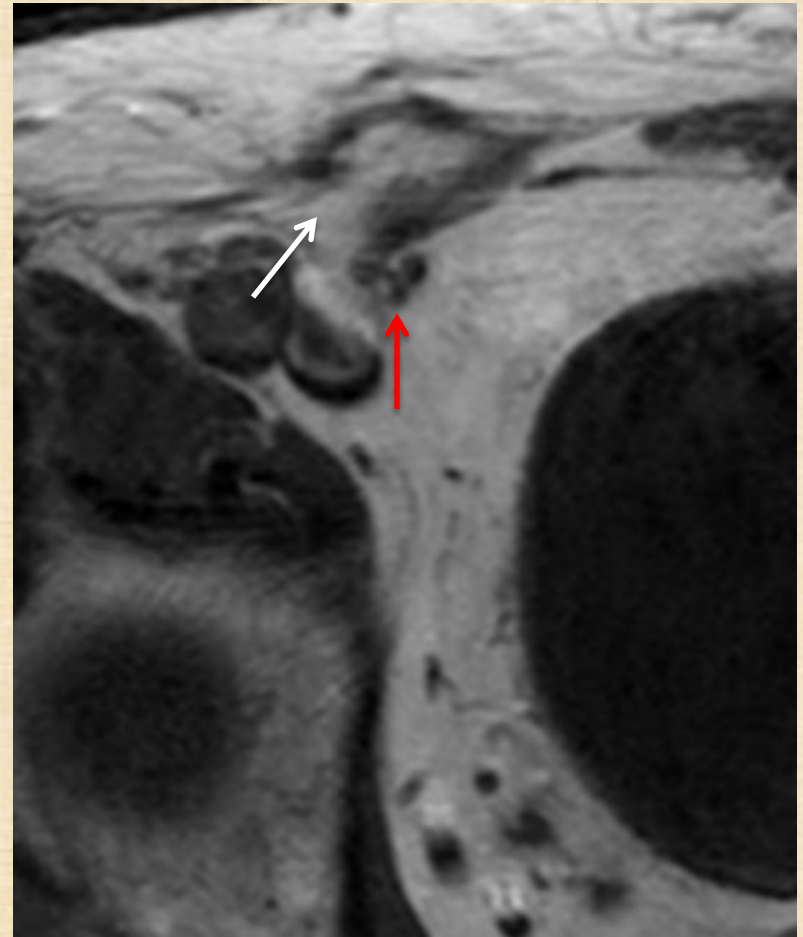
DDx

- Inguinal hernia

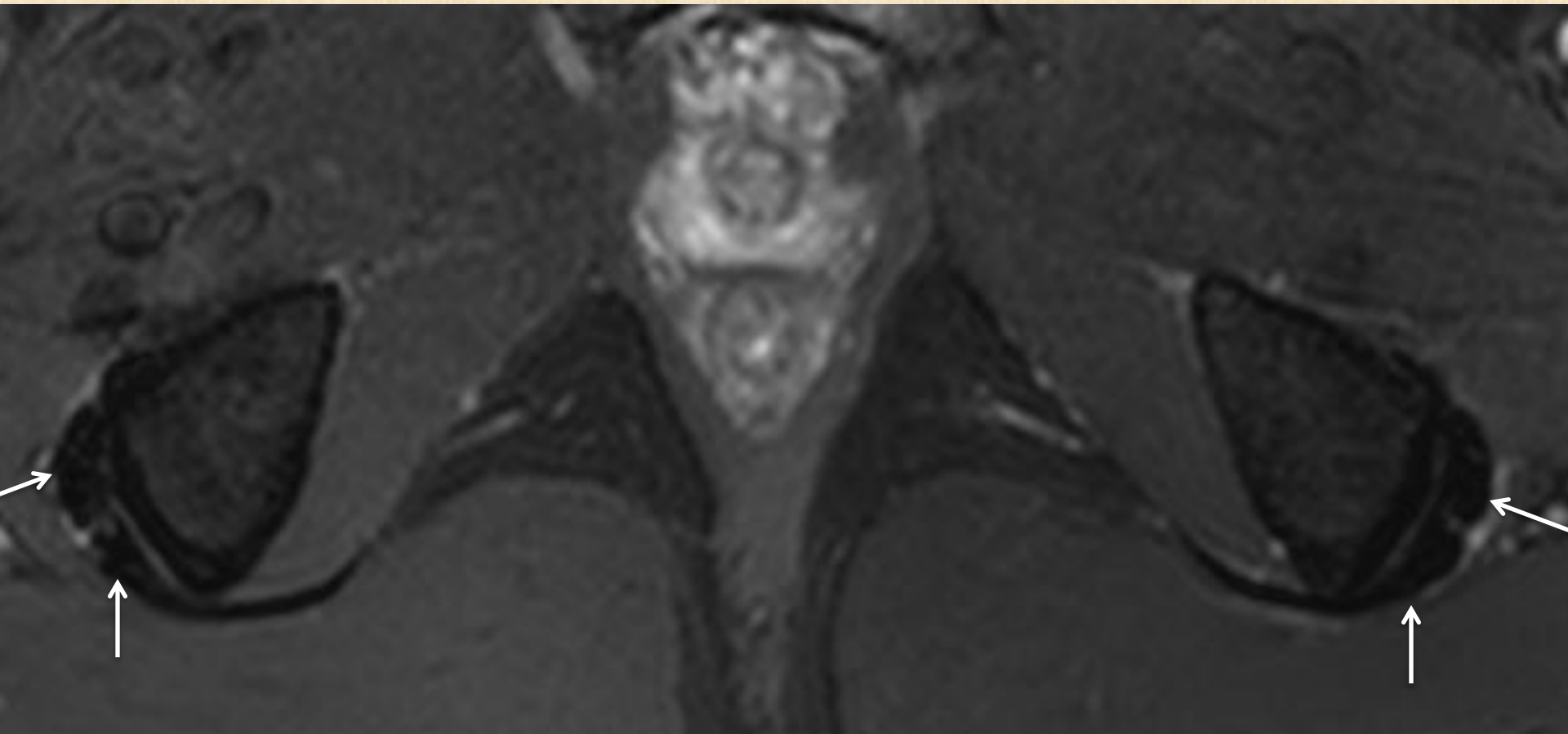
Direct

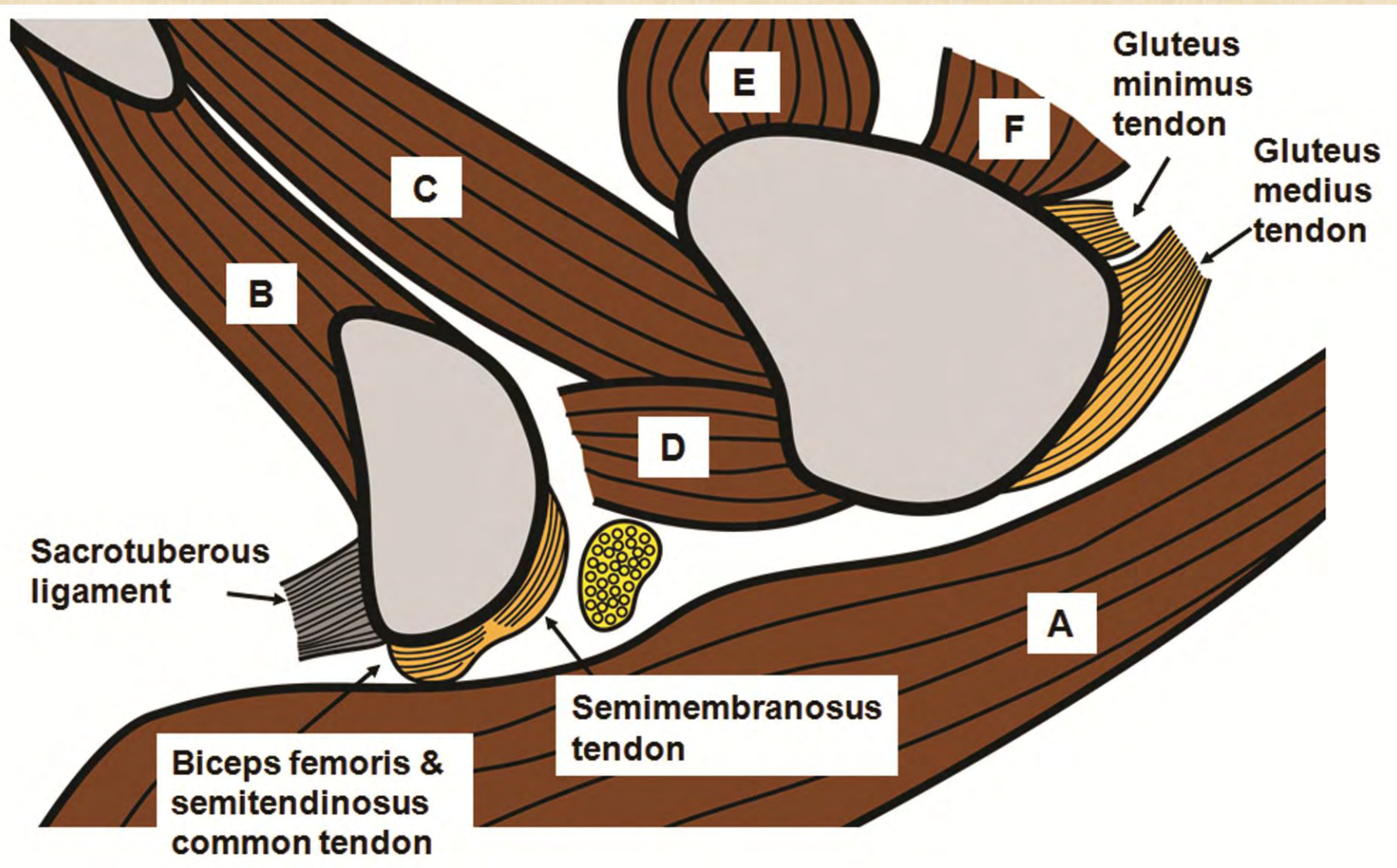


Indirect

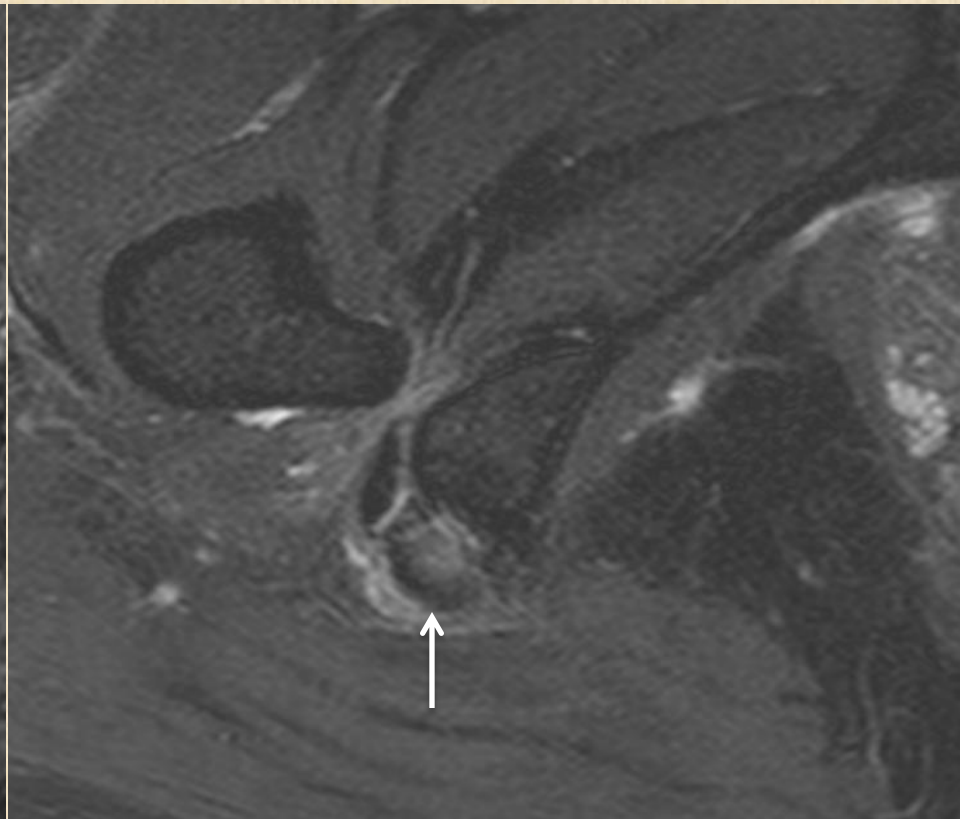
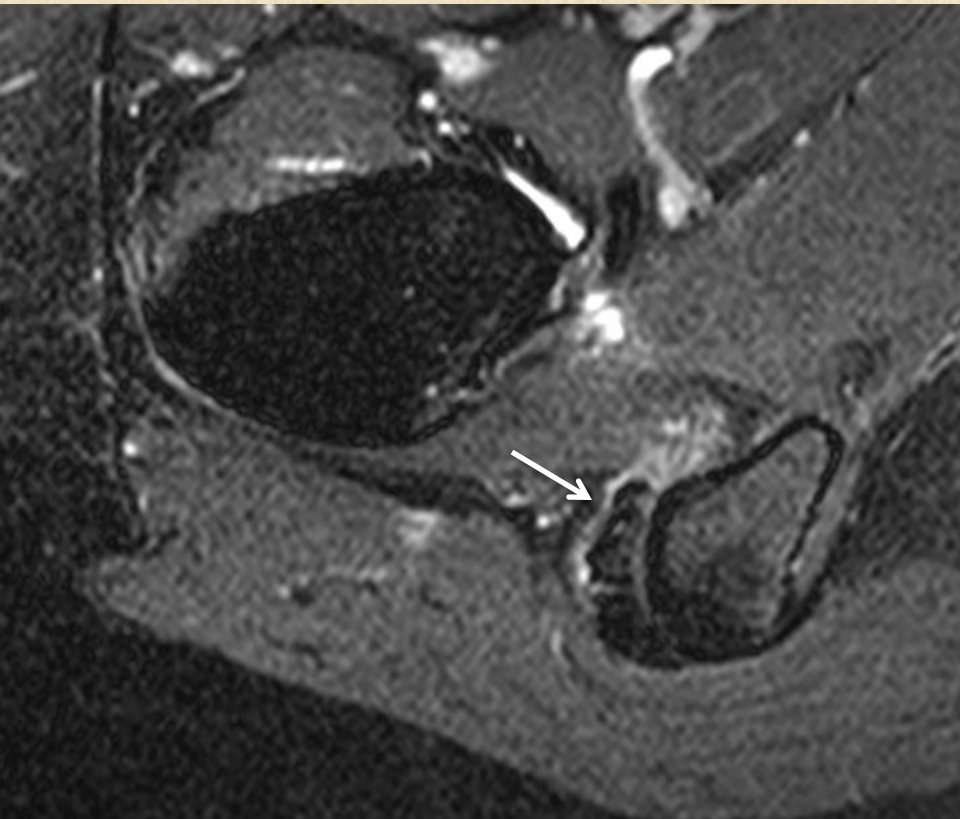


Hamstring tendinosis and tear

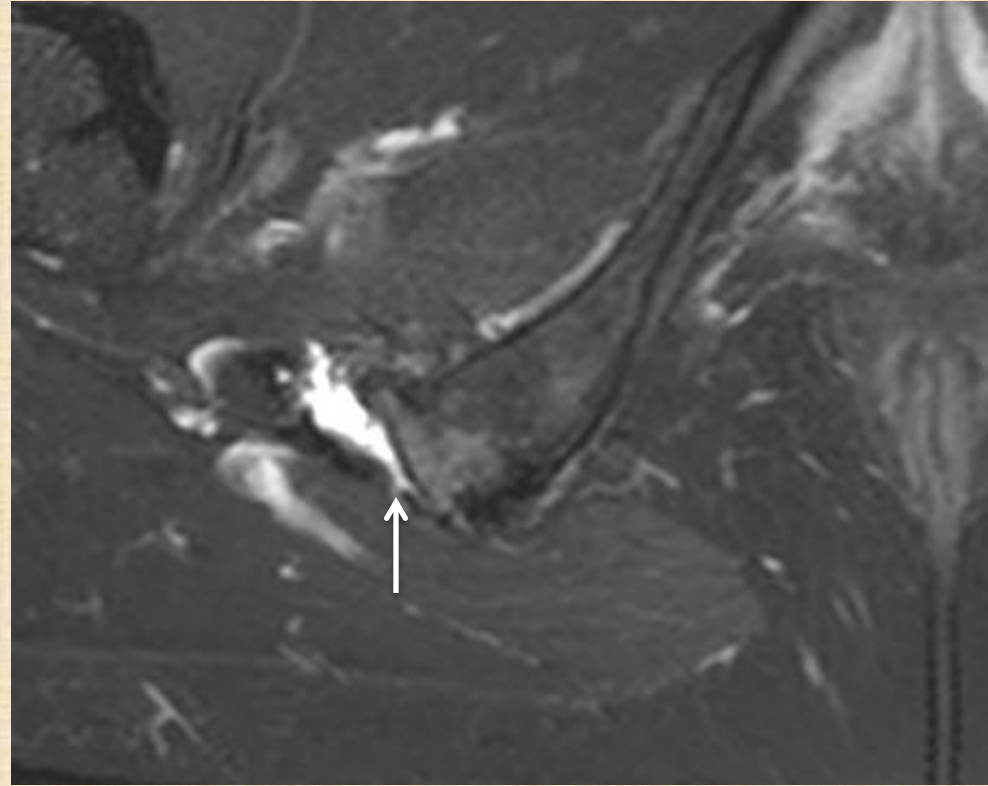
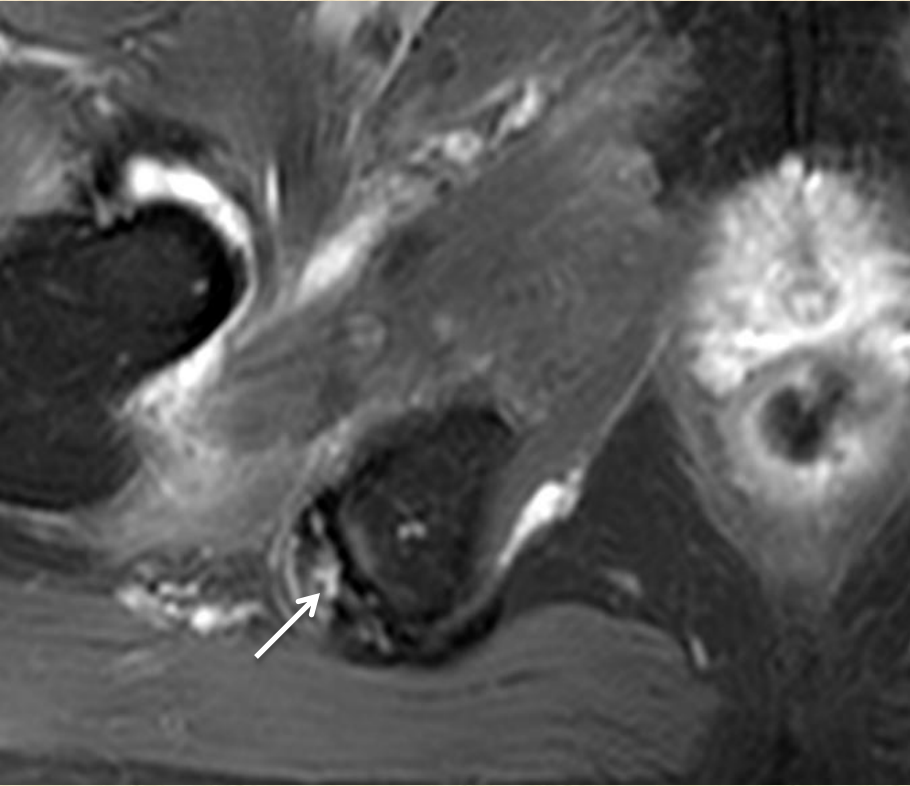




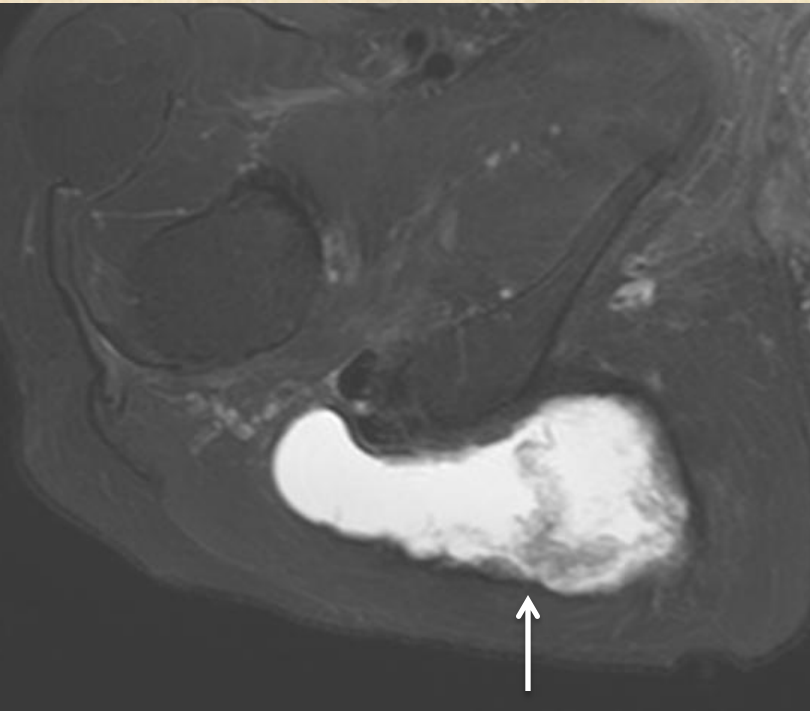
Tendinosis



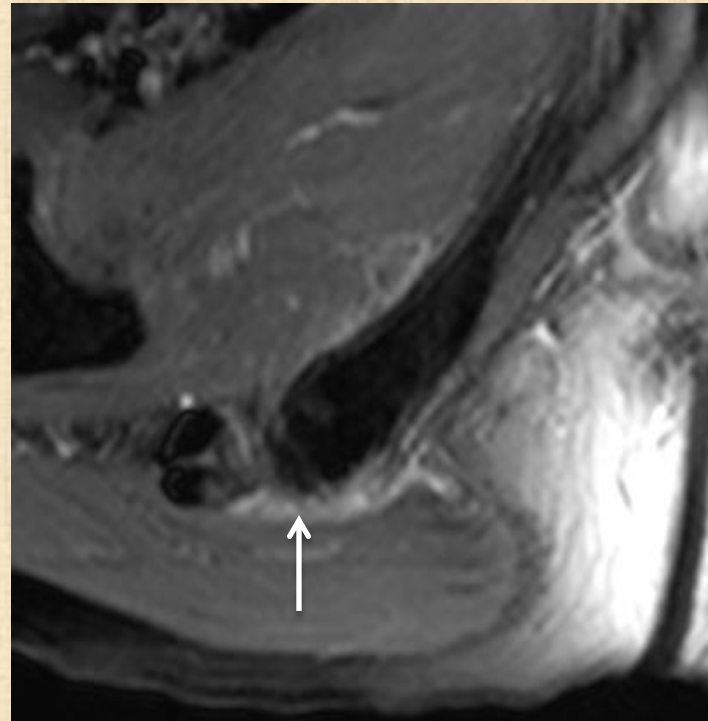
Tear



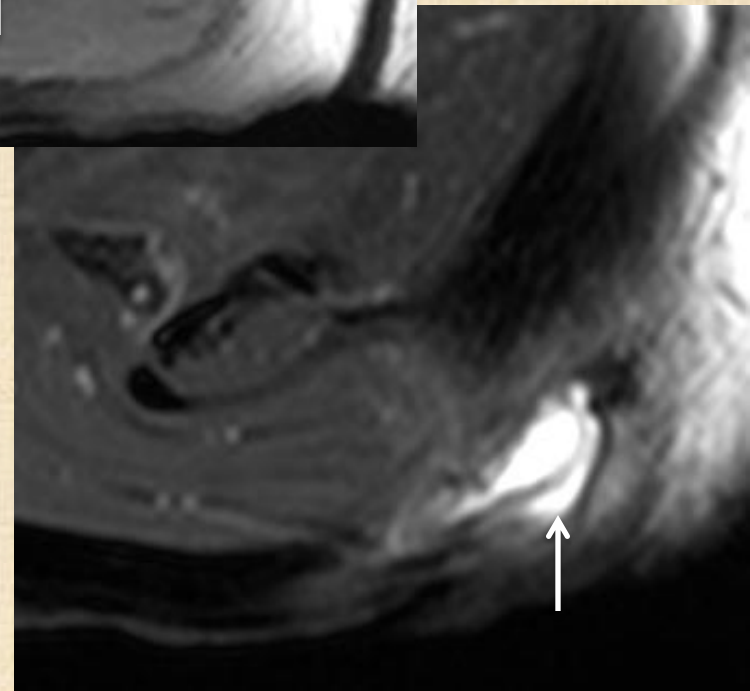
Ischial bursitis



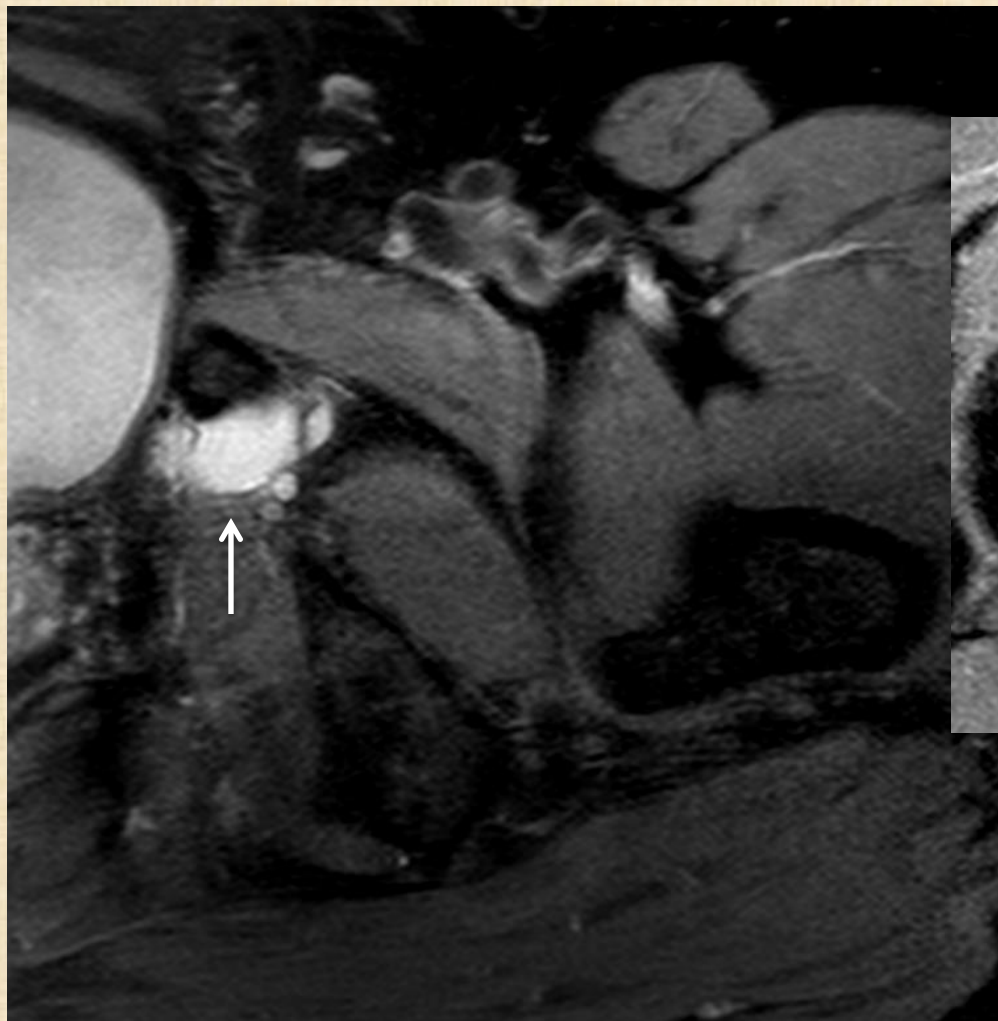
Chronic bursitis with prior hemorrhage / infection



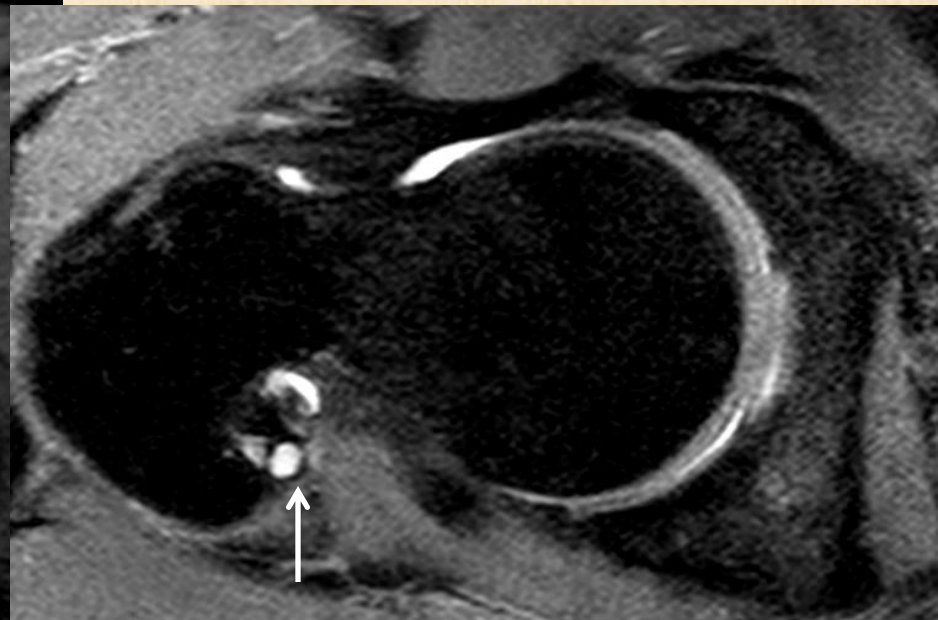
Bursitis with rupture



Other cysts



Obturator cyst

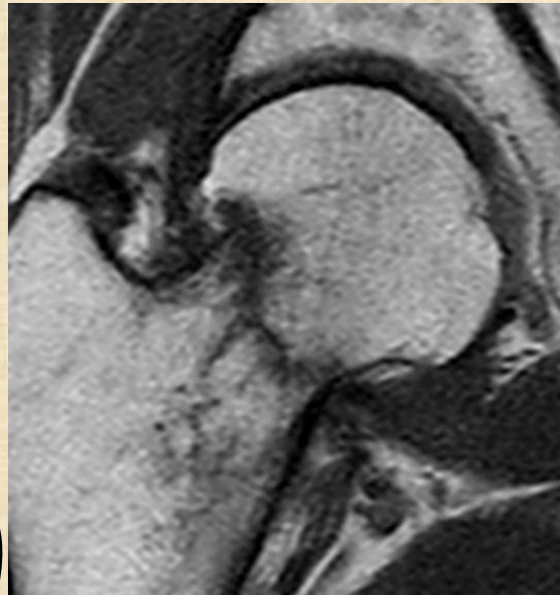
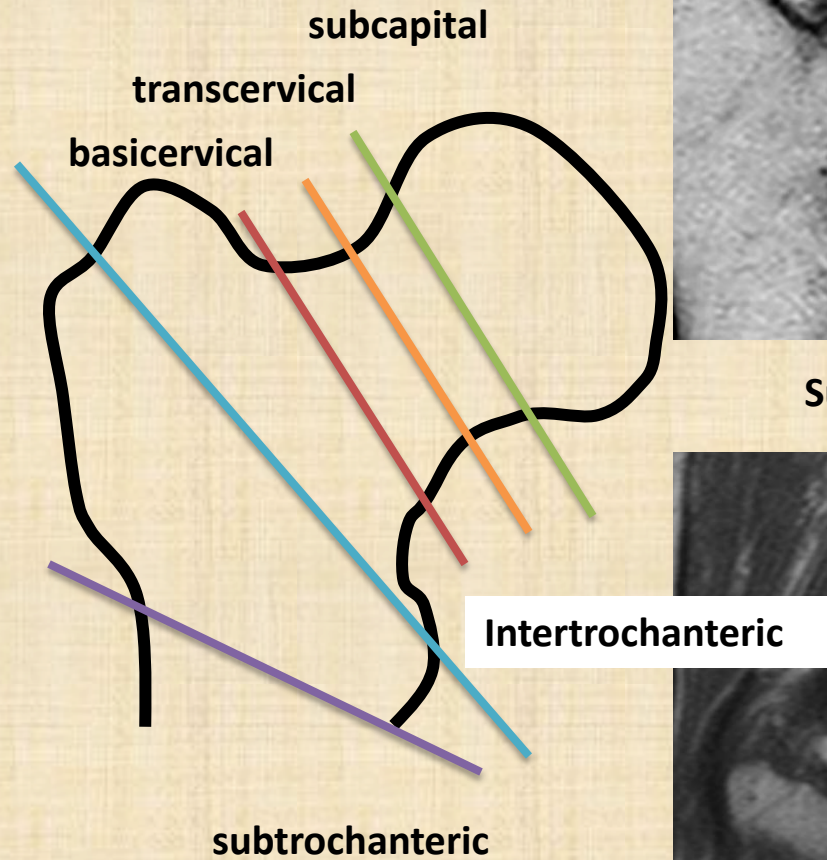


Externus tendon
insertion cyst

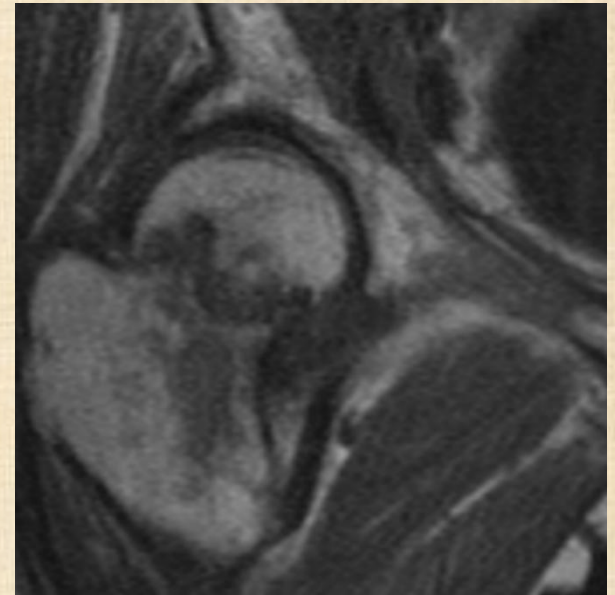
D. Hip fracture

- MRI only indicated
 - Occult fracture ? (XR : no fracture)
 - Greater trochanteric fracture :
Intertrochanteric extension ?
- CT vs MRI

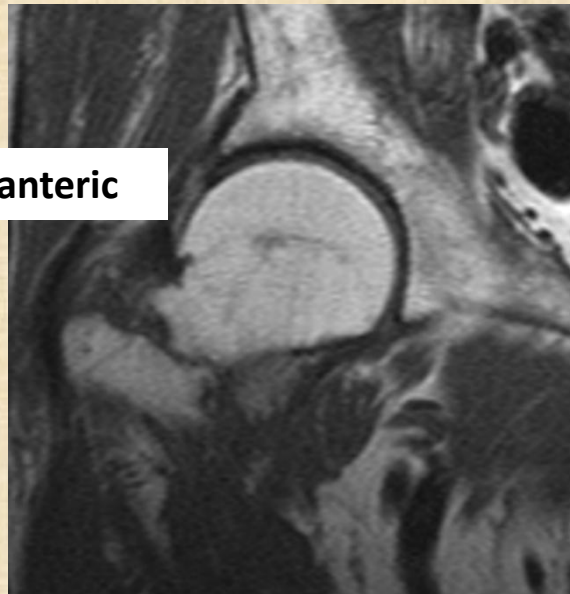
Types



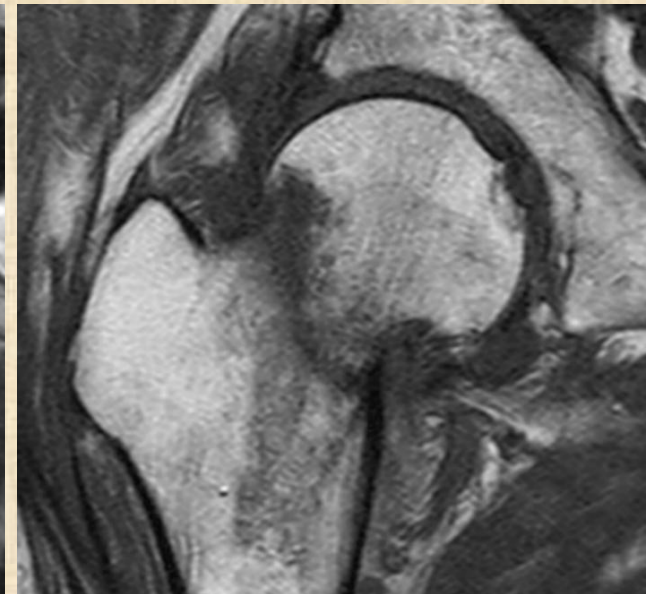
Subcapital



Transcervical

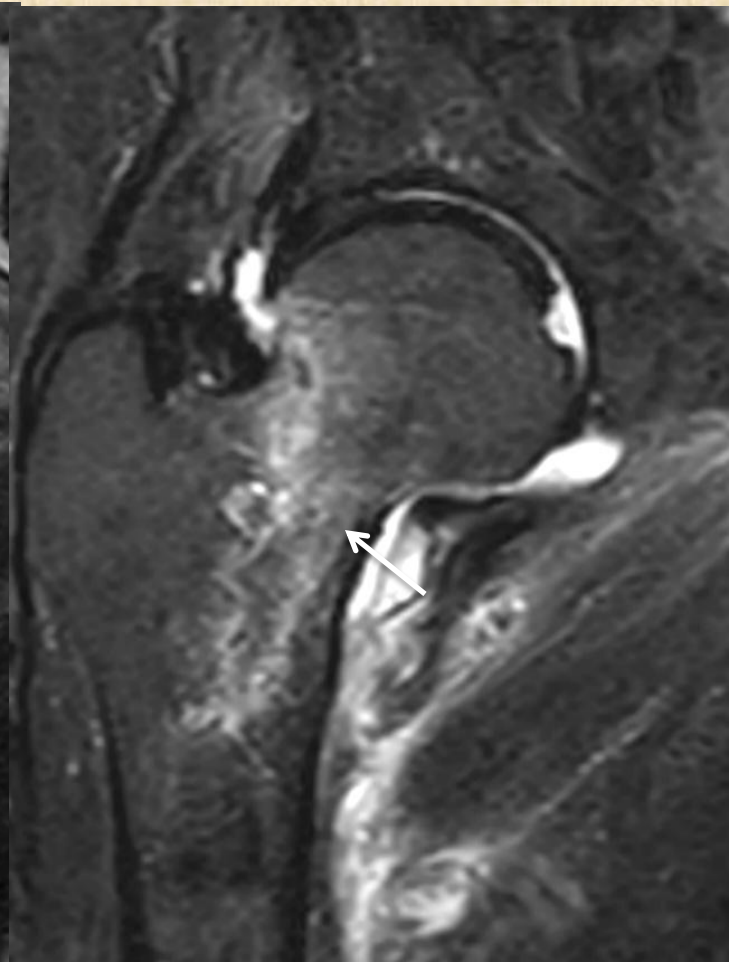
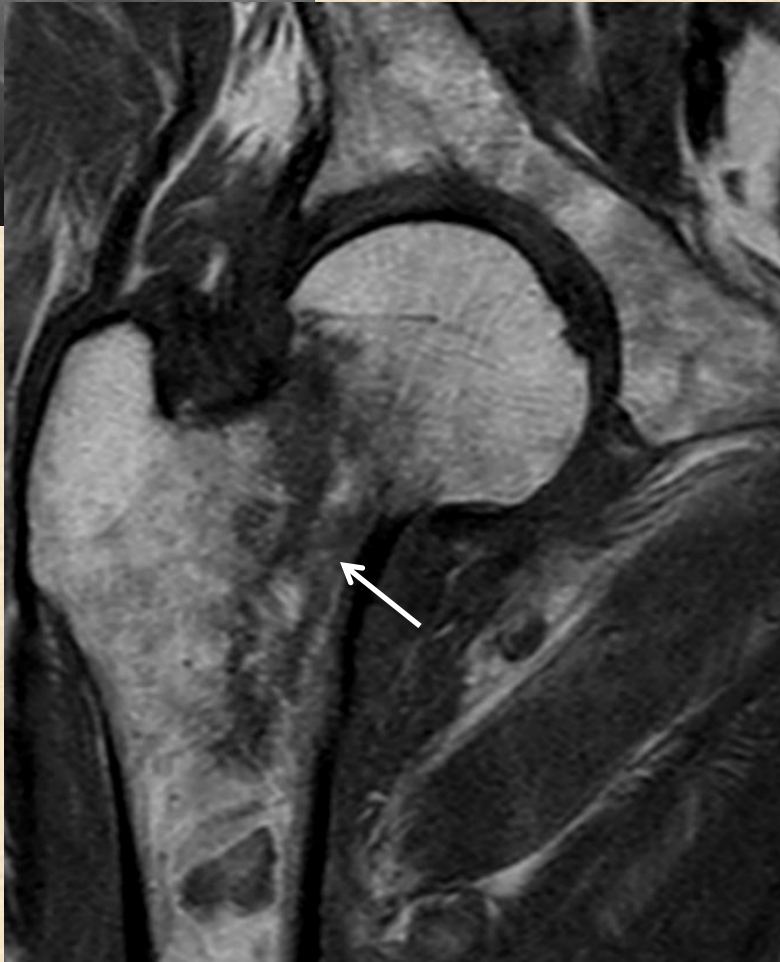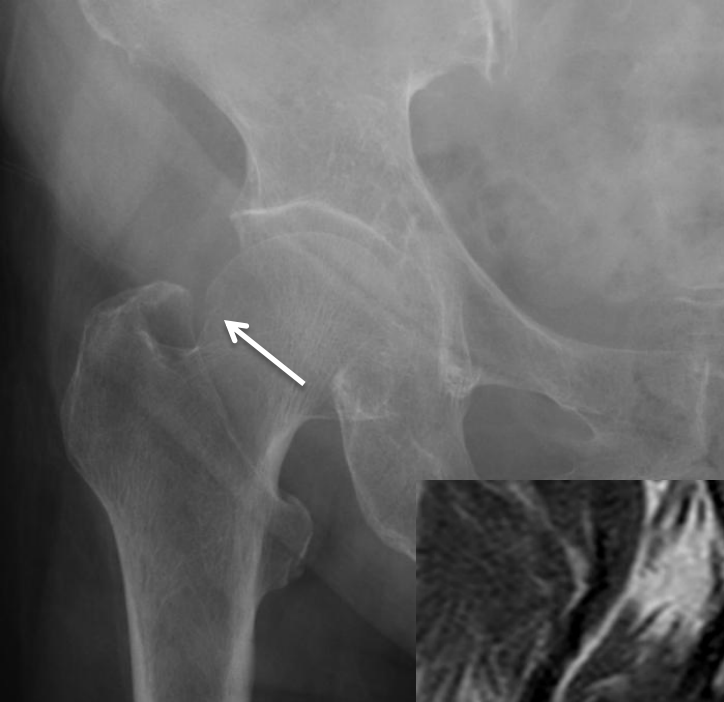


Basicervical

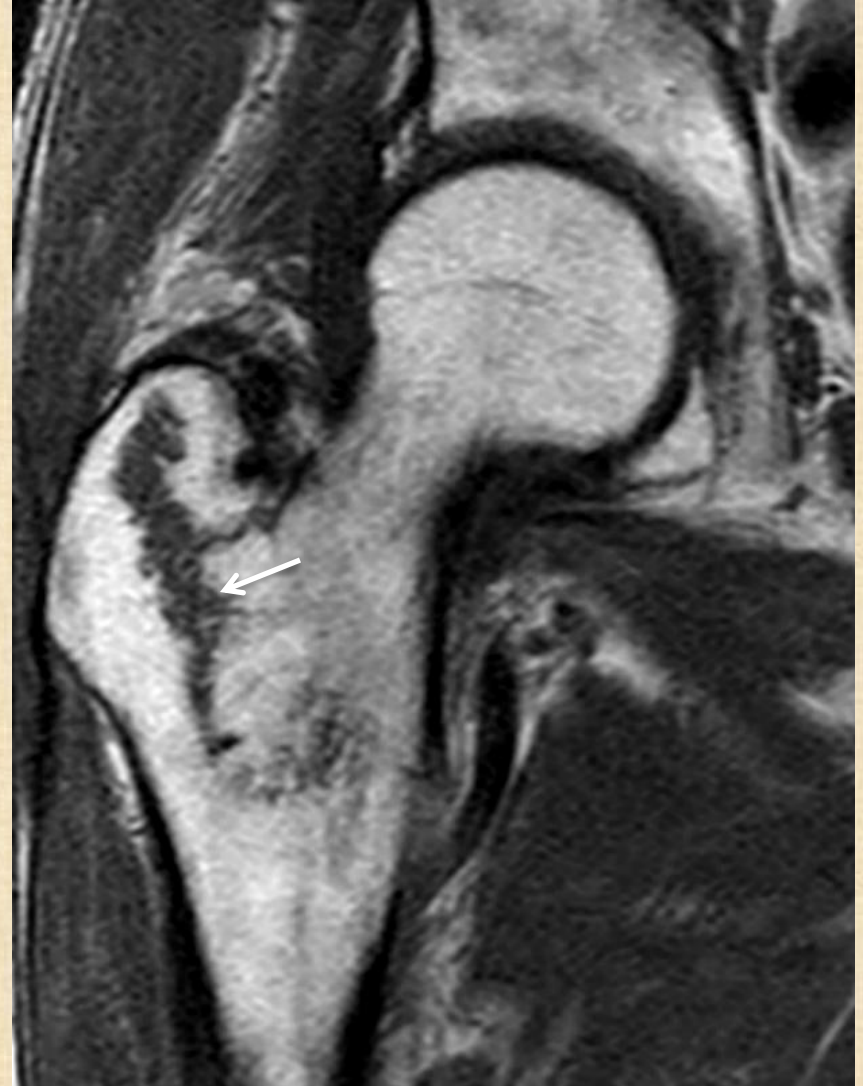
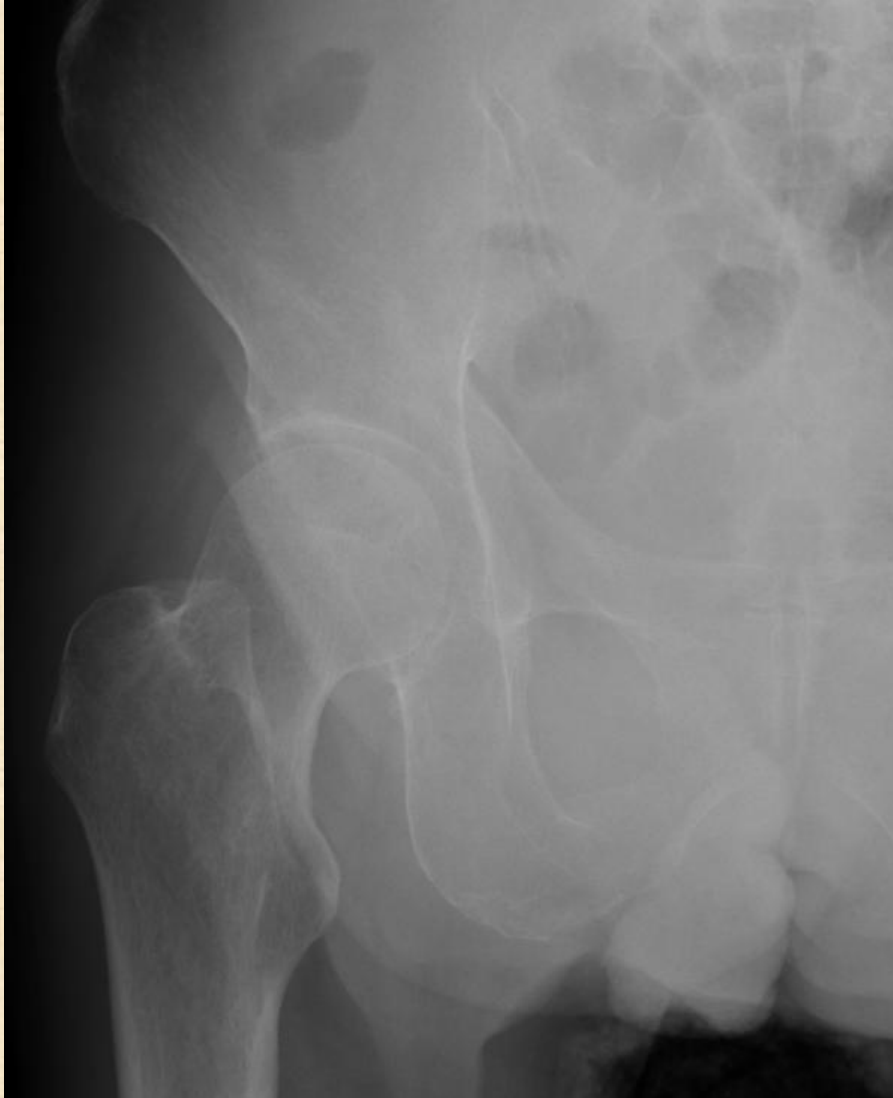
Subcapital to basal

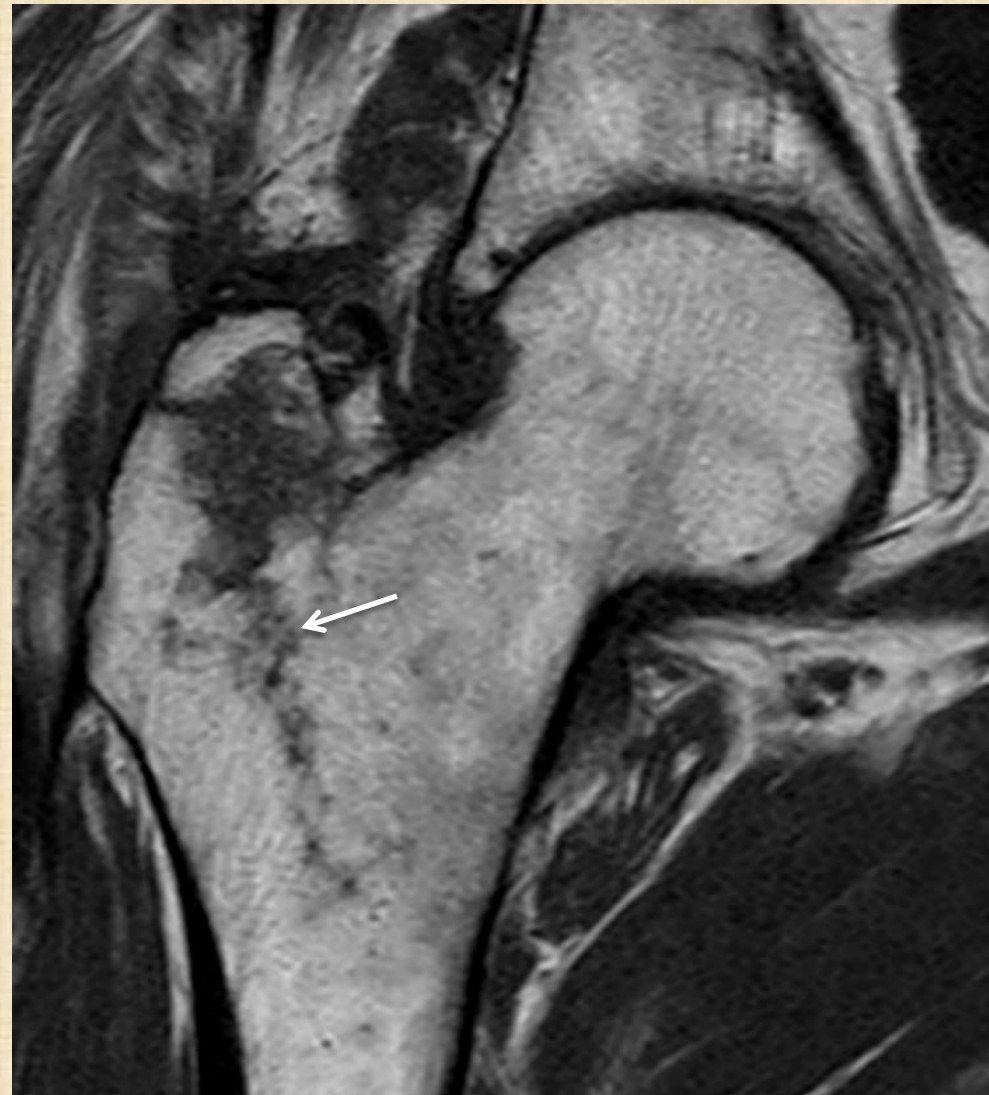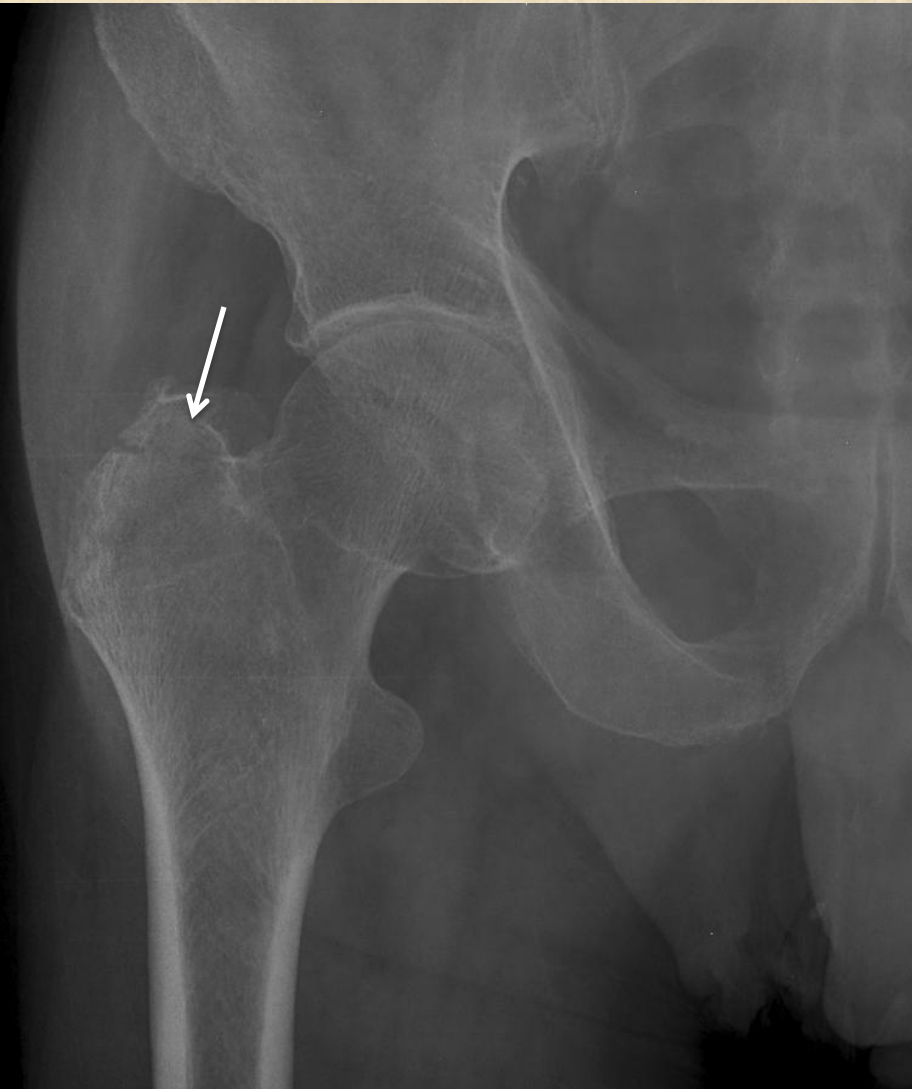
Missed hip fracture



Occult fracture

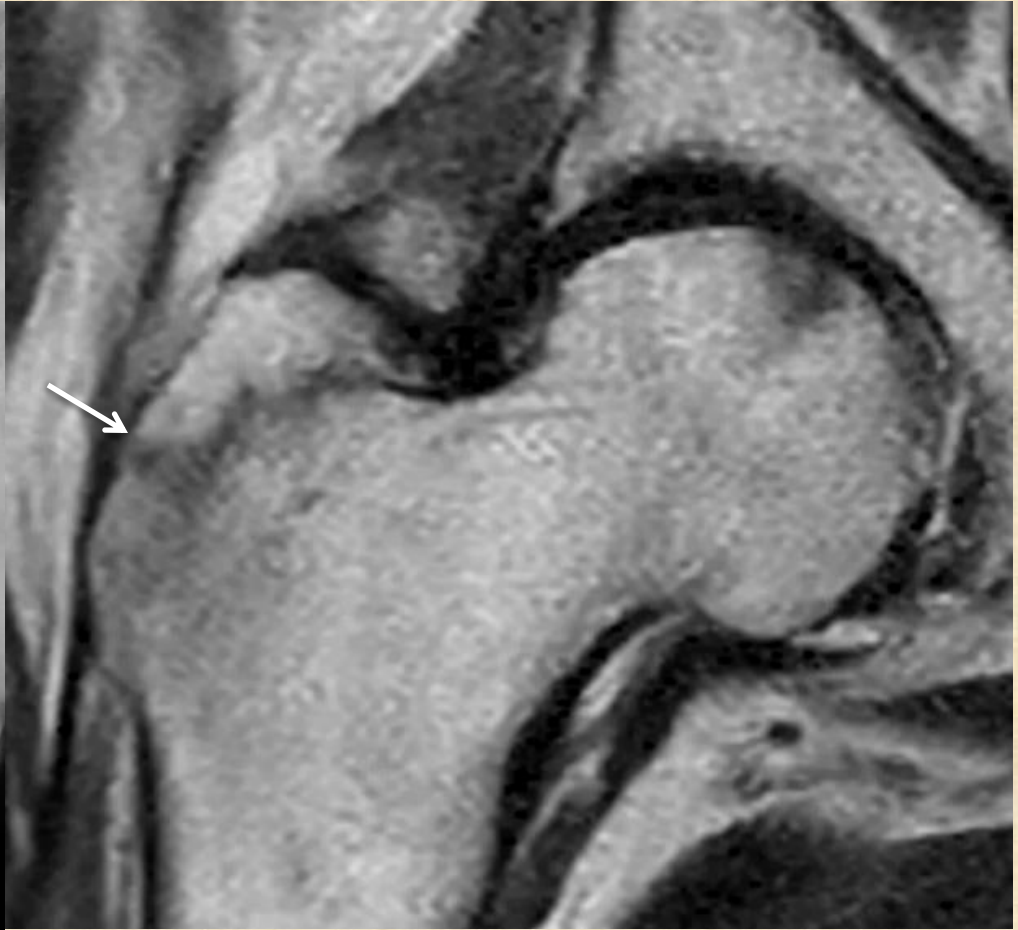
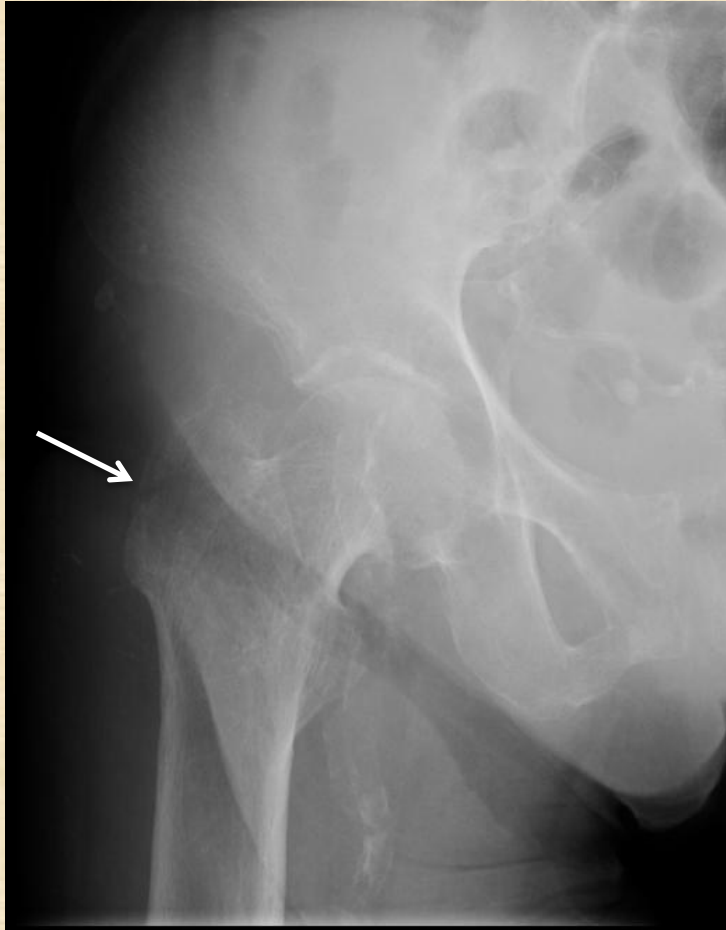

Isolated greater trochanteric fracture ?

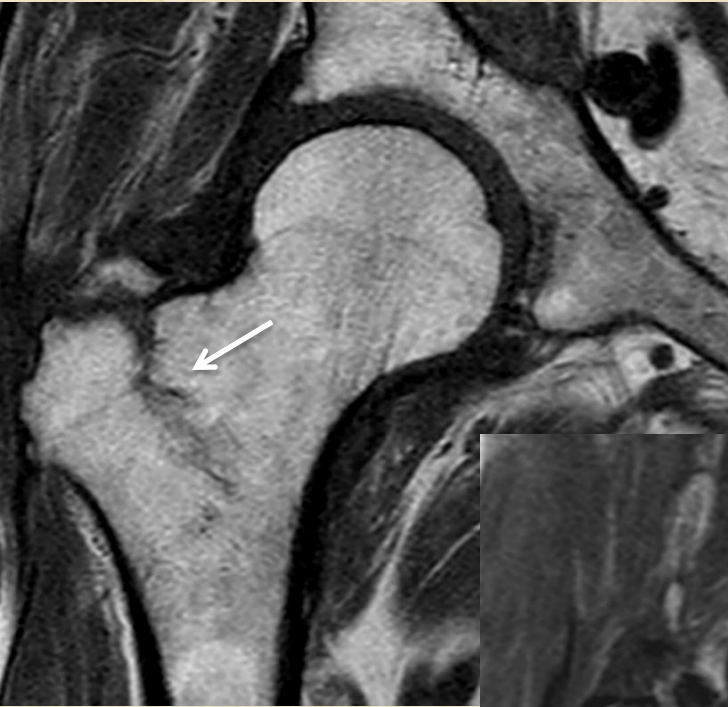

Isolated greater trochanteric fracture

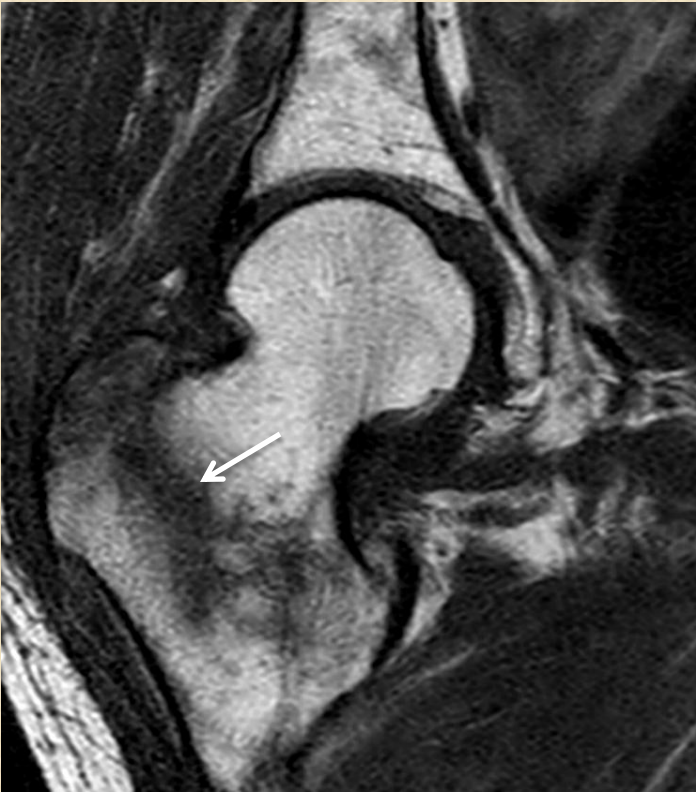- rare



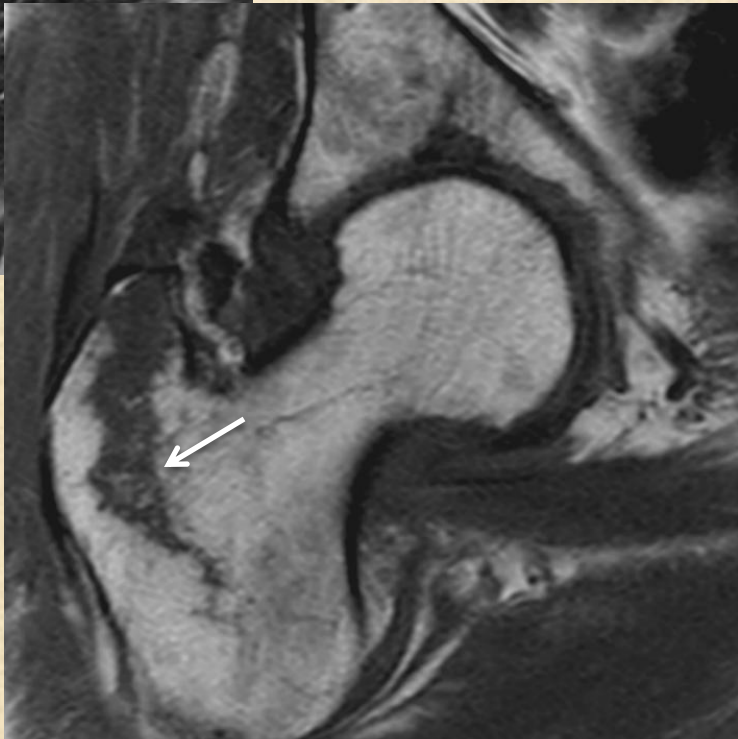
Interochanteric fracture



Partial



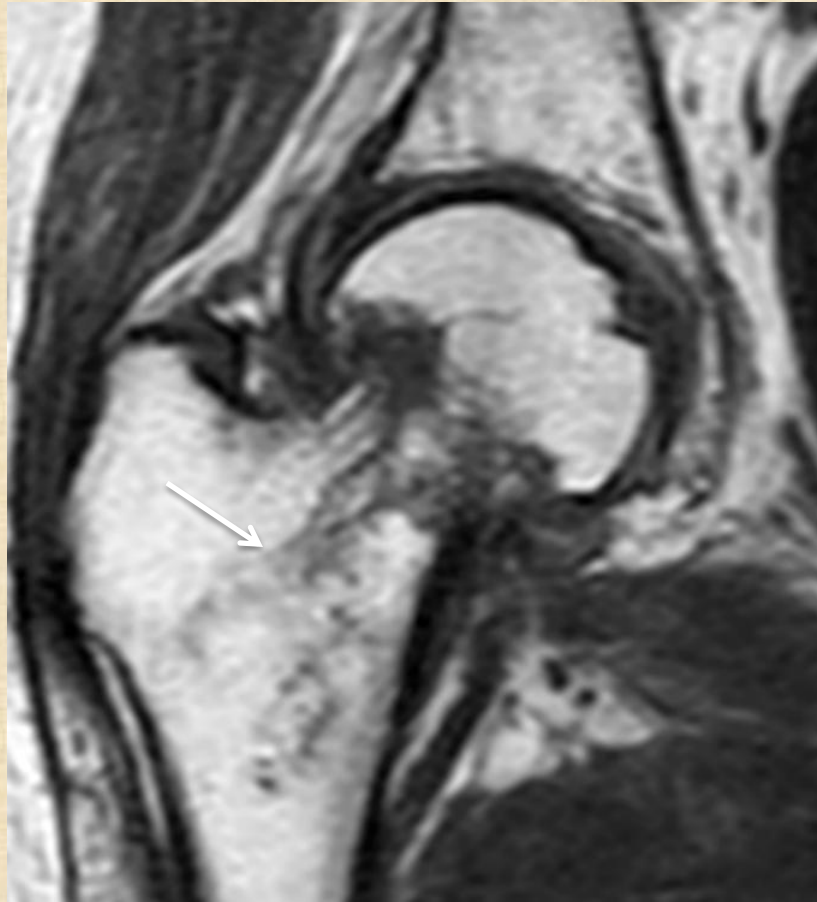
Complete



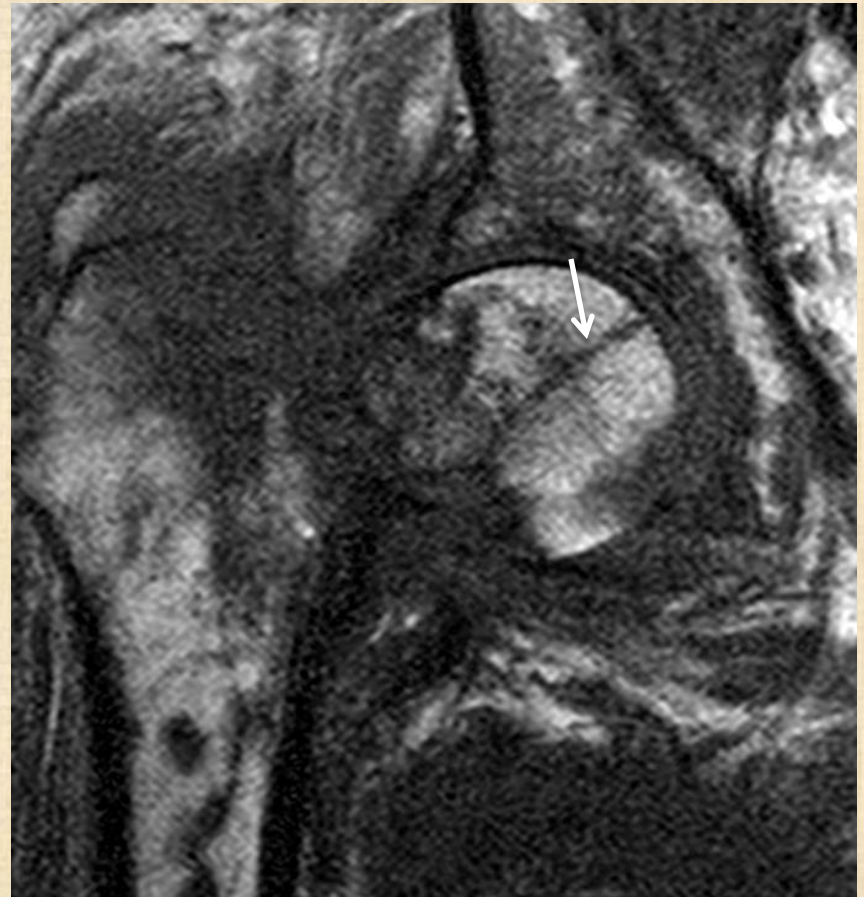Partial

Give percentage !!

Neck with trochanteric and head extension

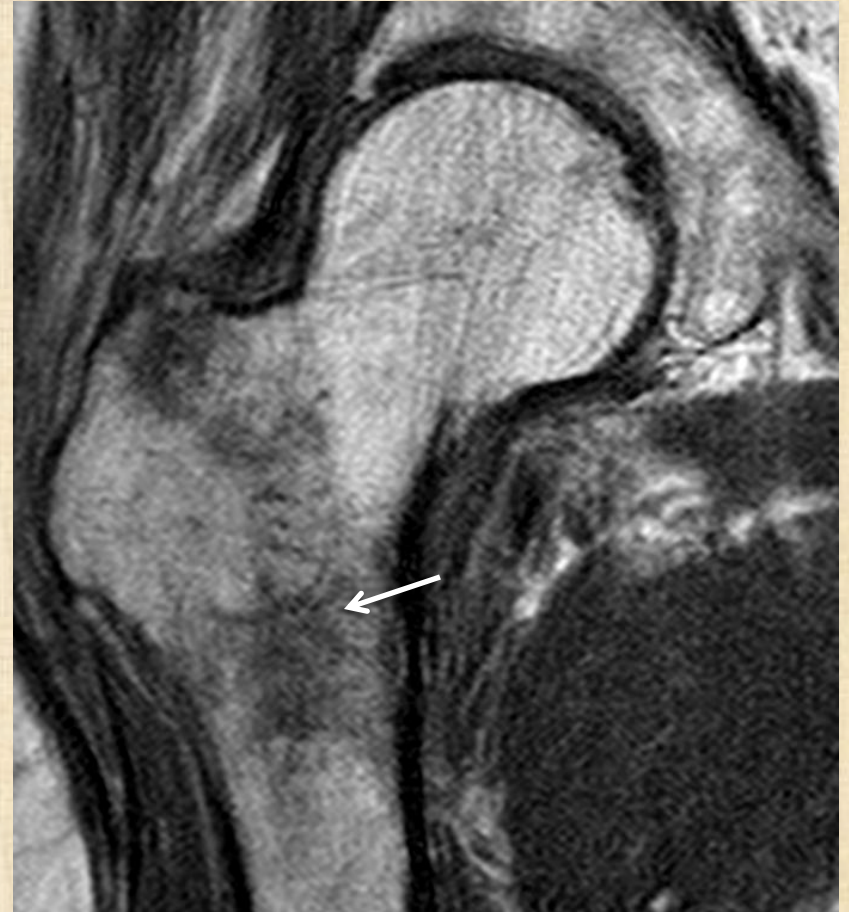
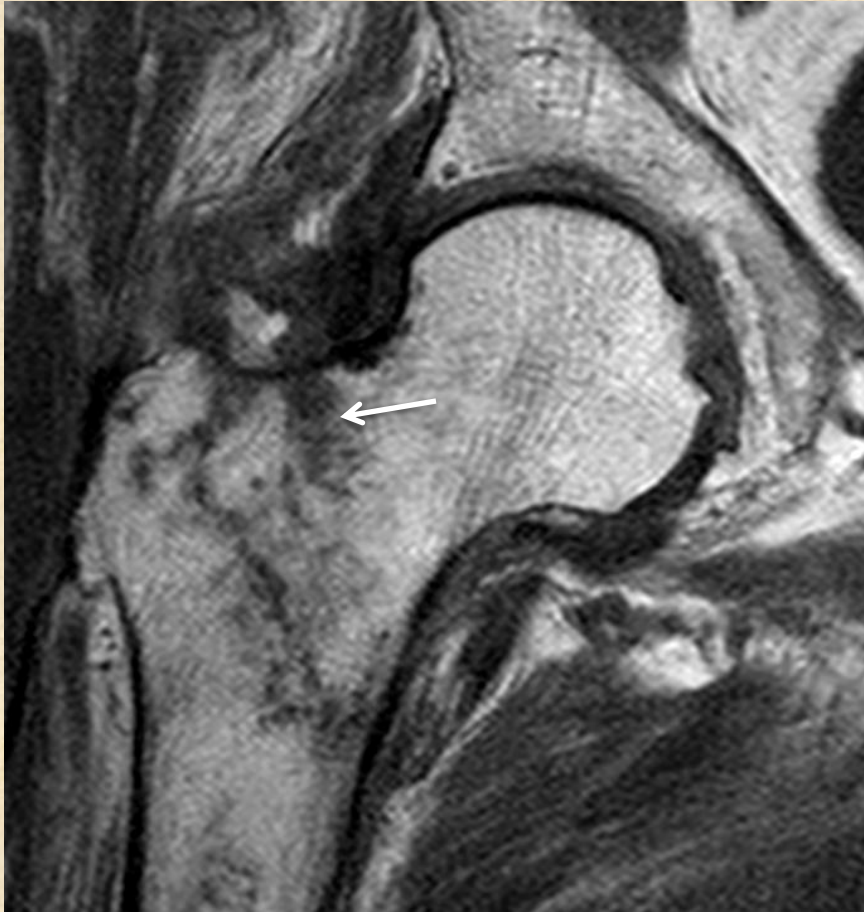
Trochanteric extension



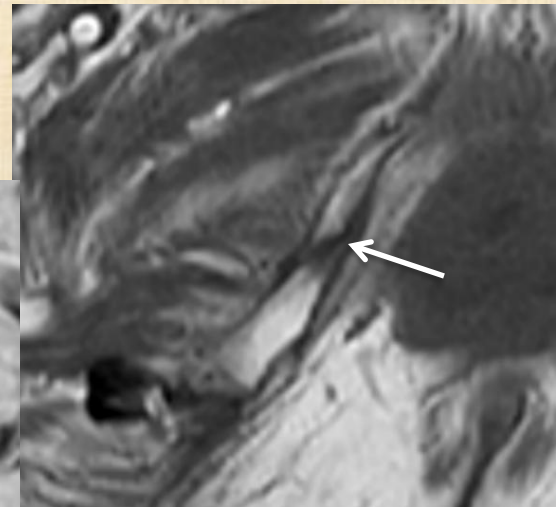
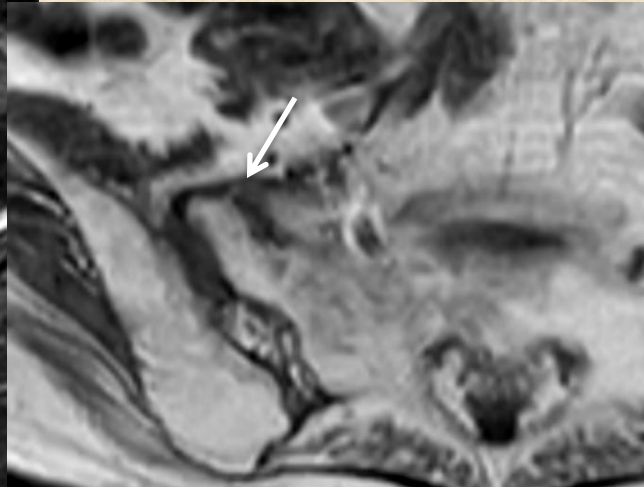
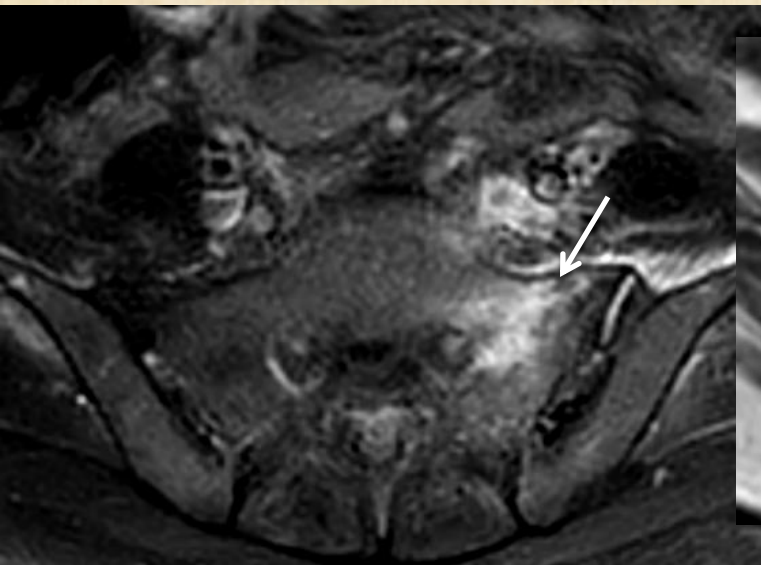
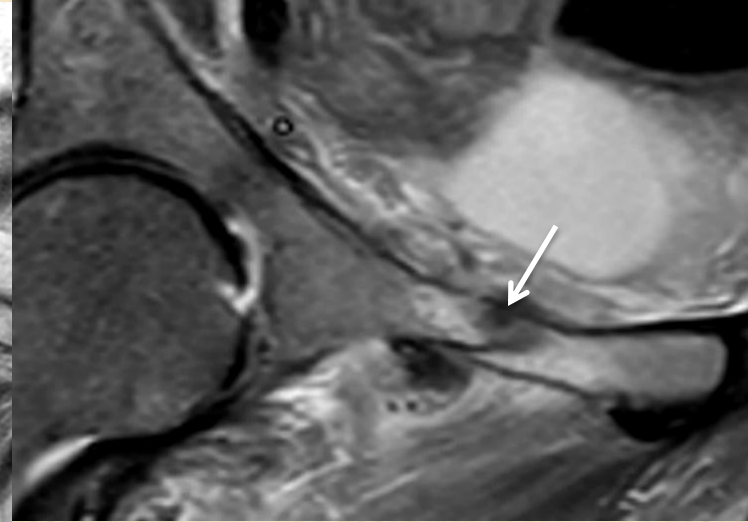
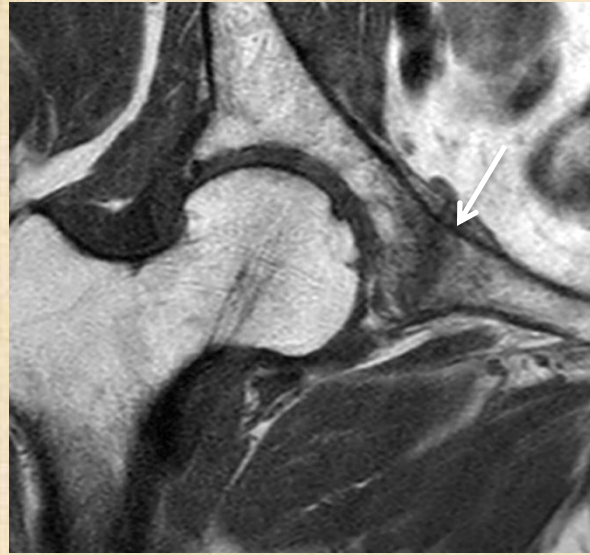Head extension

Intertrochanteric fracture with neck and femoral shaft extension

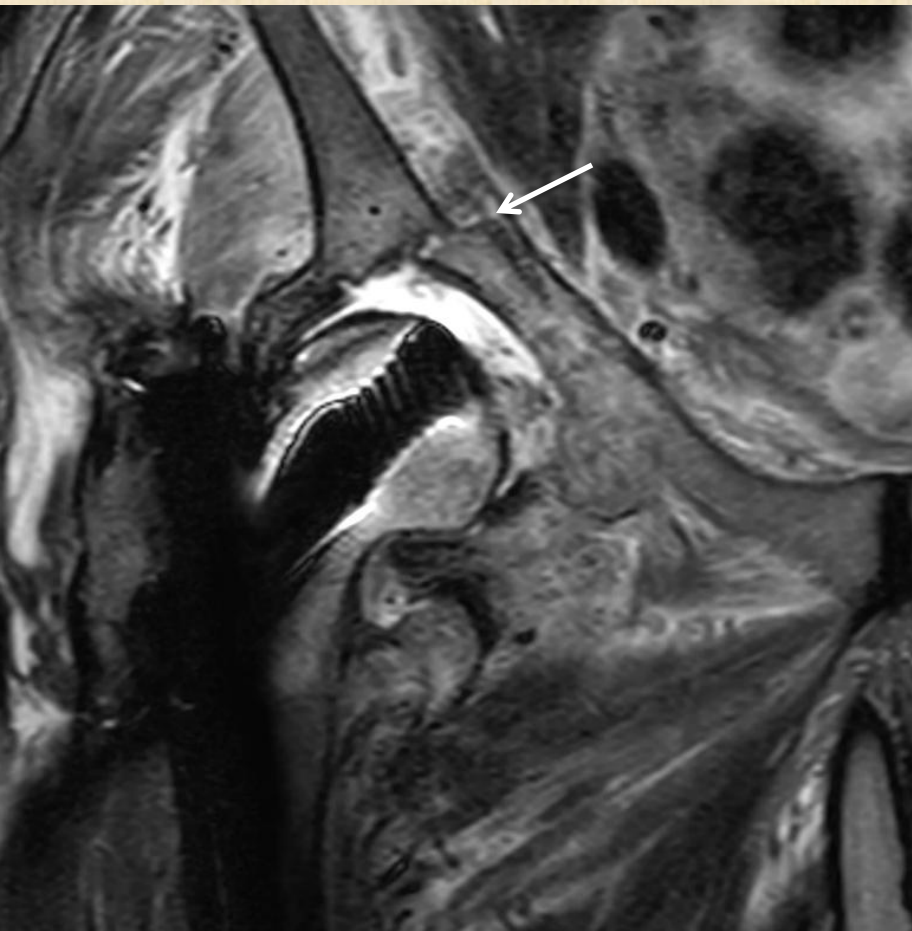


Other fractures

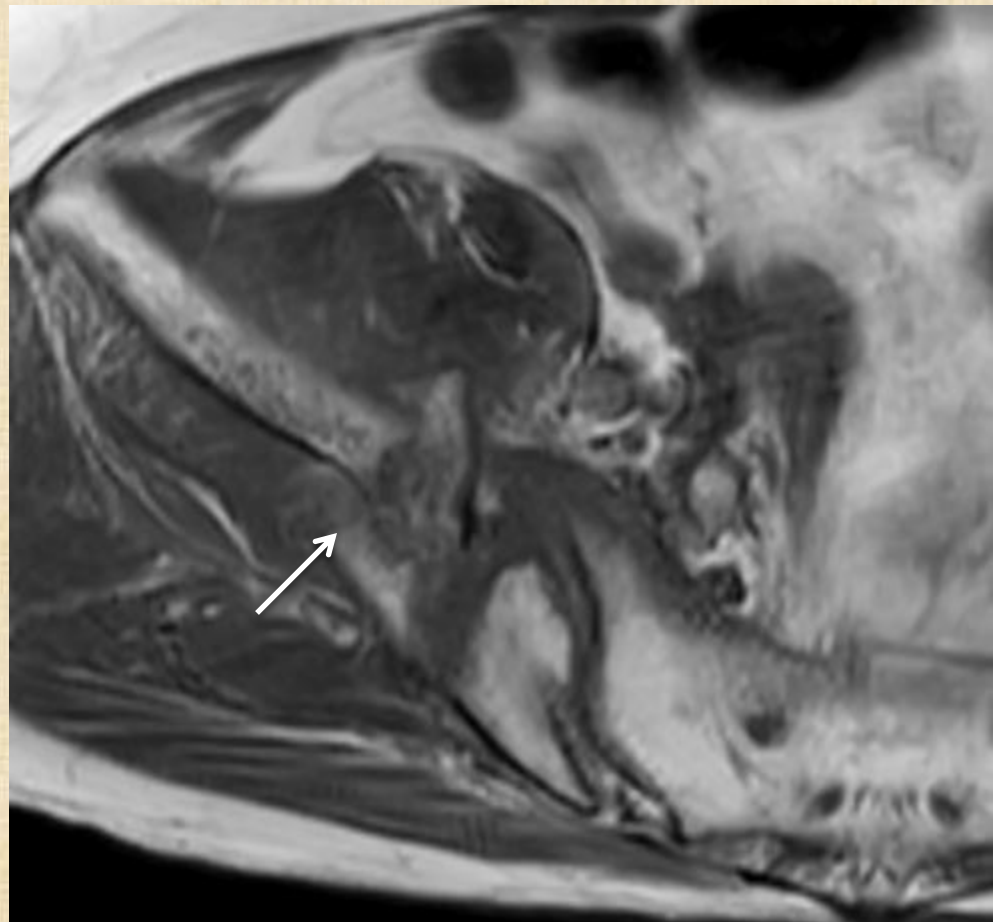
- Pubic rami
- Sacrum
- Ilium
- Acetabulum



Other fractures

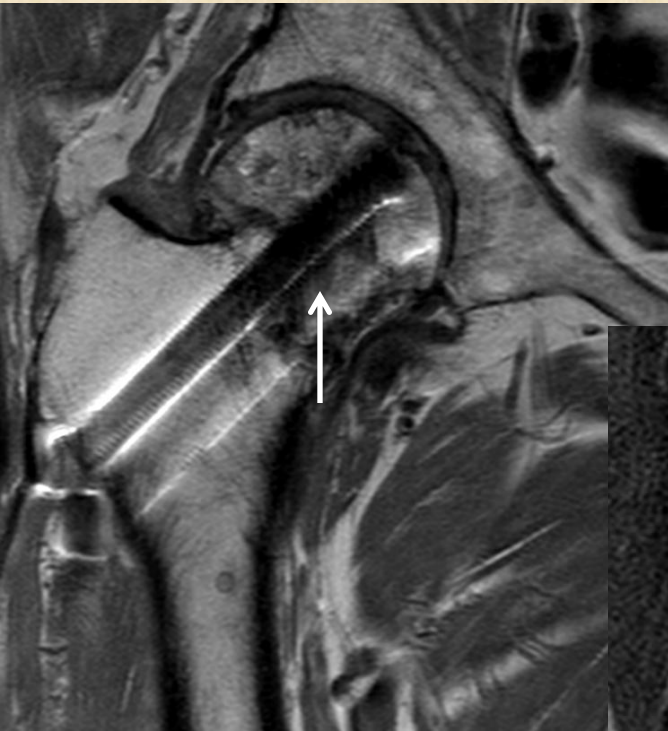

Acetabular fracture

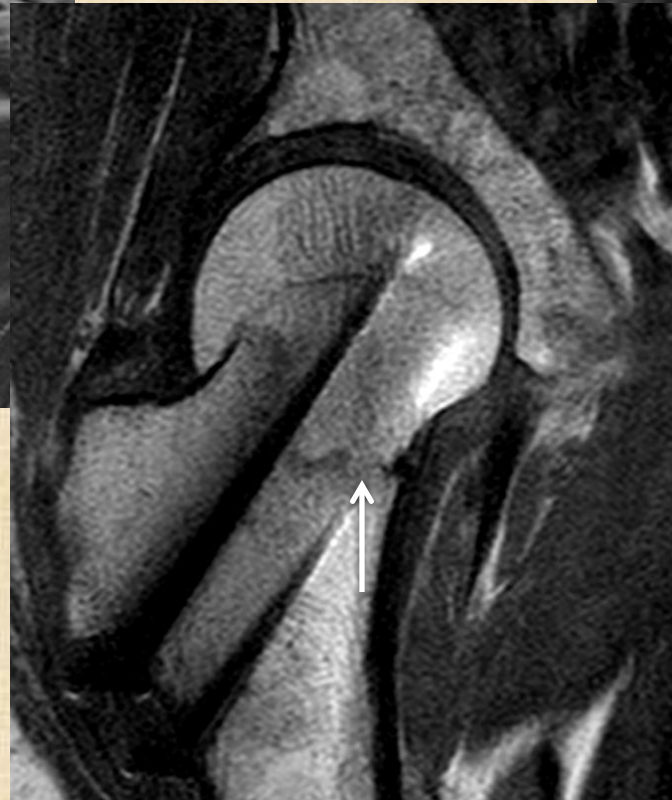

Iliac bone fracture

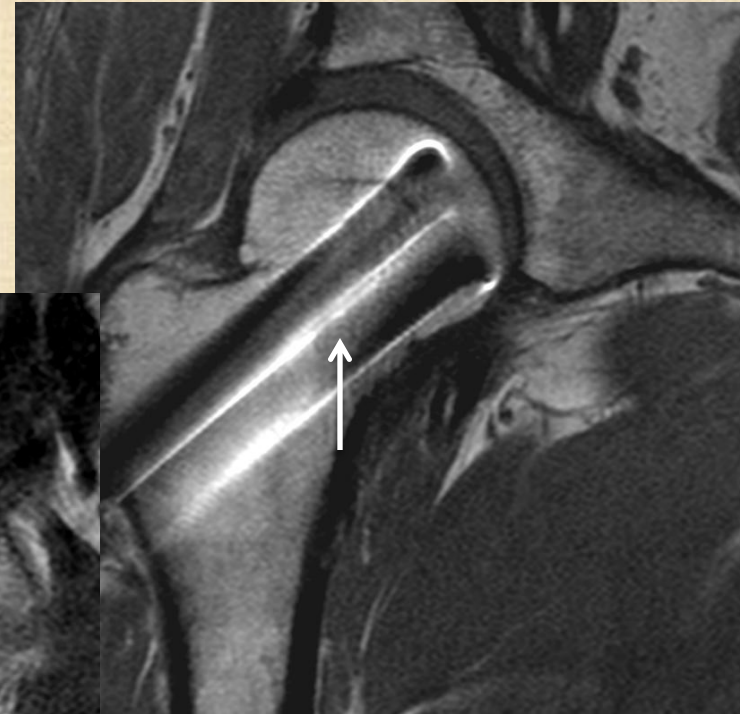Fracture healing



Non-united



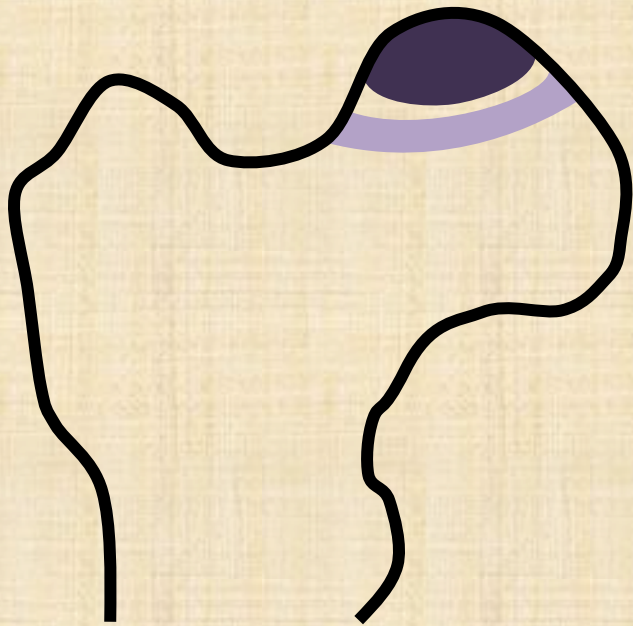Partially united



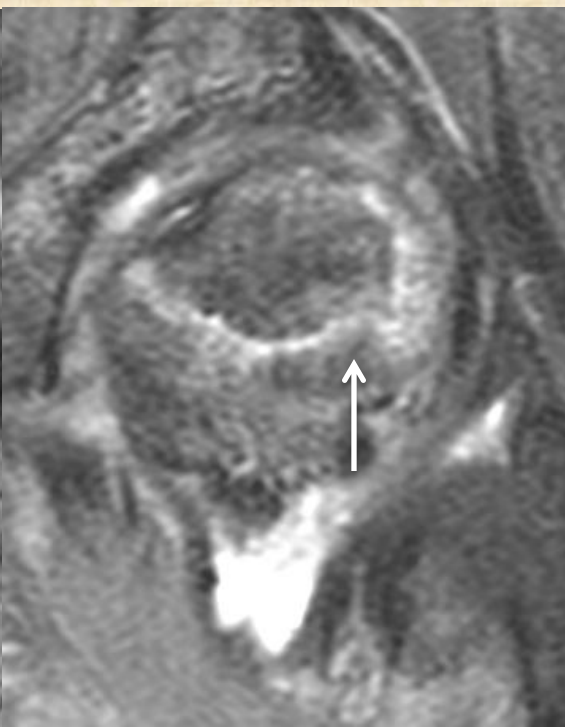
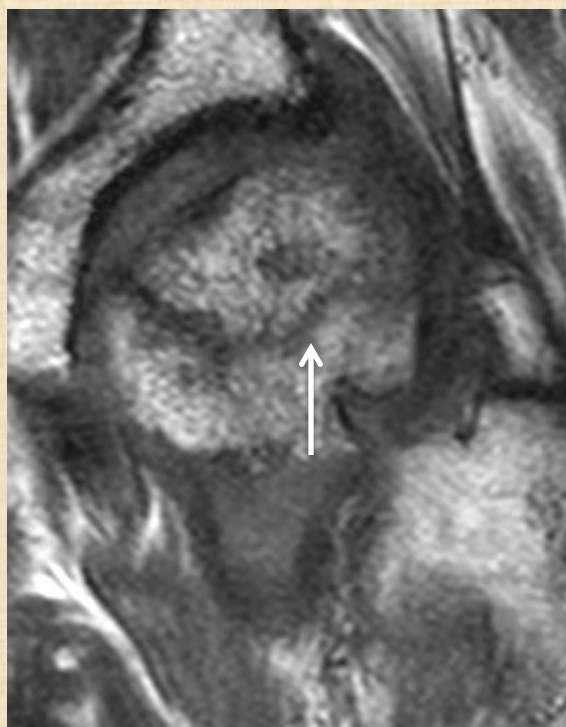
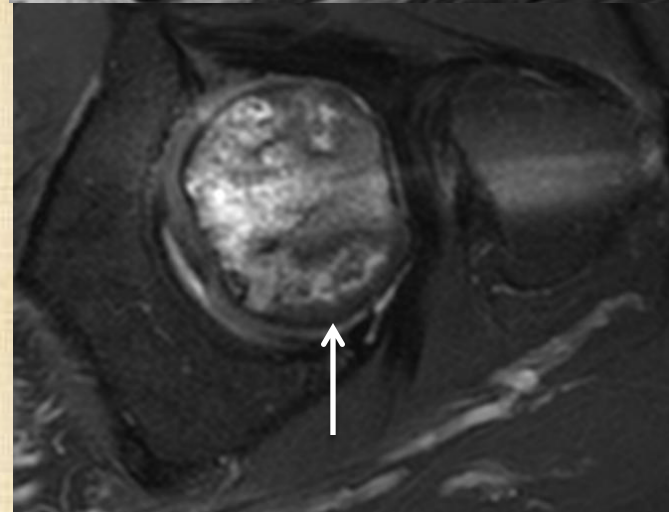
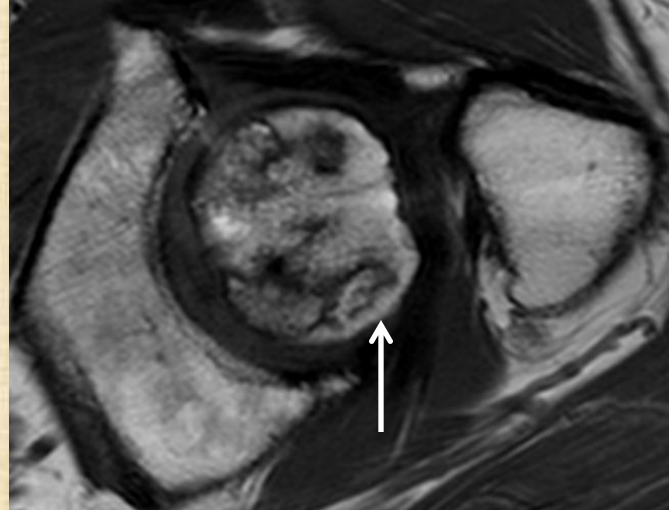
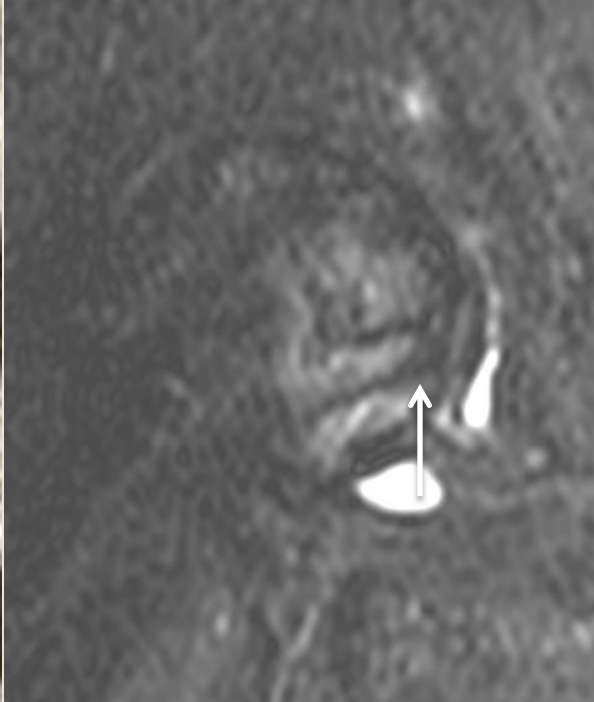
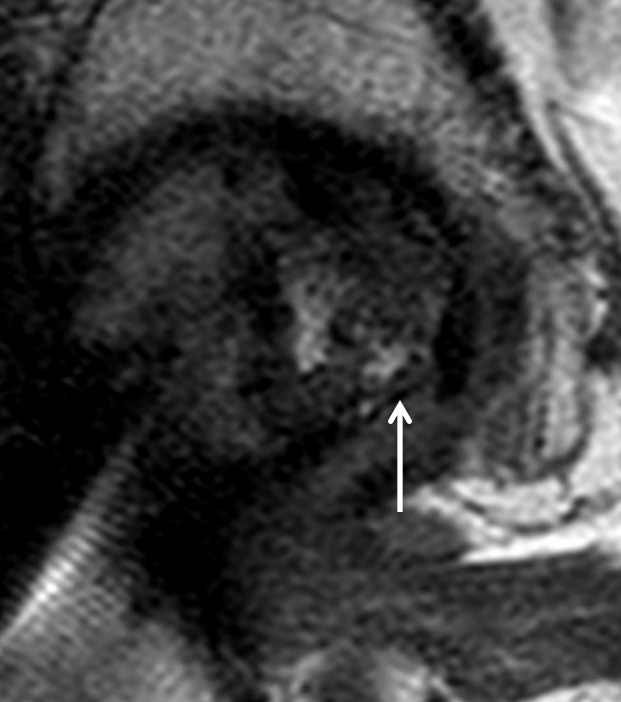
Completely united


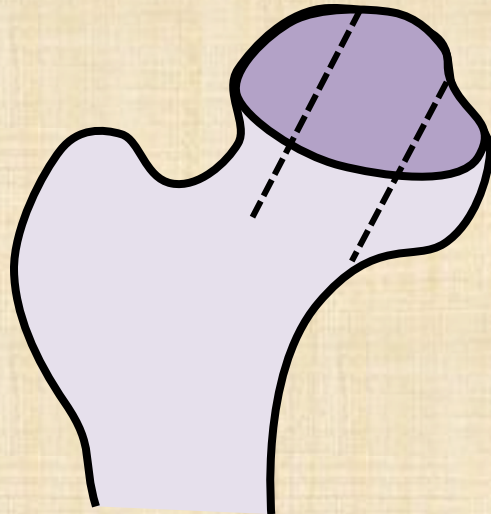
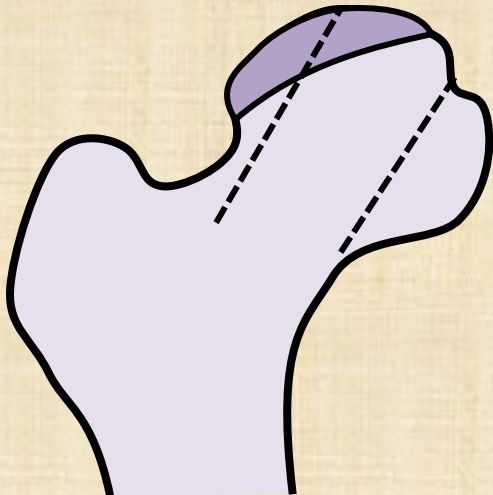

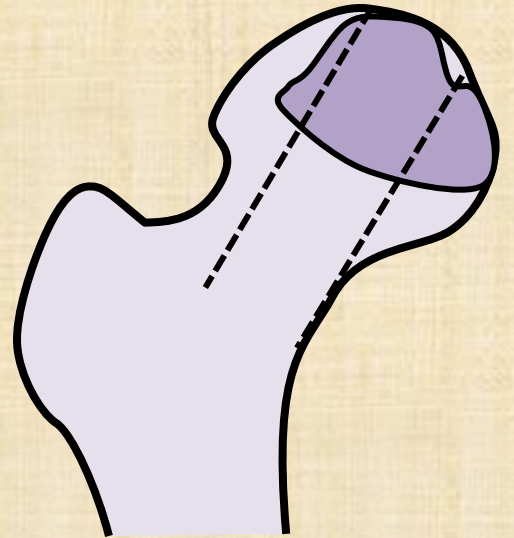
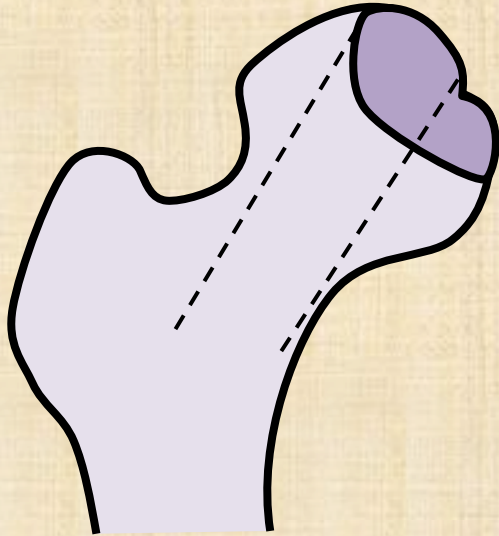
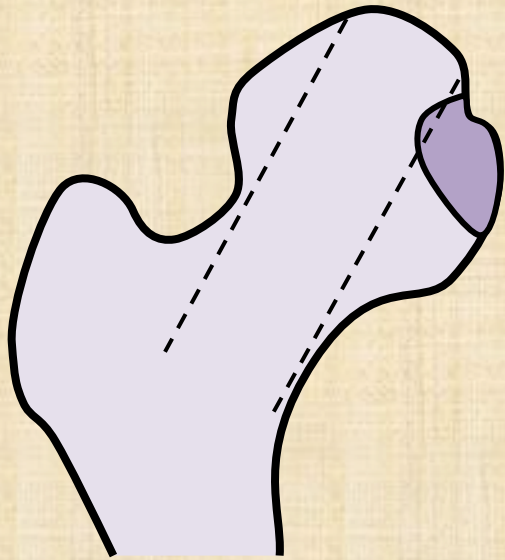
E. Femoral head necrosis

- MRI gold standard
- MRI changes before XR changes
- Typical band like double line sign



OSTEONECROSIS AREA			
STAGE	T1-w	T2-w	TISSUE
A	HIGH	MIDDLE	FAT
B	HIGH	HIGH	BLOOD
C	LOW	HIGH	LIQUID
D	LOW	LOW	FIBROSIS





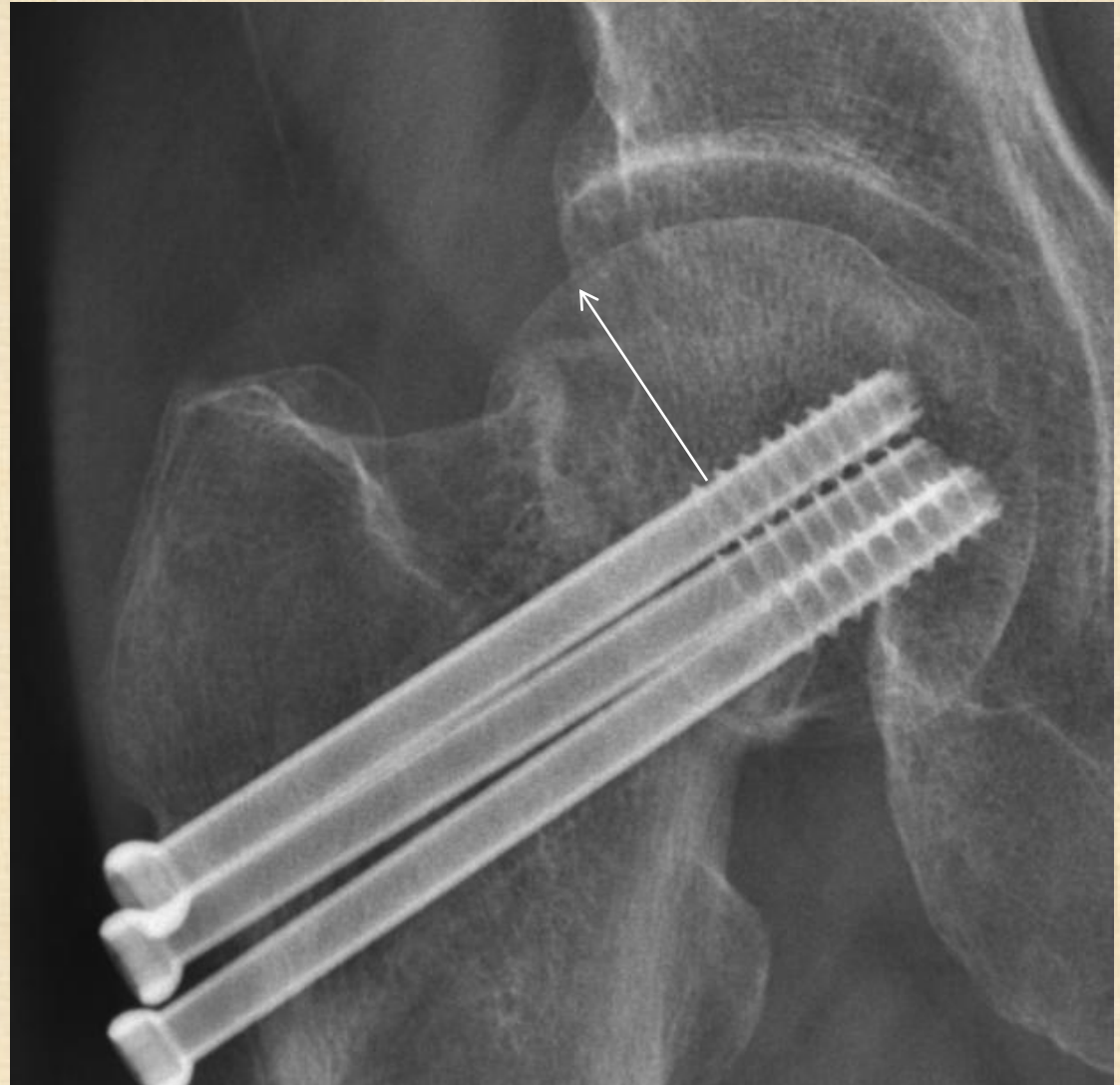STAGE	FICAT-ARLET	STEINBERG/UNIVERSITY OF PENNSYLVANIA	ARCO			
0	<ul style="list-style-type: none"> •Hip Pain - •Plan X-Ray - •CT - •RM - •Bone scan - 	<ul style="list-style-type: none"> •Hip Pain - •Plan X-Ray - •CT - •RM - •Bone scan - 	<ul style="list-style-type: none"> •Hip Pain - •Plan X-Ray - •CT - •RM - •Bone scan - 			
1	<ul style="list-style-type: none"> •Hip Pain + •Plan X-Ray - •CT - •RM + •Bone scan + 	<ul style="list-style-type: none"> •Hip Pain + •Plan X-Ray - •CT - •RM + •Bone scan + 	Head affected •A: <15% •B: 15%-30% •C: >30%	<ul style="list-style-type: none"> •Hip Pain + •Plan X-Ray - •CT - •RM + •Bone scan + 	Location Quantitation	Area •A: <15% •B: 15%-30% •C: >30%
2	Sclerosis & porosity &/ or cystic	Femoral head lucency/sclerosis	Head affected •A: <15% •B: 15%-30% •C: >30%	Sclerosis in femoral head, no collapse	medical central lateral	Length of crescent •A: <15% •B: 15%-30% •C: >30%
3	Femoral head flattening, subchondral collapse, "crescent sign"	Subchondral collapse without femoral head flattening, "crescent sign"	Involvement of the articular surface •A: <15% •B: 15%-30% •C: >30%	Femoral head collapse, "crescent sign", no joint space narrowing		Surface collapse Dome depression •A: <15% •B: 15%-30% •C: >30%
4	Osteoarthritic joint space narrowing, degenerative changes	Subchondral collapse femoral head flattening, Normal joint space	•A:<15% & <2mm depression •B: 15%-30% or 2-4mm depression •C: >30% or >4mm depression	Osteoarthritic degenerative changes		
5		Flattening with joint space narrowing, acetabular changes, or both	Average of femoral head involvement & estimated acetabular involvement			
6		Osteoarthritic degenerative changes				

Surgical decision

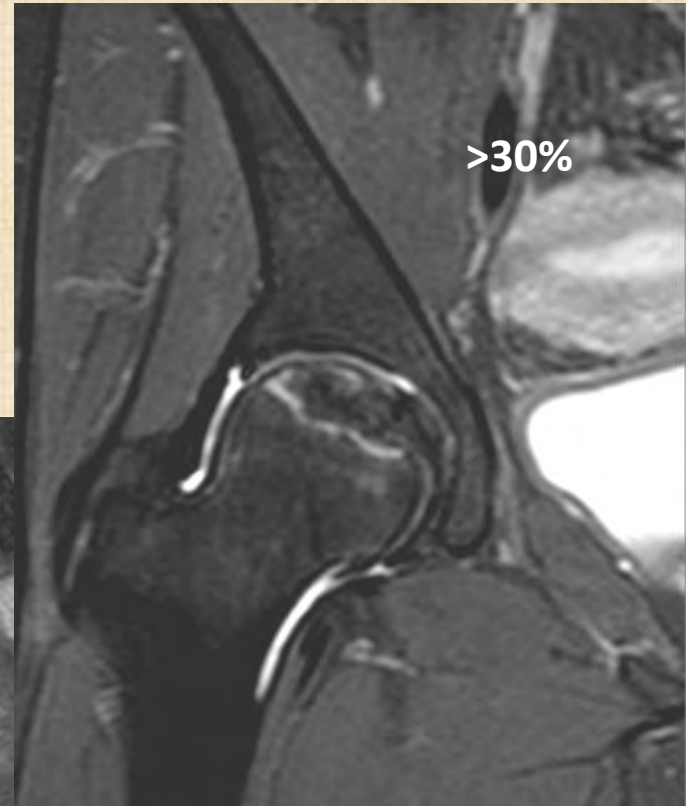
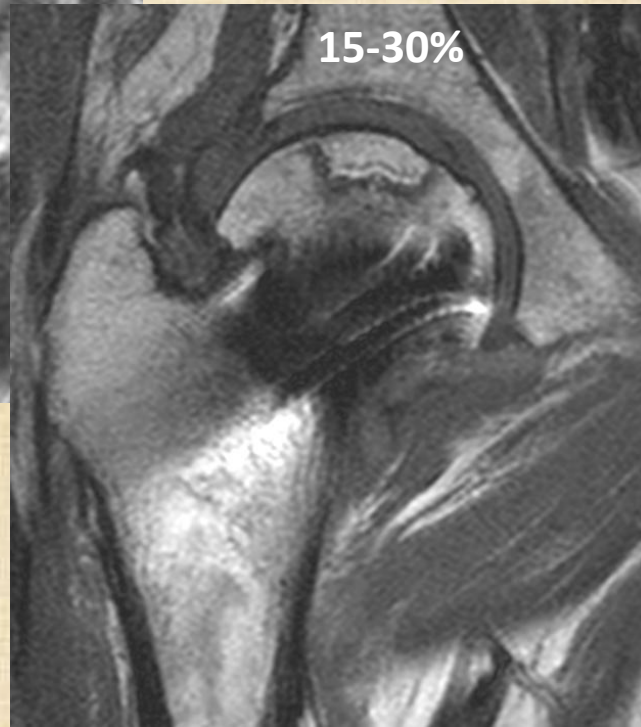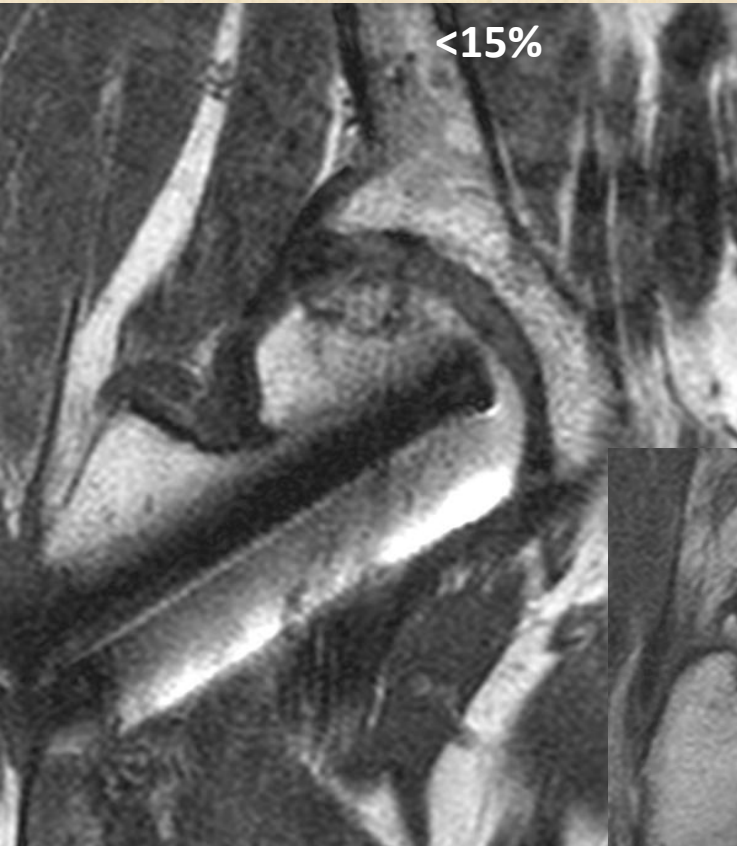
- No collapse : % femoral head involvement
- Collapse : % femoral head articular surface involvement
- Pillar involvement (medial/central/**lateral**)
- Osteoarthritis

Subchondral collapse

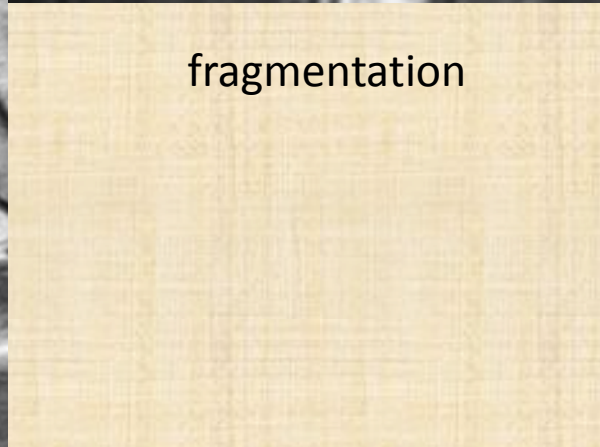
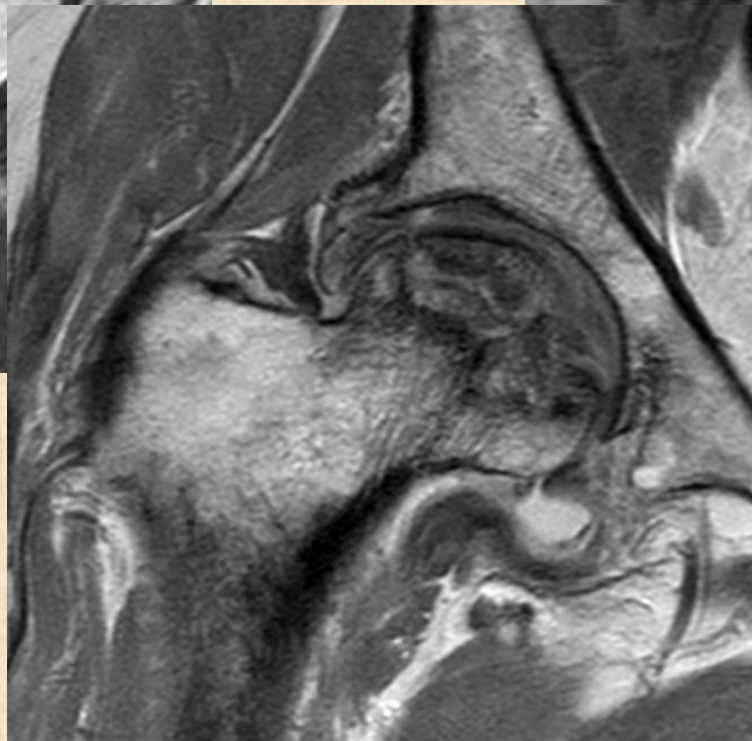
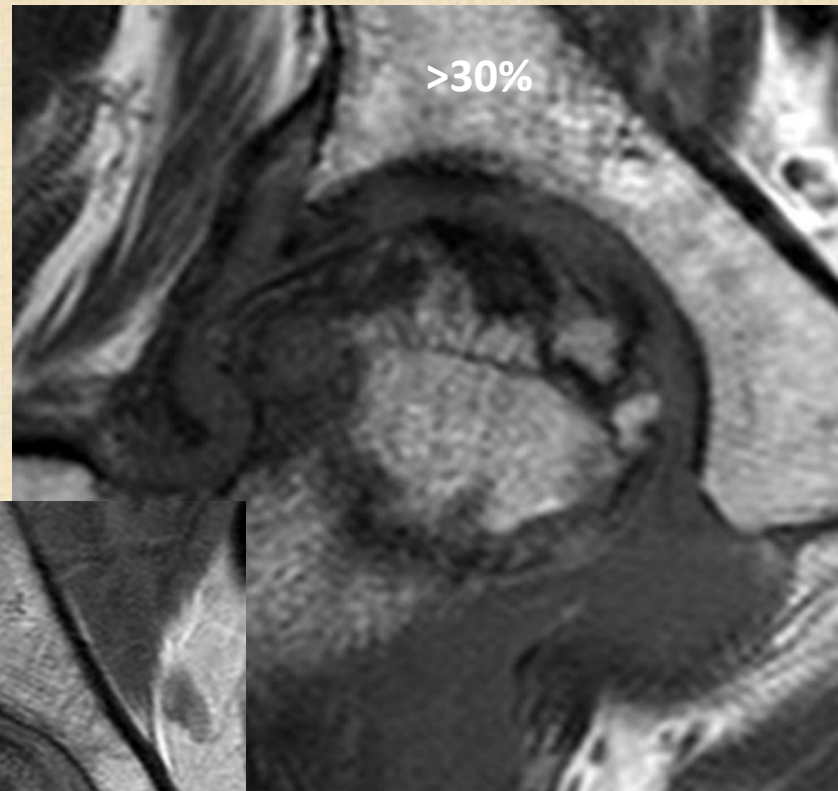
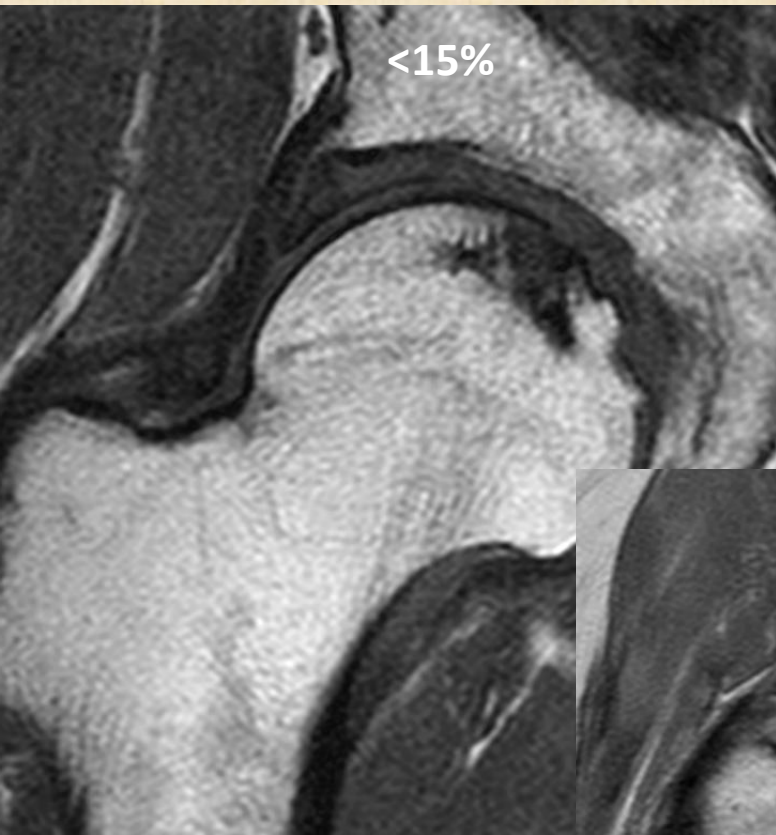
- Crescent sign



No collapse

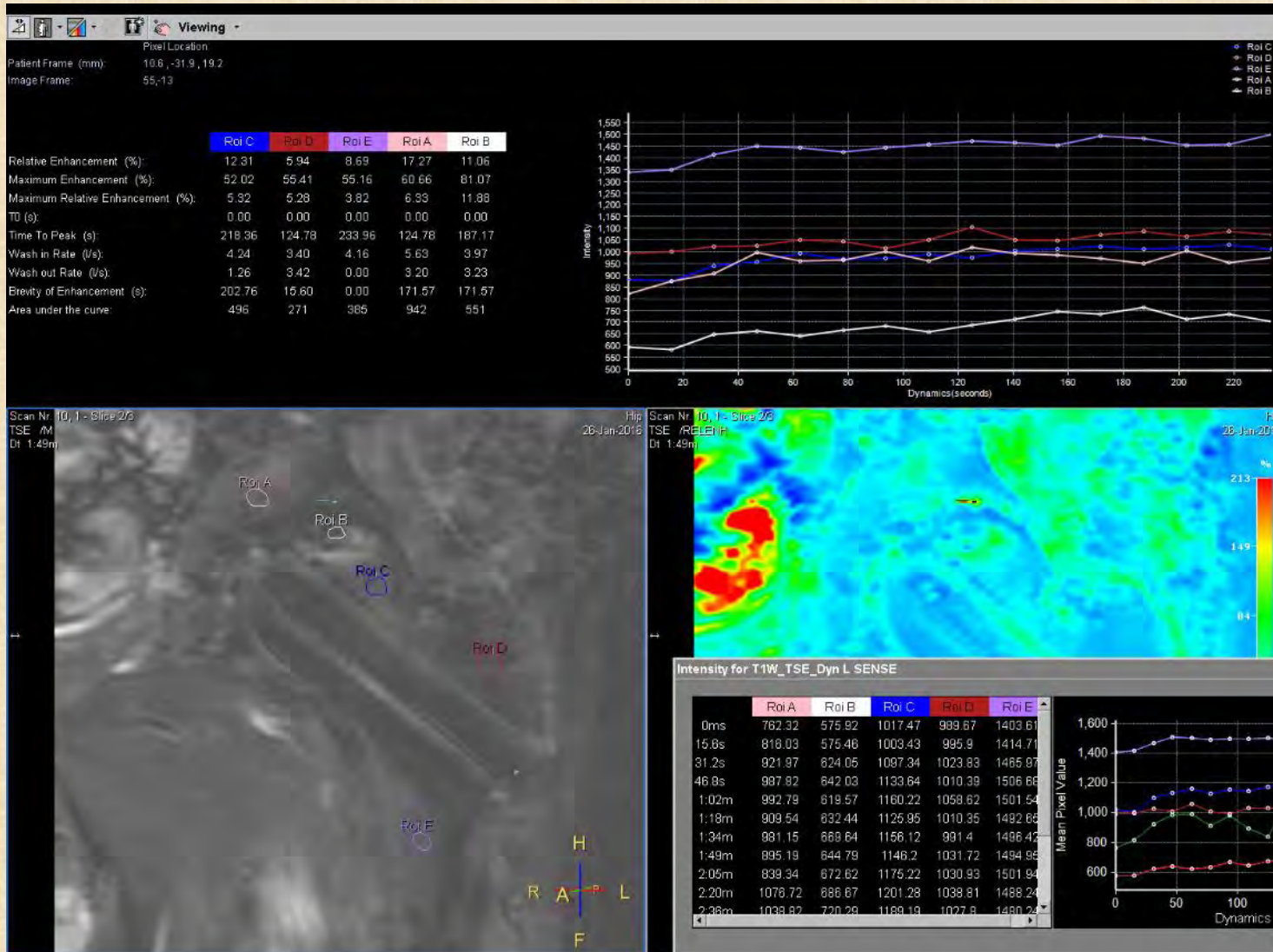


Flattening of femoral head



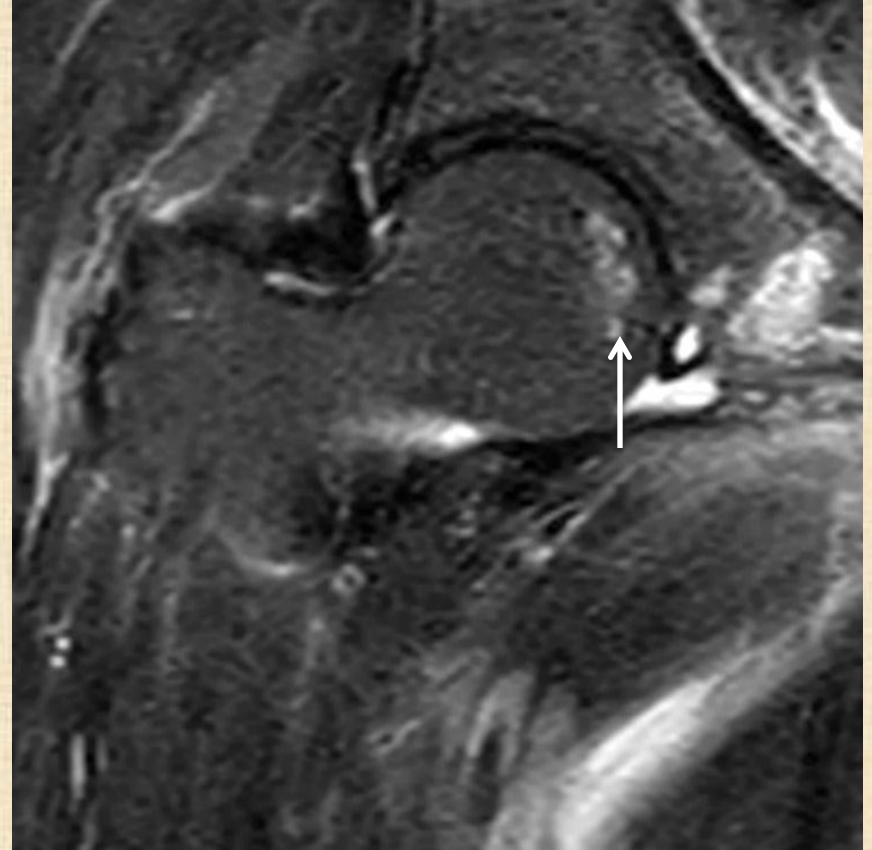
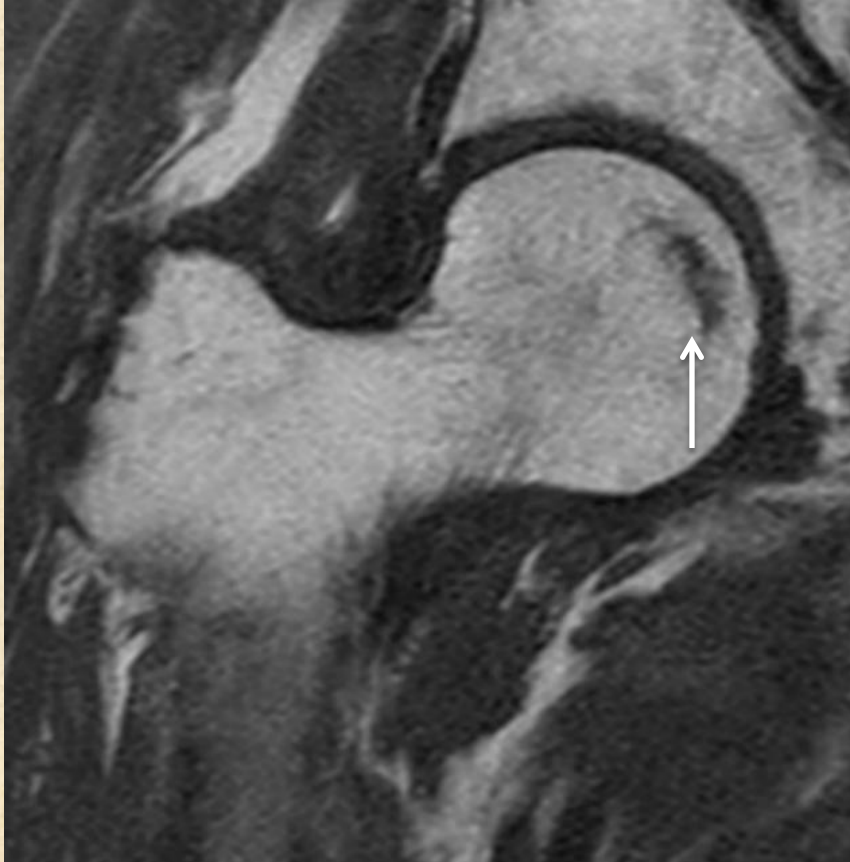
fragmentation

Dynamic MRI

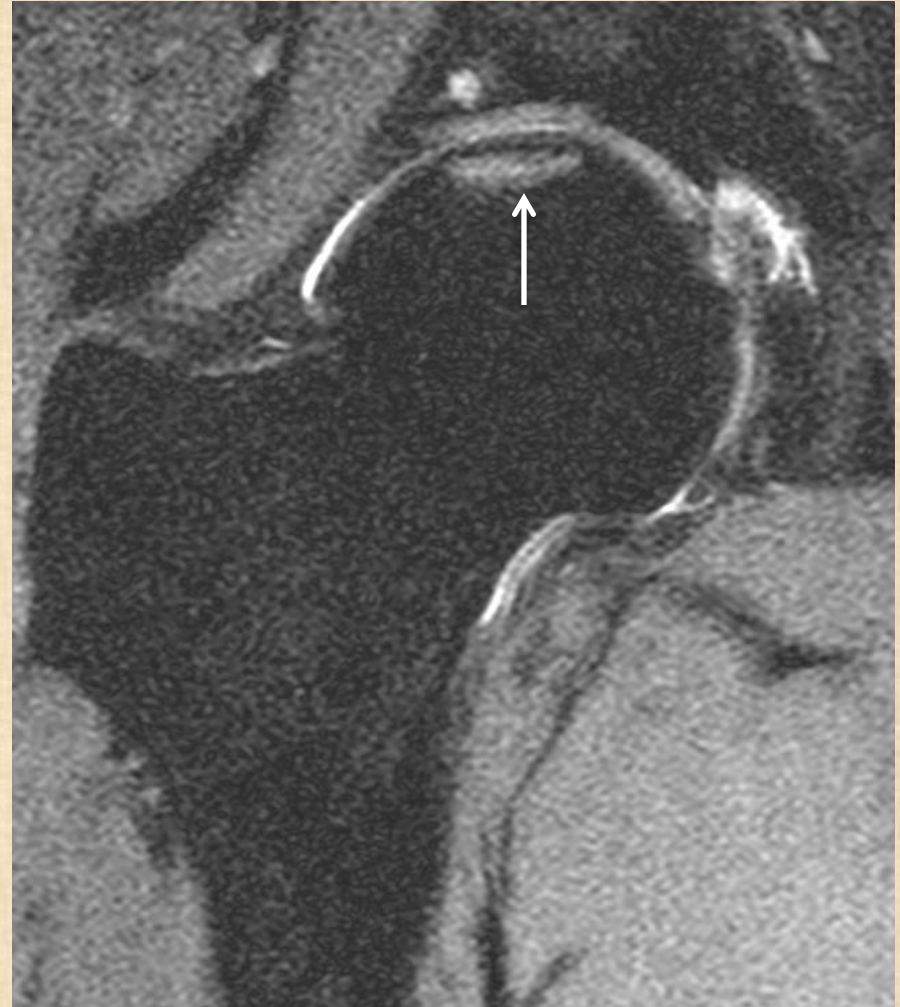
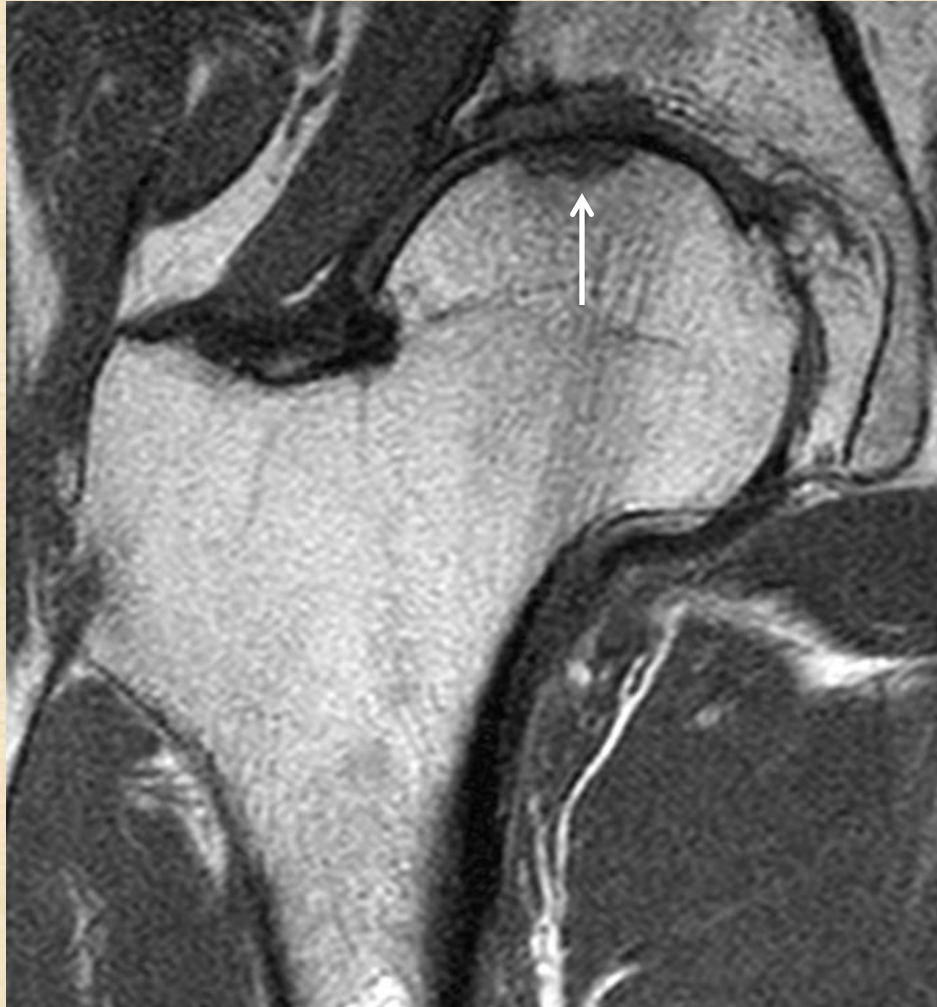
	Subchondral insufficient fracture	Osteonecrosis
Age/sex	Elderly/female	30s to 40s
Etiology	Osteoporosis/obese	Steroid / alcohol
Bilateral	Rare	50%-70%
Shape of the band	Irregular, disconnected Convex	Smooth Concave
High signal of the proximal		
Segment on gadolinium MRI	Yes	No

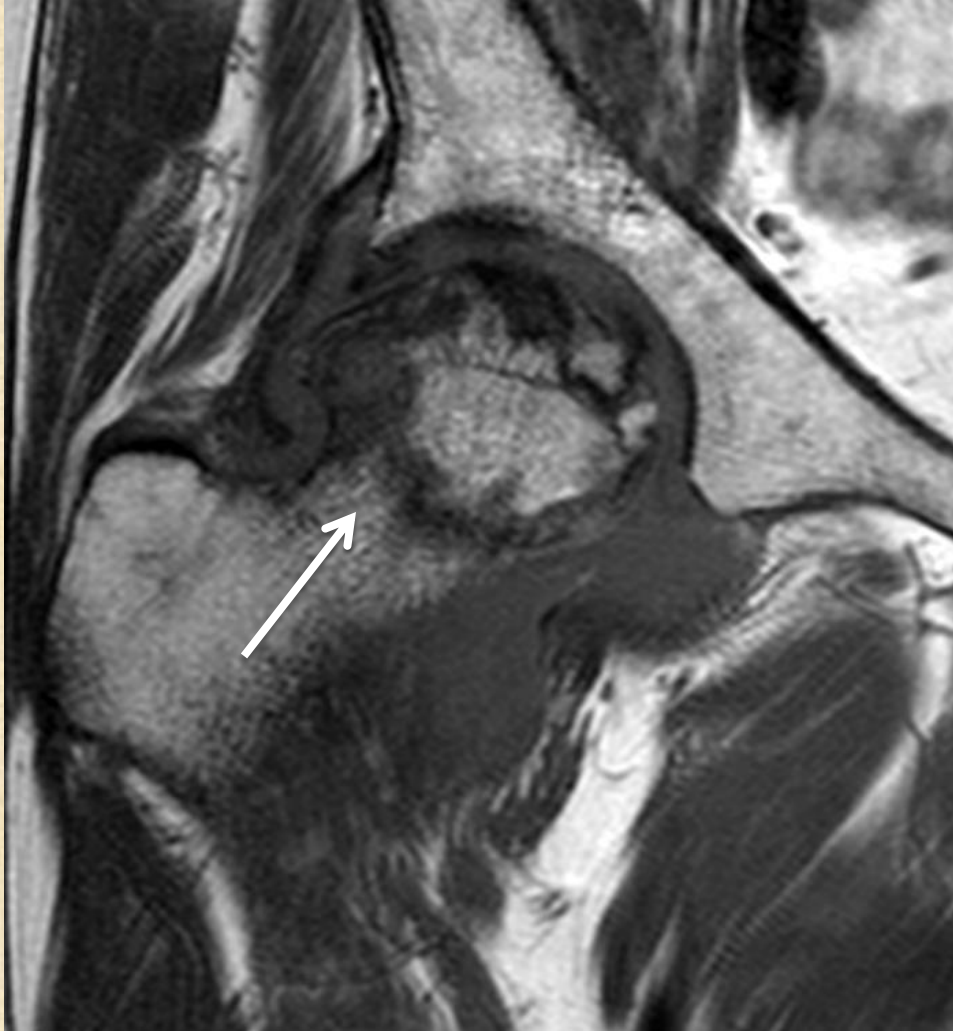Subchondral insufficiency fracture



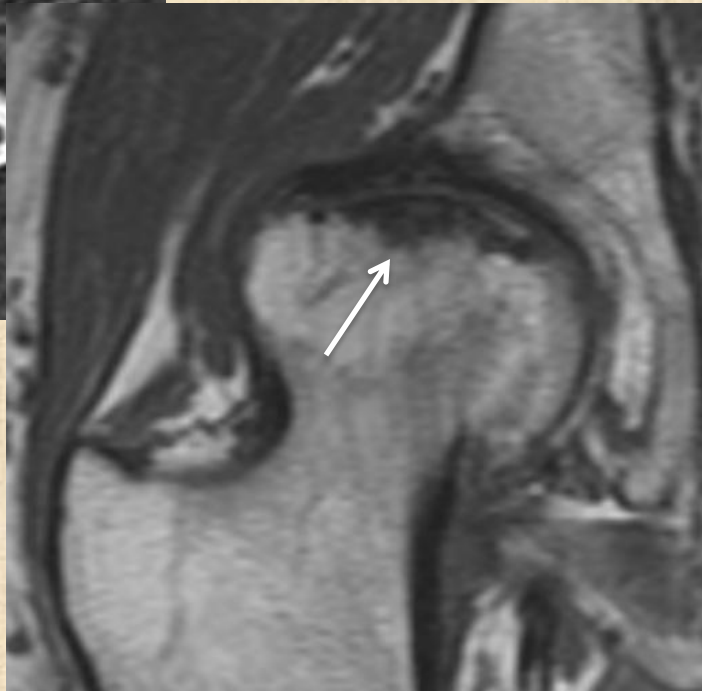
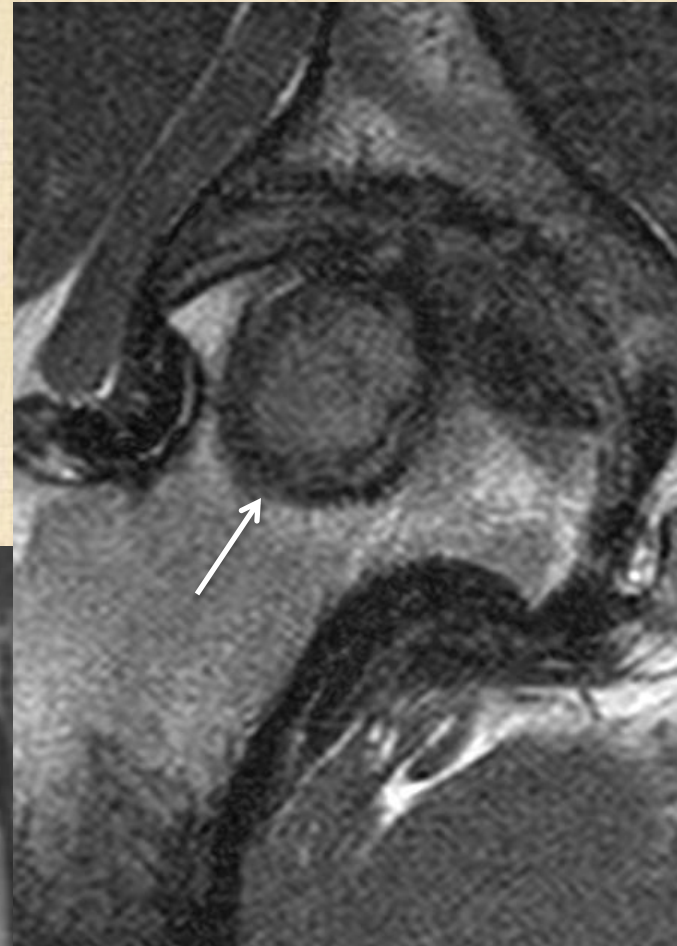
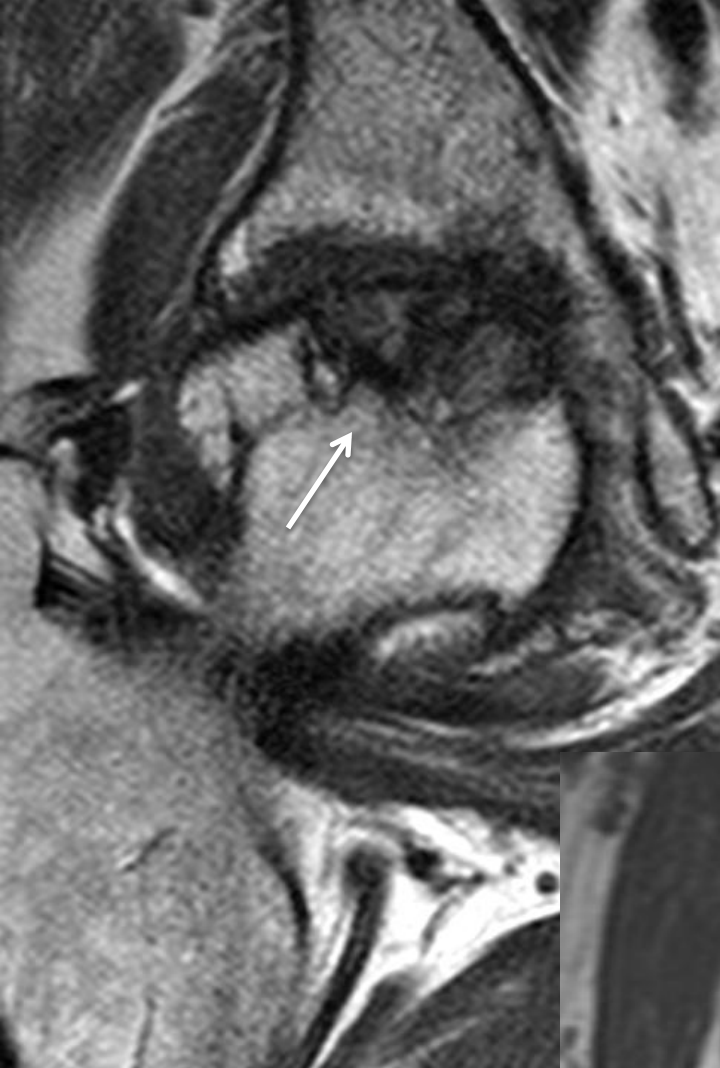
Subchondral insufficiency fracture ?




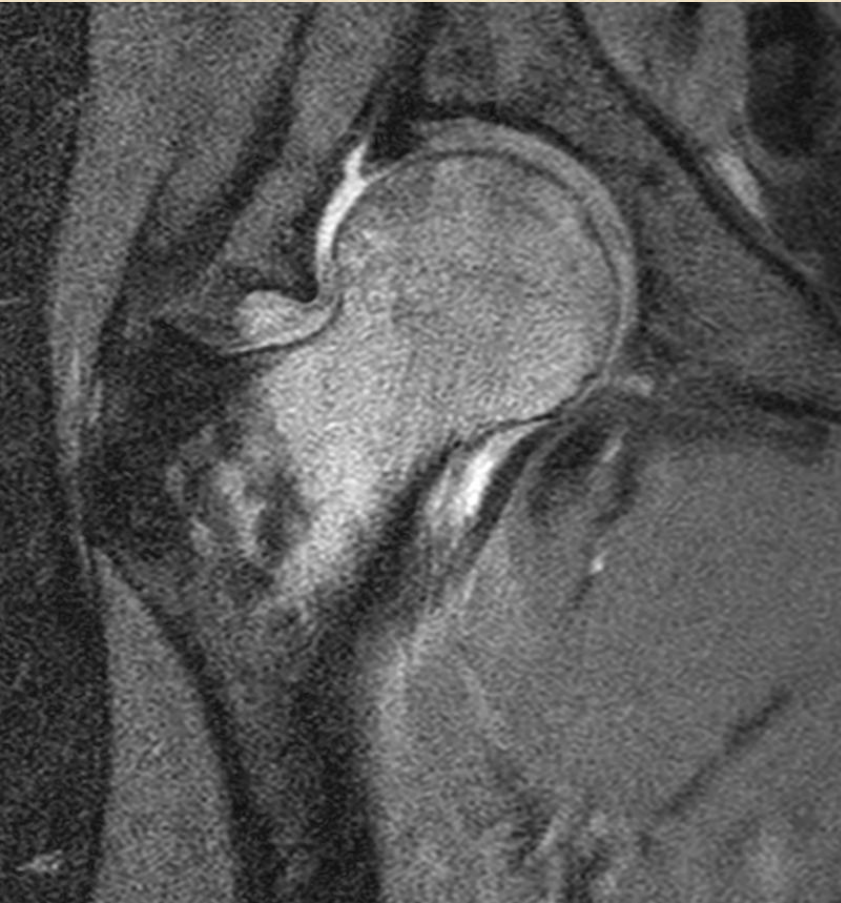
Large AVN mimic femoral neck fracture



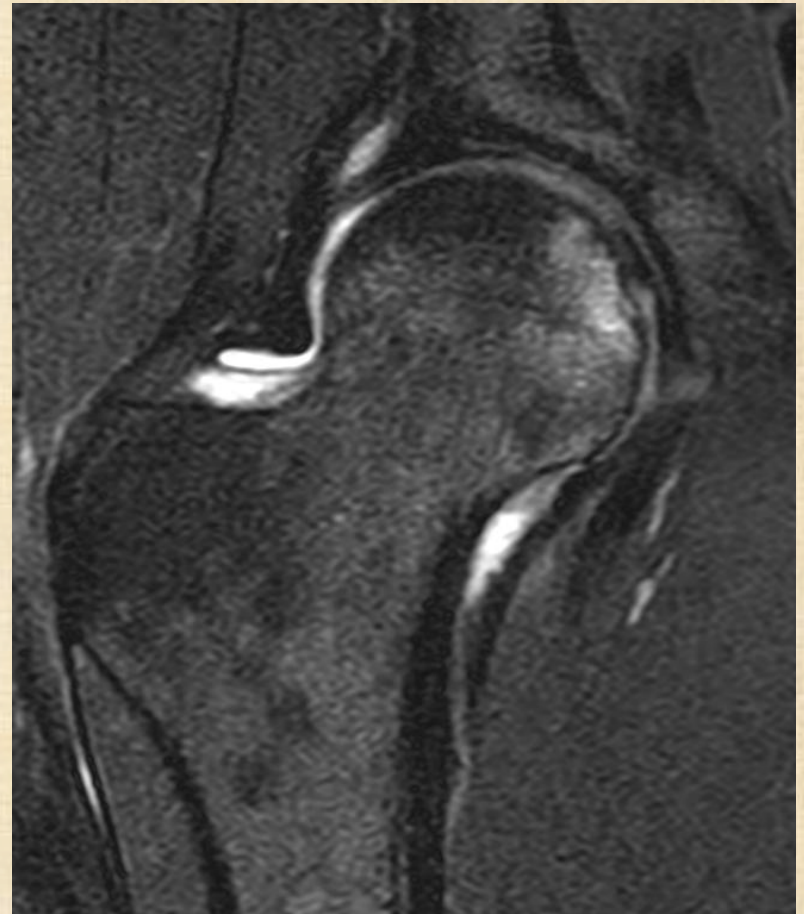OA with
secondary AVN ?



Transient osteoporosis of hip

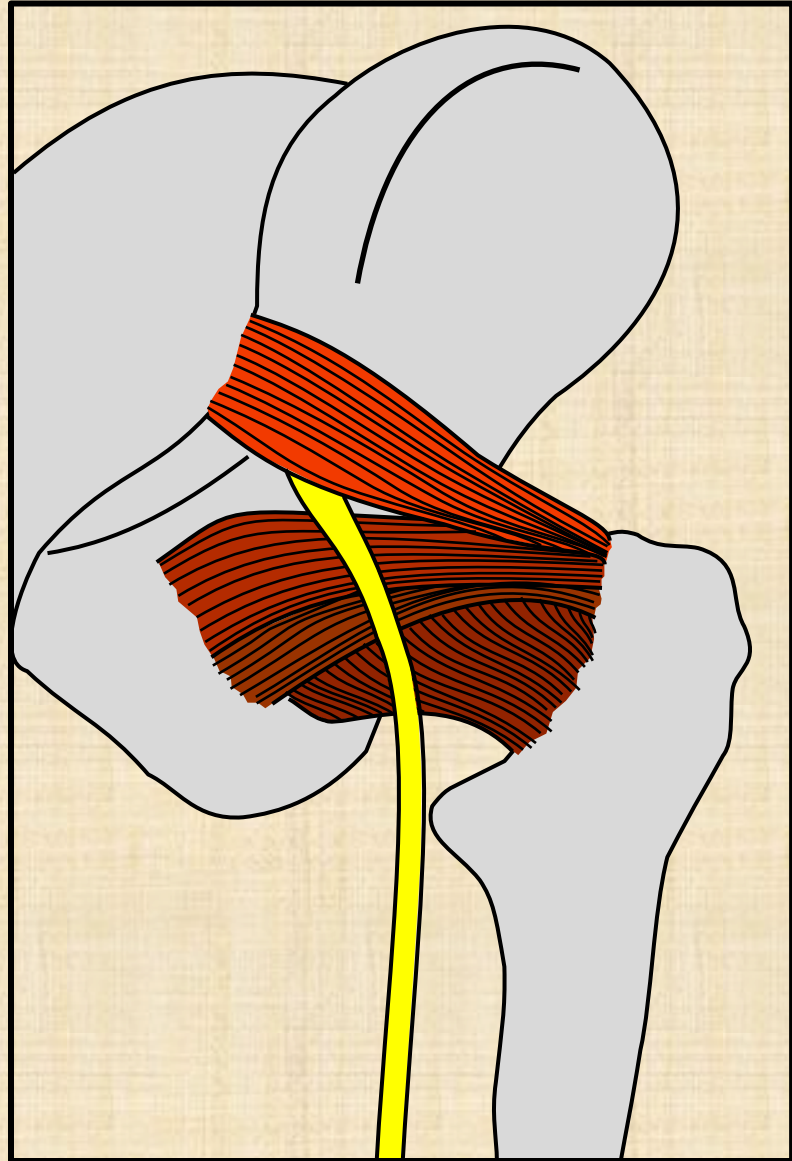


4 months
later

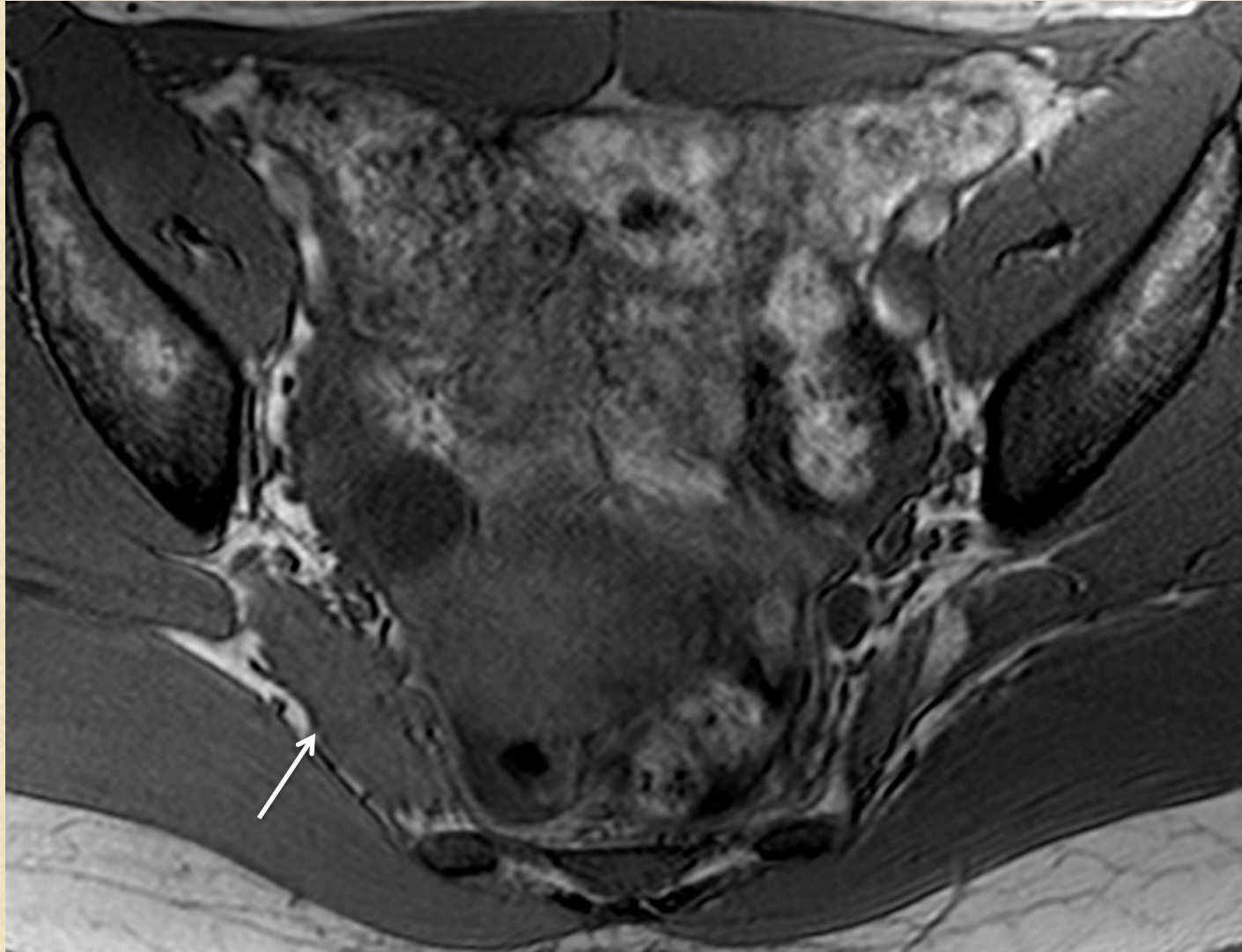


Piriformis syndrome

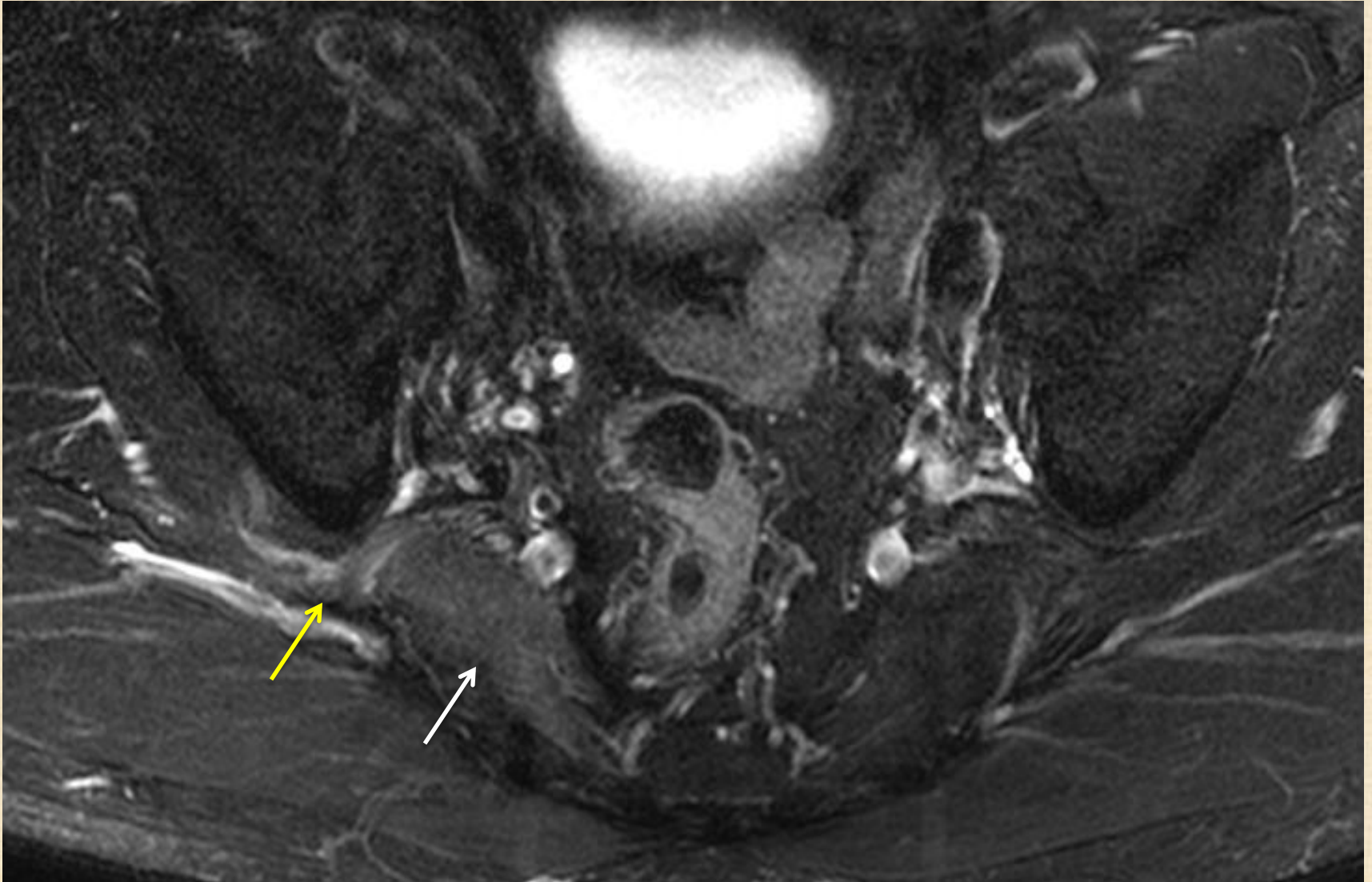
Deep gluteal syndrome



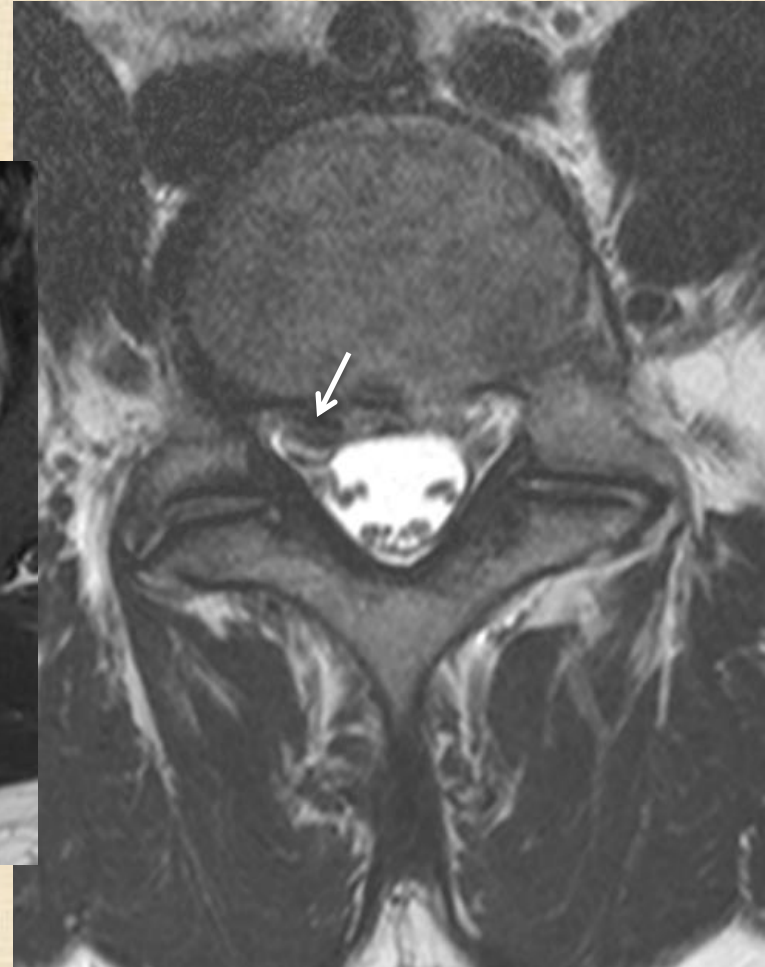
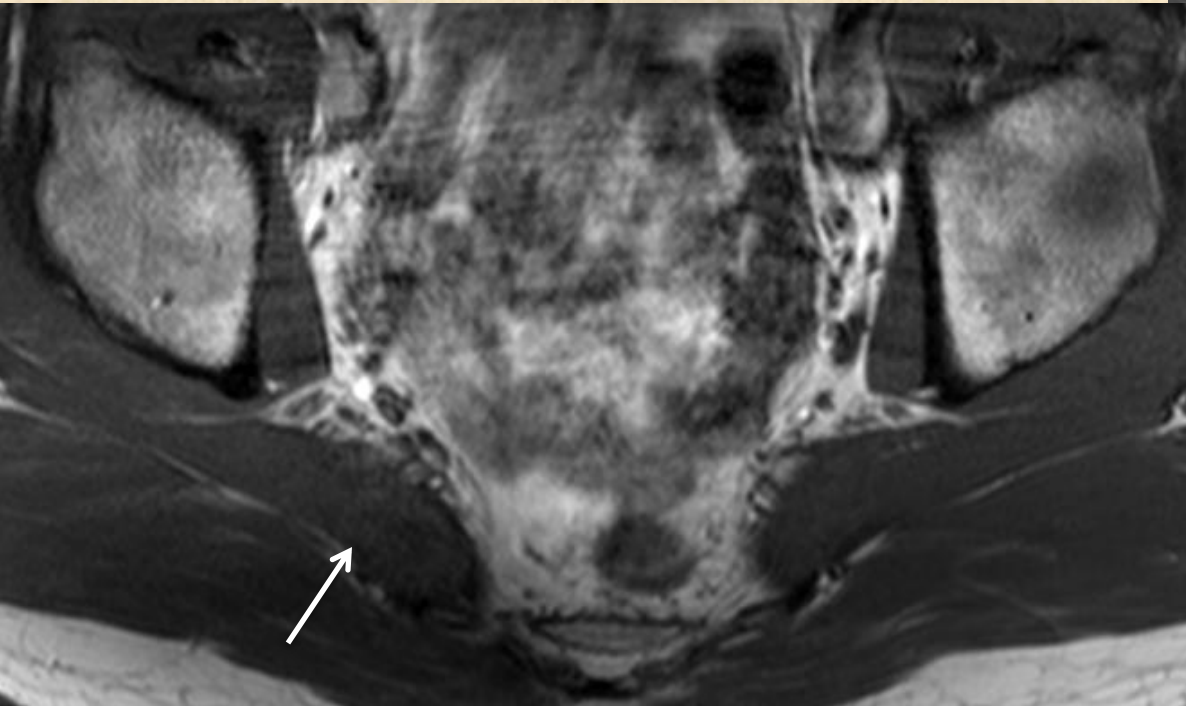
Piriformis syndrome



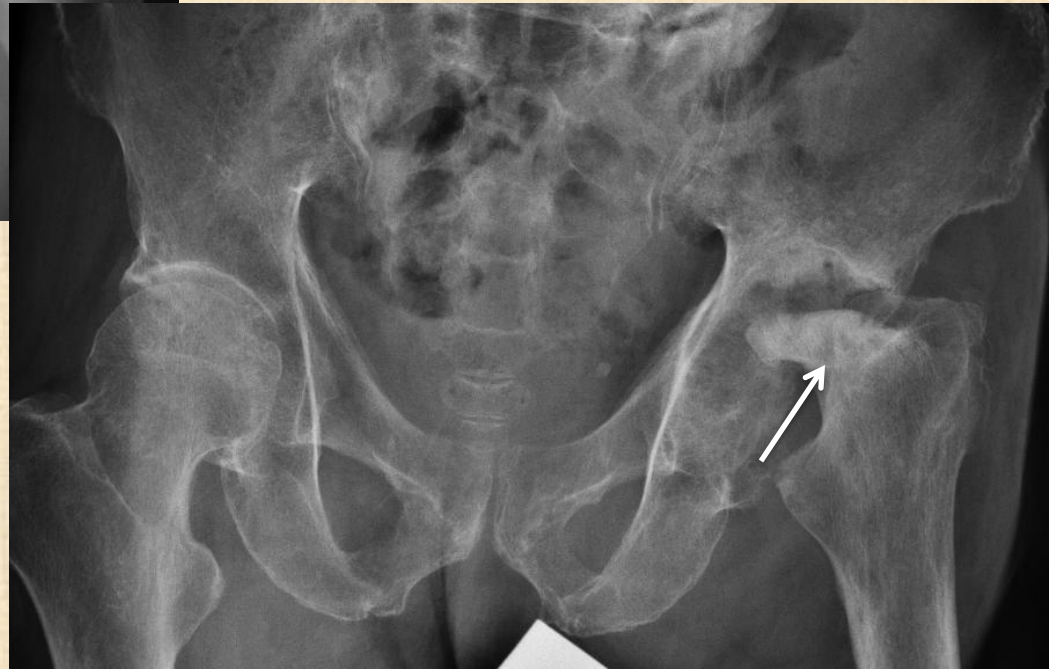
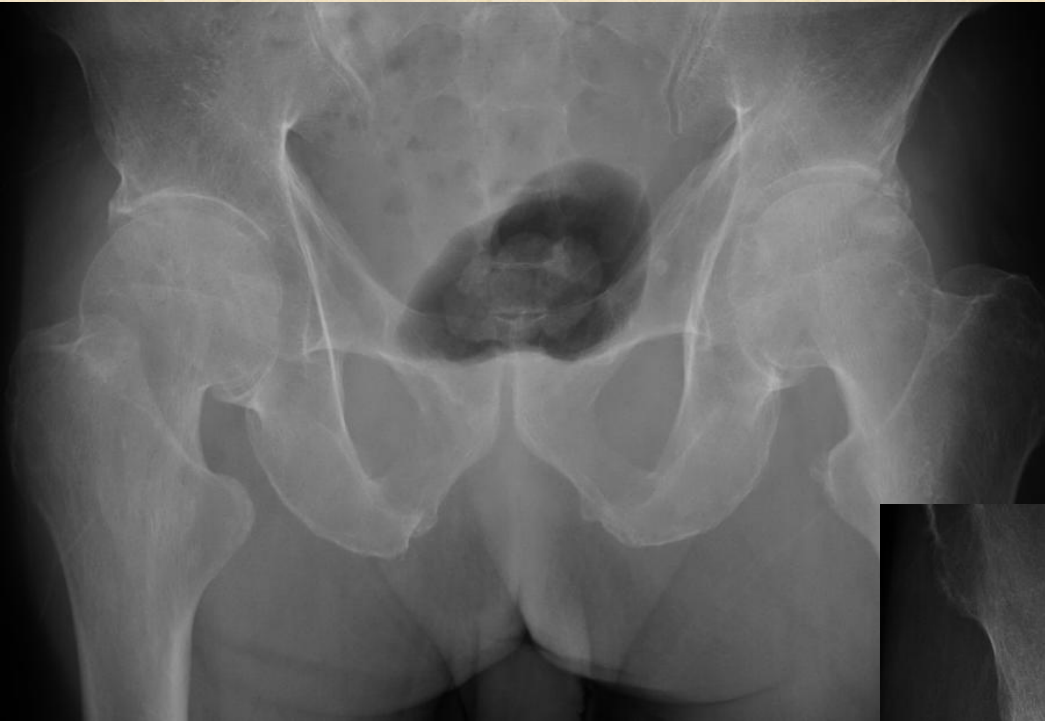Piriformis syndrome



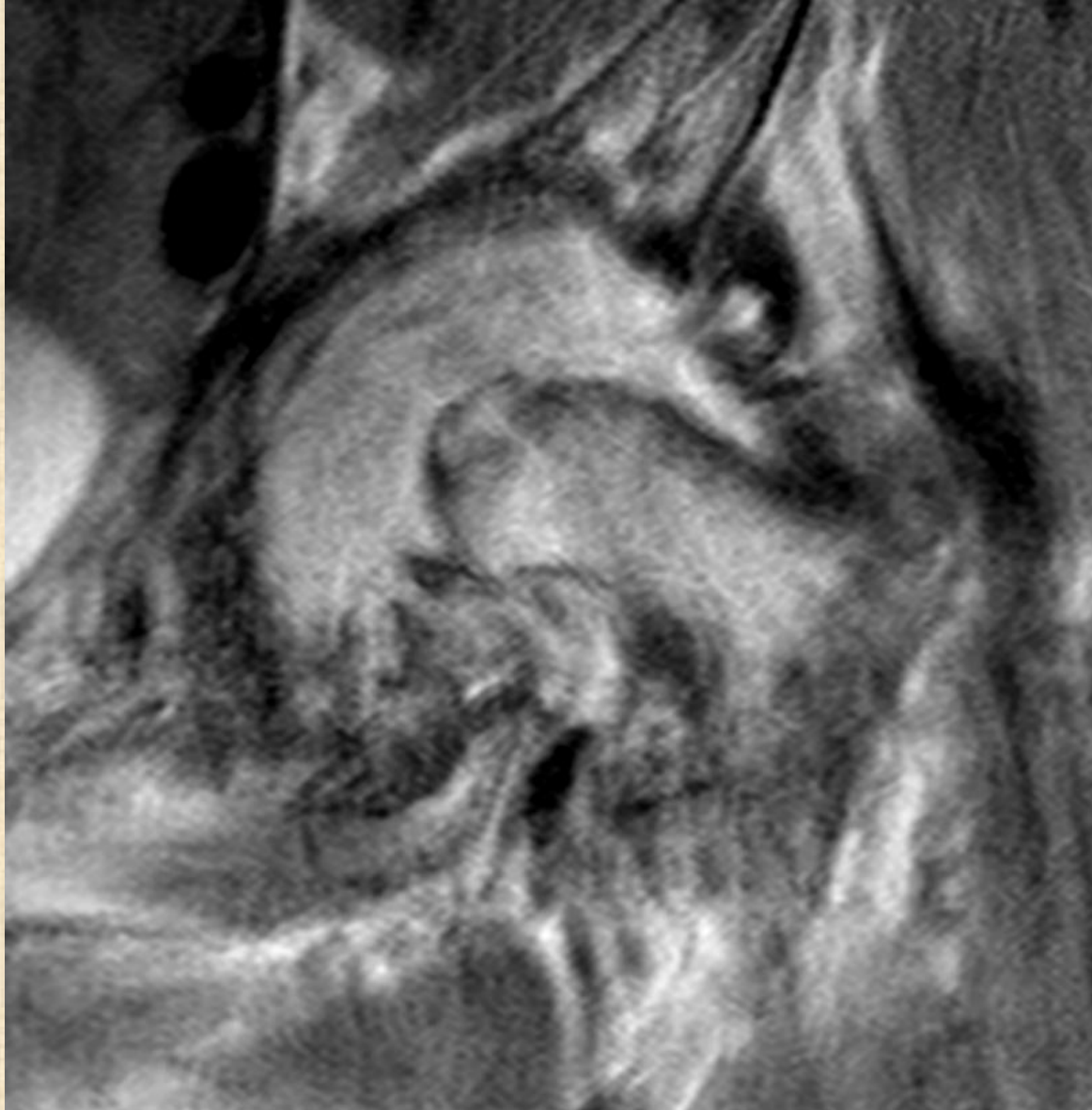
Piriformis syndrome ?

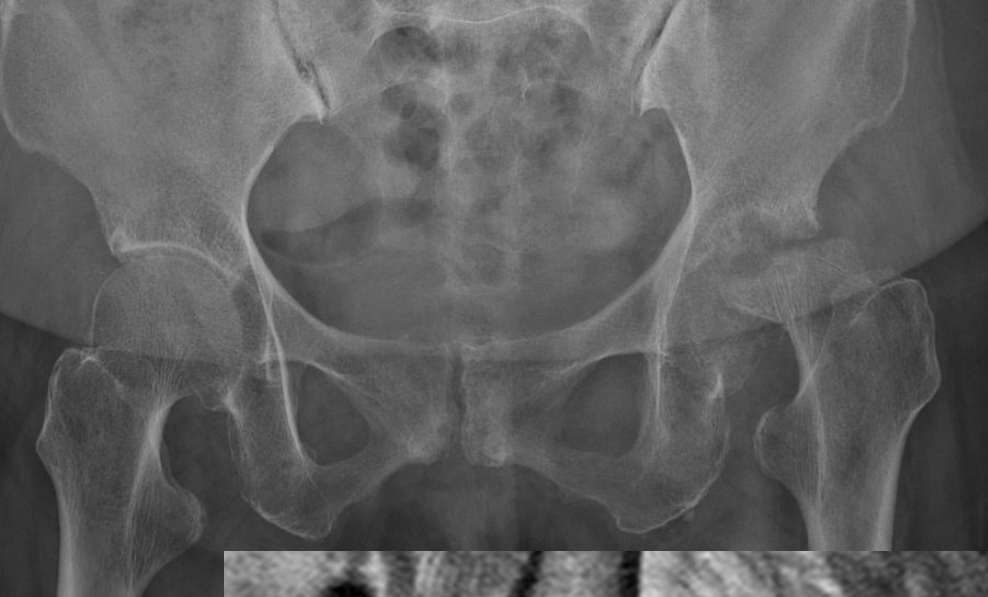

Joint pathology

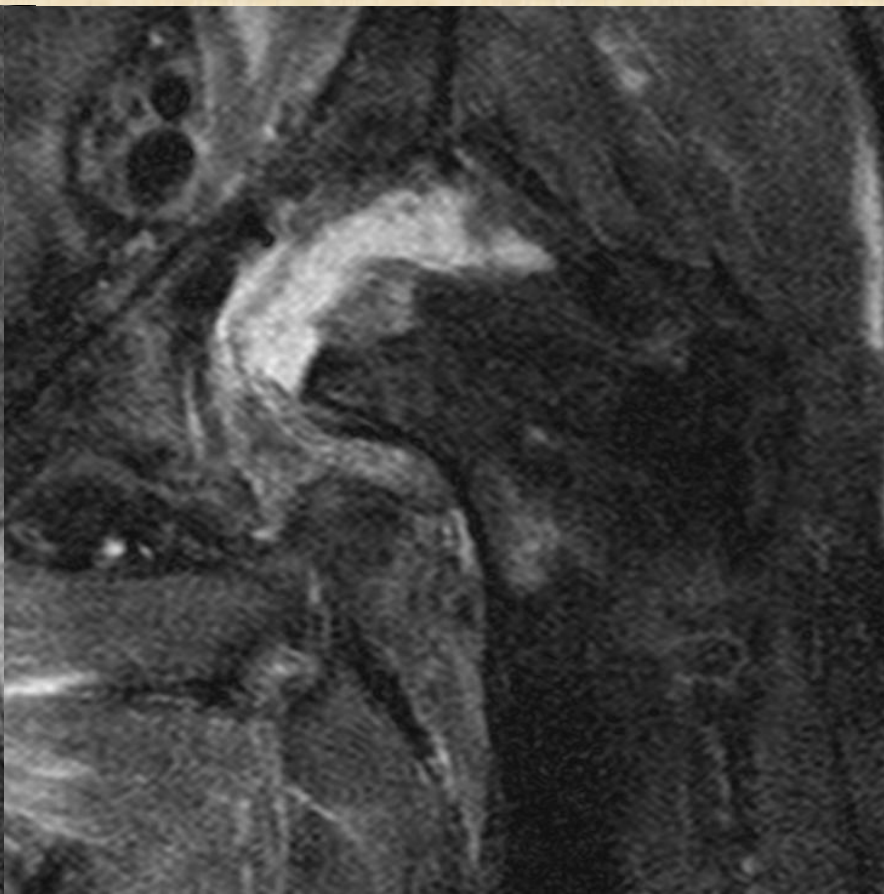
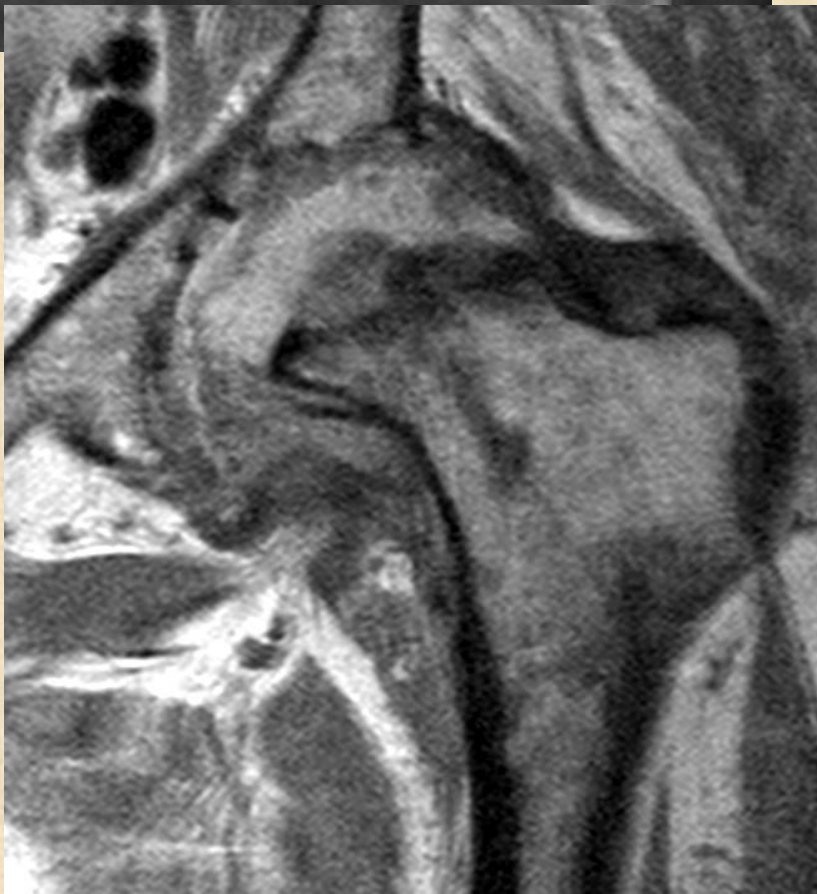
Rapidly destructive arthropathy of hip

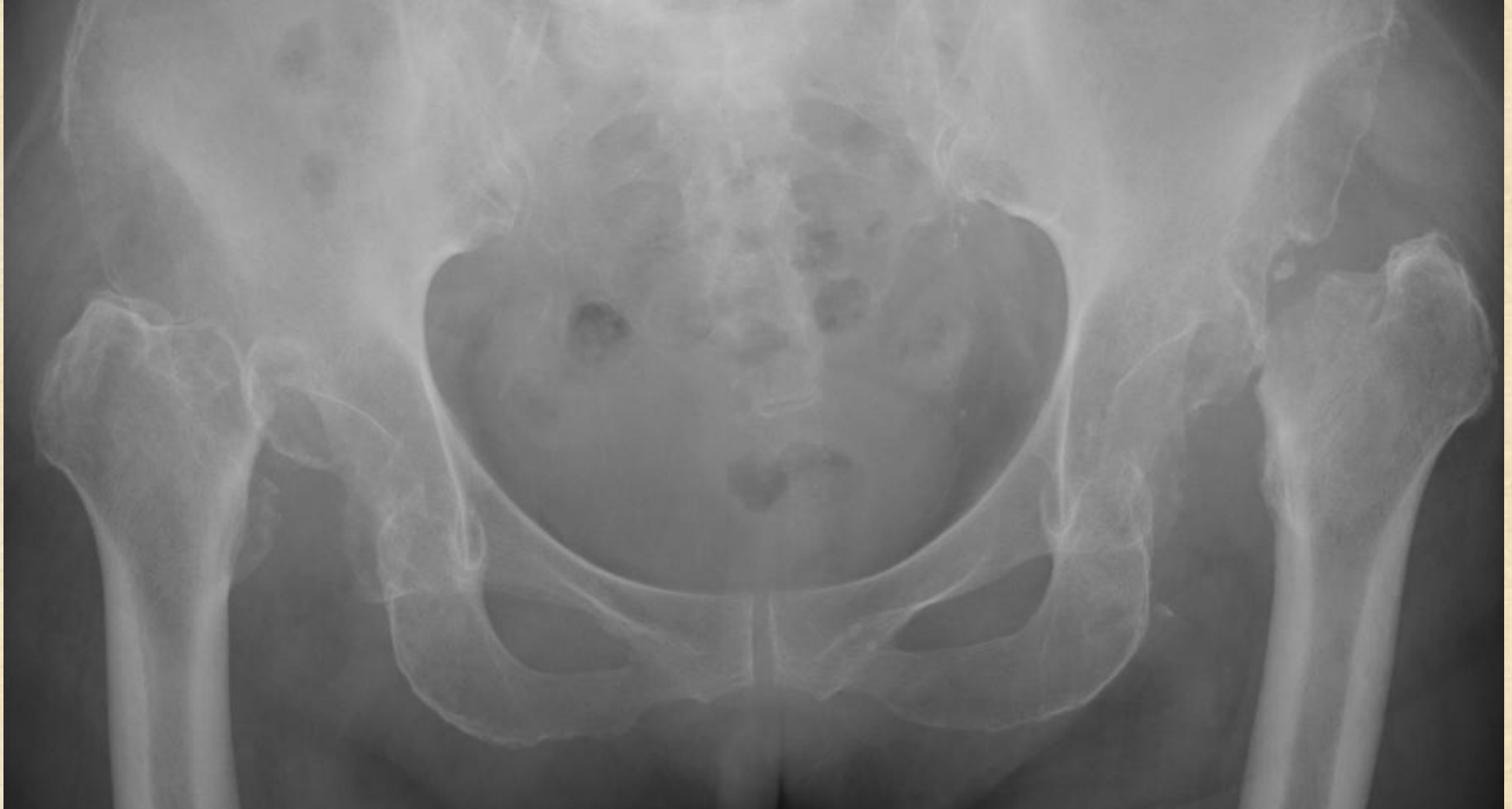

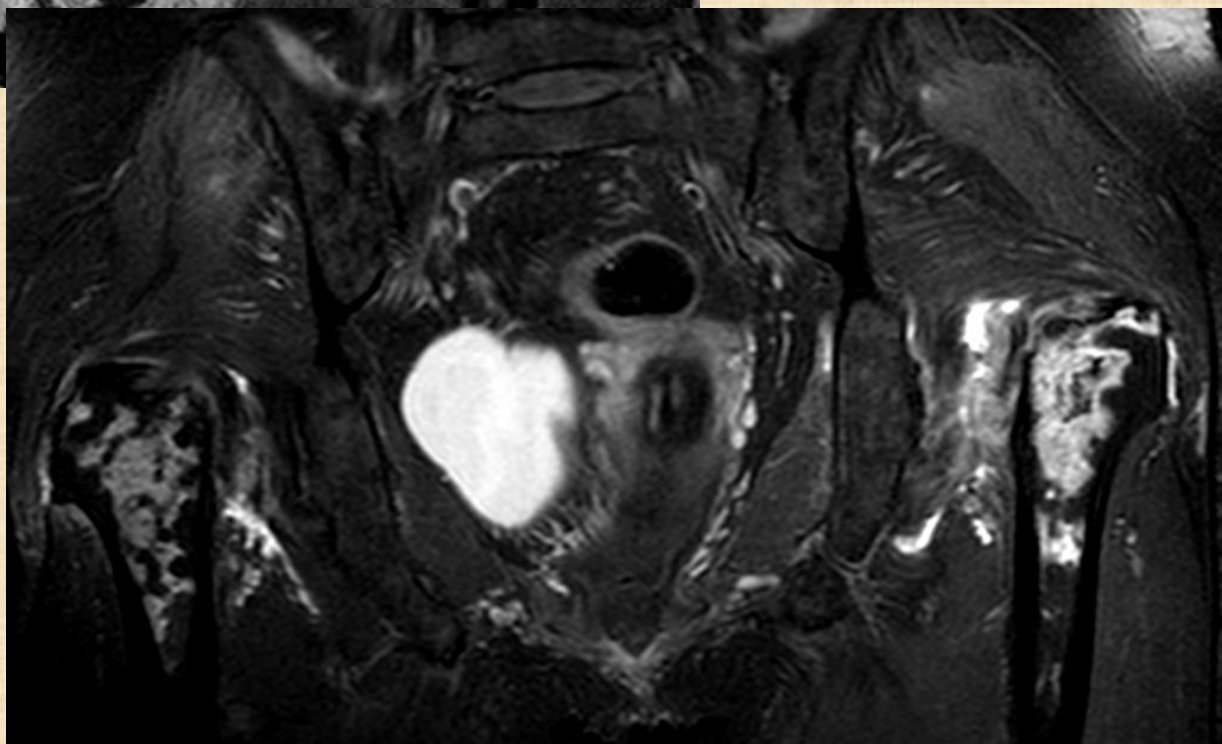
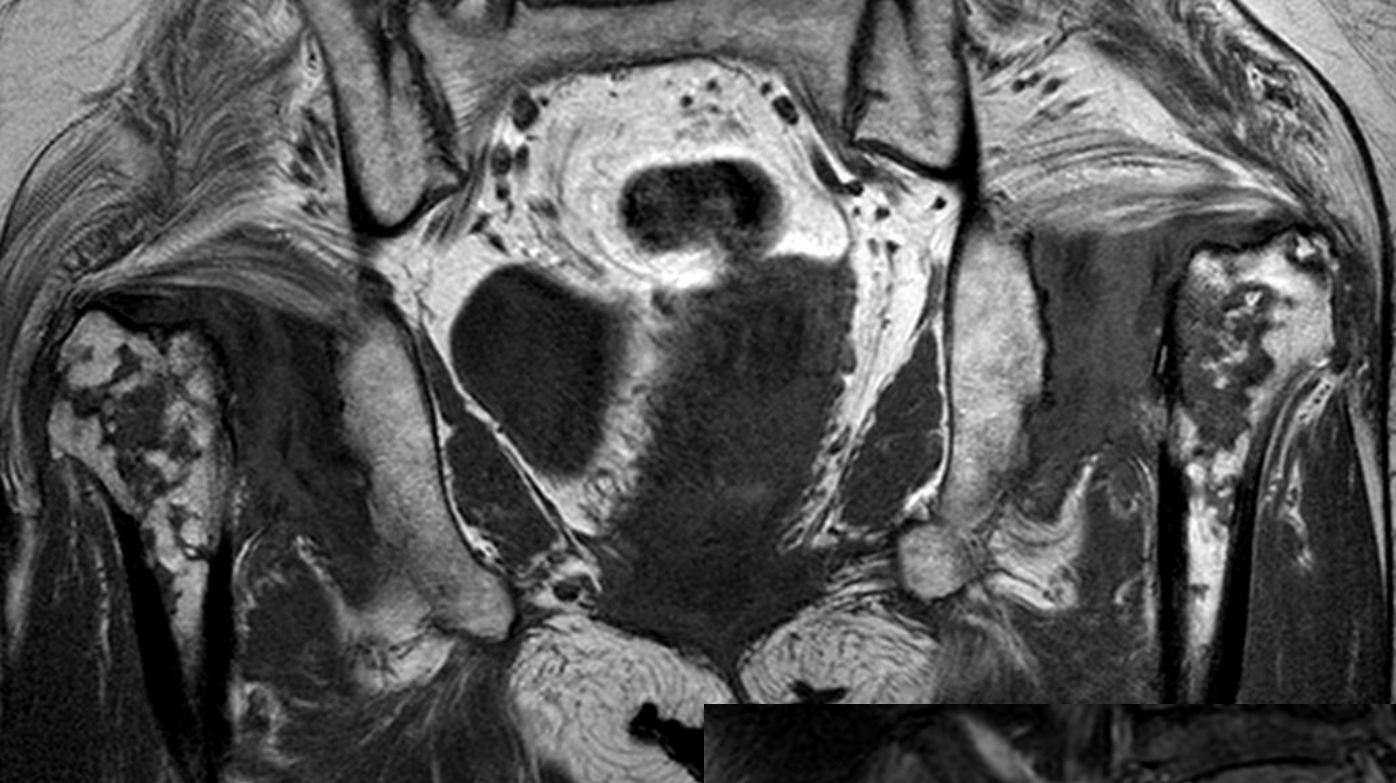


case 2



Case 3





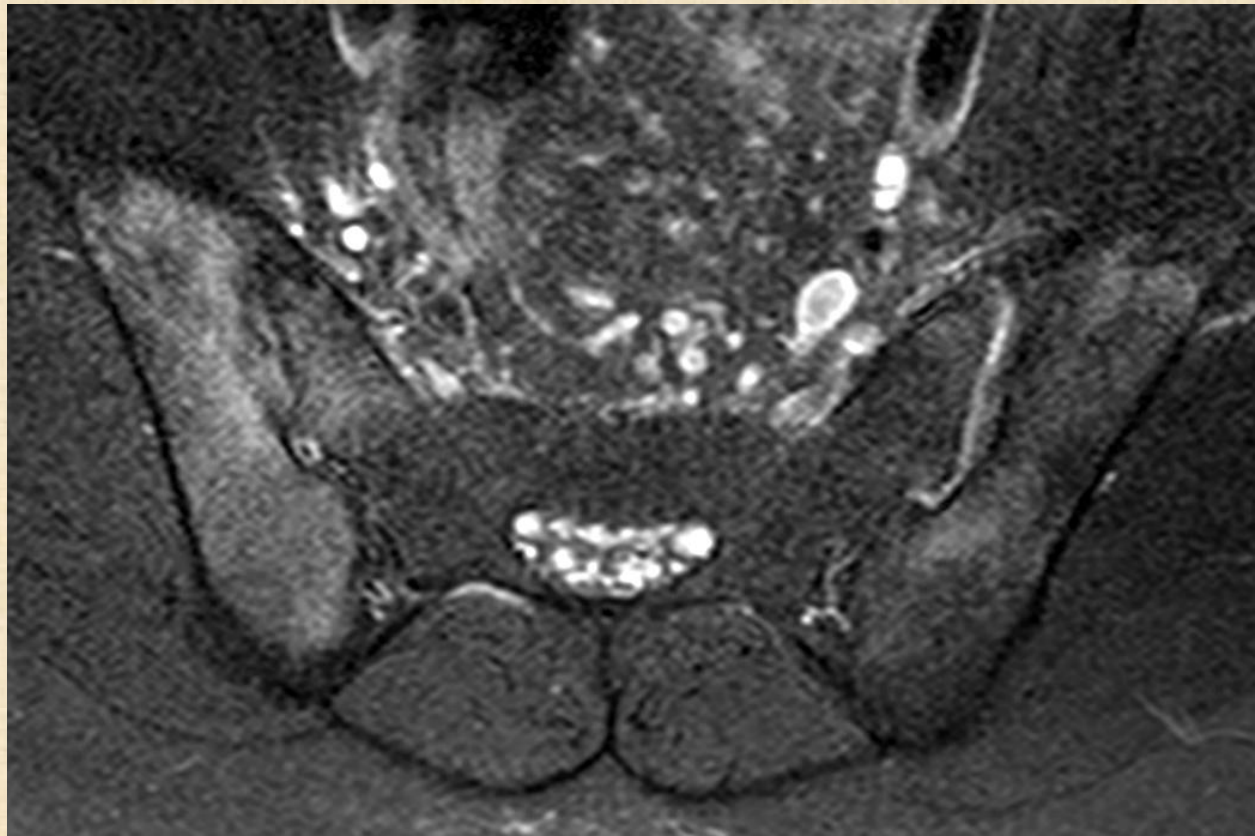
Rapid destructive arthropathy of hip

- OA (most commonly)
- CPPD

- RA
- Septic arthritis
- Neuropathic
- Avascular necrosis

Hip pain : need to rule out

- Sacroiliitis
- Back problem



End